

Caso Clínico / Radiological Case Report

ADULT EPIGLOTTITIS COMPLICATED WITH A PHARYNGEAL MUCOSAL SPACE COLLECTION

EPIGLOTITE NO ADULTO COMPLICADA POR COLEÇÃO NO ESPAÇO DA MUCOSA FARÍNGEA

Filipa Vilaverde¹, Romeu Mesquita¹, Marta Sousa¹, Alcinda Reis

¹Serviço de Imagiologia do Centro Hospitalar de Entre o Douro e Vouga, Feira
Diretora: Dra Rosa Cardoso

Correspondência

Filipa Vilaverde
Rua do Arinho, nº 6
4730-430 Vila Verde
e-mail: filipavilaverde@gmail.com

Recebido a 09/12/2014
Aceite a 28/02/2015

Abstract

The authors describe the case of a 30-year-old female patient who presented to the emergency department with a two days history of odynophagia and progressive severe dyspnea. Physical examination revealed an enlarged epiglottitis. A neck CT scan to assess complications was performed, confirming epiglottitis and showing a mucosal pharyngeal space collection. Sudden spontaneous elimination of purulent sputum a few hours later confirmed the collection to be an abscess.

Key-words

Epiglottitis; Abscess; Mucosal pharyngeal space; CT.

Resumo

Os autores descrevem um caso de uma mulher de 30 anos que recorreu ao serviço de urgência com uma história de odinofagia há 2 dias e dispneia severa progressiva. O exame físico revelou uma epiglote tumefacta. Foi realizada TC cervical para avaliar complicações, confirmando a epiglote e mostrando uma coleção do espaço mucoso faríngeo. A eliminação espontânea de secreções purulentas algumas horas depois confirmou que a coleção se tratava de um abscesso.

Palavras-chave

Epiglote; Abscesso; Espaço mucoso faríngeo; TC.

Case report

A previously healthy woman presented with a two days history of odynophagia unresponsive to nonsteroidal anti-inflammatory drugs, and progressive onset of severe dysphagia, dyspnea and fever. Physical examination revealed neck swelling and oropharyngeal erythema but no signs of respiratory distress. Laboratory data showed leukocytosis and raised *C-reactive protein*. The patient performed a chest X-Ray (not shown), which was unremarkable. A neck CT before and after intravenous contrast ruled out foreign bodies, and showed an enlarged edematous epiglottitis and enlargement of the aryepiglottic folds in the supraglottic larynx, associated with thickening and hypodensity of pharyngeal mucosal space (PMS) of the oropharynx and hypopharynx (Figs. 1, 2, 3). The PMS involvement also showed

a central fluid collection with mild peripheral rim-like enhancement suggesting the presence of a collection (Fig. 4). There was no marked narrowing of the airway, extension to parapharyngeal space, vascular complications or involvement of the mediastinum. Mild reactive bilateral internal jugular chain lymphadenopathies were found, namely in the level II.

The patient started intravenous antibiotics (clindamycin plus ceftriaxone) and corticotherapy (dexamethasone), and wasn't immediately intubated but stayed at the hospital in closed observation. A few hours later had a sudden onset of cough with spontaneous elimination of purulent sputum. She had completely clinical recovery and repeated CT three days later, which showed resolution of the previous findings. Blood cultures were negative.

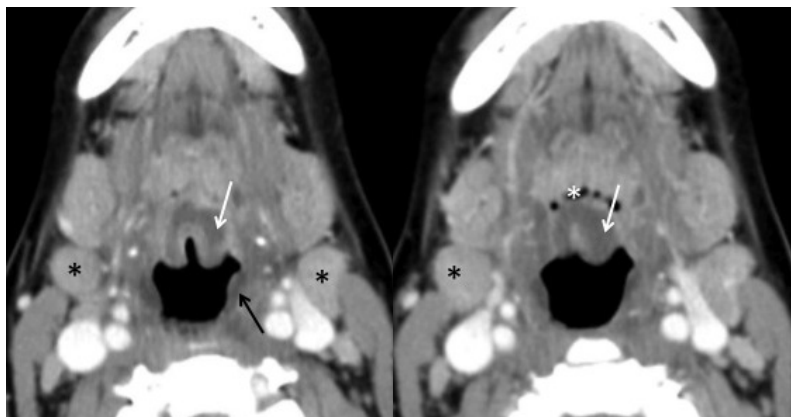


Fig. 1 - Epiglottitis. Axial contrast enhanced CT above the hyoid bone level, shows an enlarged and edematous epiglottitis (white arrow), with mild thickening of the pharyngeal mucosa (black arrow) without extension to vallecula (*). Mild reactive bilateral upper internal jugular chain lymphadenopathies (level II) were also found (black *).

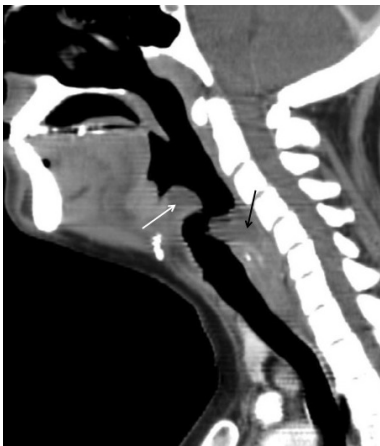

Fig. 2 - Epiglottitis. Sagittal reformatted contrast enhanced CT demonstrates the edematous epiglottis (white arrow) and prevertebral (apagar) soft tissue swelling between cervical spine and upper airway due to pharyngeal mucosal space collection (black arrow). Note that a retropharyngeal space collection should extend inferiorly to the mediastinum.

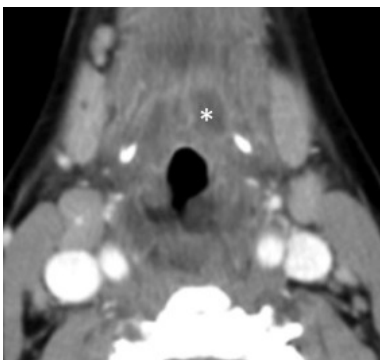


Fig. 3 - Supraglottic extension. Axial contrast enhanced CT at the level of the supraglottis shows the extension of the inflammation to the floor of the mouth (*) and to the aryepiglottic folds, occluding the pyriform sinus.

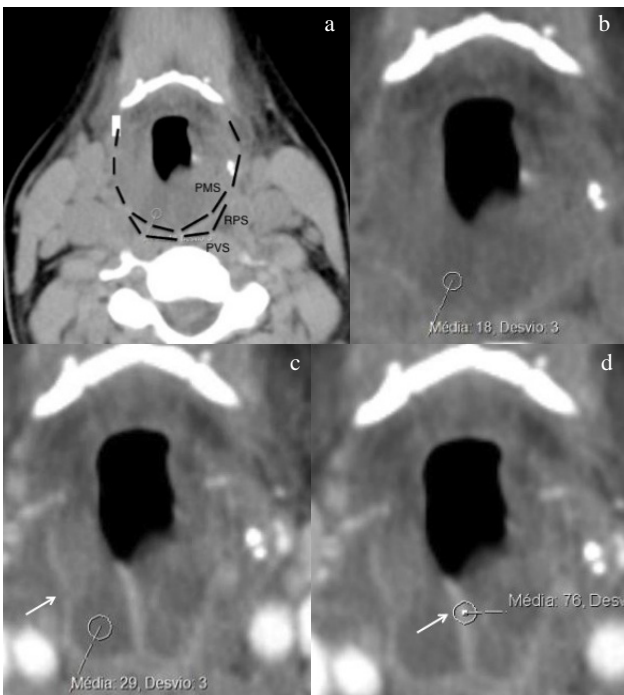


Fig. 4 - Pharyngeal mucosal space phlegmon/abscess. Axial pre (a, b) and post contrast (c, d) enhanced CT at the level of the hyoid bone, depicts marked thickening and hypodensity of the pharyngeal mucosal space, extending laterally, beyond the retropharyngeal limits. There is peripheral rim-like enhancement (arrow) although without a clearly fluid collection (clinic evolution confirmed this was an abscess (apagar)). PMS – parapharyngeal space; RPS – retropharyngeal space; PVS – prevertebral space.

Discussion

The differential diagnosis of an enlarged epiglottis and mucosal pharyngeal edema should include infection, angioedema, ingestion of a caustic substances or foreign body, trauma and thermal injury, and post-irradiation edema, the last five hypotheses excluded by an adequate clinical history. Also, angioedema usually occurs more suddenly with a history of exposition to a potential offending antigen. In this particular case, the clinical and laboratory findings support the infectious etiology as the most likely.

Epiglottitis is an acute life-threatening disease often associated with airway compromise mainly in children. The introduction of *Haemophilus influenzae* type b vaccinations programs led to a drastic decrease in its incidence among children [1] and to a demographic and etiologic shift, with more prevalence in adulthood, and *non-Haemophilus influenzae* becoming the dominant agent [2]. *Non-Haemophilus influenzae* epiglottitis tends to involve the supraglottic structures to a much greater extent [2], and 4%–25% of patients develop complications such as necrotizing epiglottitis and epiglottic or deep neck abscess [3]. The PMS abscess is one of these collections and is very unusual, having the same serious complications as other deep neck abscesses, such as spontaneous rupture into the pharynx (risk of aspiration pneumonia and empyema).

The symptoms of epiglottitis and its complications overlap, and patients typically present with fever, abrupt onset of stridor (more often in children) and dysphagia, shortness of breath, sore throat and posturing with neck extension [5,6].

Epiglottitis is usually a clinical diagnosis. Imaging studies are reserved for doubtful cases and to assess the extent and possible complications. Lateral neck radiography is usually the first exam, mostly in children, which reveals the typical “thumb sign” of thickened epiglottis [5]. In adults the contrast-enhanced CT is more useful, and shows a thickened, edematous epiglottis and mucosal enhancement. The supraglottic larynx, tongue base, and tonsils are often involved, and a phlegmonous collection or even an abscess may be seen within the adjacent soft tissues [5, 7]. In the presented case, there was also implication of the PMS, an extremely rare finding, especially secondarily to epiglottitis. The PMS includes the mucosal surface structures of the nasopharynx, oropharynx, and hypopharynx, and extends from the skull base to the cricoid cartilage [8-11].

One of the greatest author’s struggles when faced with this case was the assessment of the lesion to a specific space. As we faced with a lesion predominantly involving the more posterior compartments of the neck, the main spaces considered were the PMS, the retropharyngeal and the prevertebral spaces. The prevertebral muscles were normal, the collection involves almost circumferentially the hypopharynx (Fig. 4) and the caudal extension of the collection is in the neck, don’t extending further to the mediastinum (Fig. 2). These findings make a PMS collection most likely.

Conclusion

CT scan has an important role in evaluation of epiglottitis’s possible complications, particularly in adults.

References

1. Shah, R. K.; Roberson, D. W.; Jones, D. T. - *Epiglottitis in the Hemophilus influenzae type B vaccine era: changing trends*. Laryngoscope, 2004, 114(3):557-560.
2. Capps, E. F.; Kinsella, J. J.; Gupta, M.; Bhatki, A. M.; Opatowsky, M. J. - *Emergency Imaging Assessment of Acute, Non-traumatic Conditions of the Head and Neck*. RadioGraphics, 2010, 30:1335-1352.
3. Berger, G.; Landau, T.; Berger, S.; Finkelstein, Y.; Bernheim, J.; Ophir, D. - *The rising incidence of adult acute epiglottitis and epiglottic abscess*. Am J Otolaryngology, 2003, 24(6):374-83.
4. Warshafsky, D.; Goldenberg, D.; Kanekar, S. G. - *Imaging anatomy of deep neck spaces*. Otolaryngol Clin North Am, 2012, 45(6):1203-21.
5. Harnsberger, H. R.; Osborn, A. G. - *Differential diagnosis of head and neck lesions based on their space of origin. The suprahyoid part of the neck*. AJR, 1991, 157(1):147-54.
6. Sobol, S. E.; Zapata, S. - *Epiglottitis and croup*. Otolaryngol Clin North Am, 2008, 41(3):551-566.
7. Skoulakis, C. E.; Papadakis, C. E.; Bizakis, J. G.; Nikolidakis, A. A.; Manios, A. G.; Helidonis, E. S. - *Abscess of the pharyngeal mucosal space - an unusual location*. J Otolaryngol, 2003, 32(2):121-124.
8. Vieira, F.; Allen, S. M.; Stocks, R. M.; Thompson, J. W. - *Deep neck infection*. Otolaryngol Clin North Am, 2008, 41(3):459-483.
9. Ludwig, B. J.; Foster, B. R.; Saito, N.; Nadgir, R. N.; Castro-Aragon, I.; Sakai, O. - *Diagnostic imaging in nontraumatic pediatric head and neck emergencies*. RadioGraphics, 2010, 30:781-799.
10. Warshafsky, D.; Goldenberg, D.; Kanekar, S. G. - *Imaging anatomy of deep neck spaces*. Otolaryngol Clin N Am, 2012, 45:1203-1221.
11. Rubin, J. A.; Wesolowski, J. R. - *Neck MR imaging anatomy*. Magn Reson Imaging Clin N Am, 2011, 19:457-473.
12. Harnsberger, H. R.; Osborn, A. G. - *Differential diagnosis of head and neck lesions based on their space of origin. 1. The Suprahyoid part of the neck*. AJR, 1991, 157:147-154.
13. Hoang, J. K.; Branstetter, B. F.; Eastwood, J. D.; Glastonbury, M. C. - *Multiplanar CT and MRI of collections in the retropharyngeal space: Is it an abscess?* AJR, 2011, 196:W426-W432.