

## Caso Clínico / Radiological Case Report

**An Atypical Presentation of Invasive Breast Carcinoma***Uma Apresentação Atípica de Carcinoma Invasivo da Mama*Ana Loureiro<sup>1</sup>, Duarte Rosa<sup>1</sup>, Marta Palmeiro<sup>2</sup>, João Niza<sup>1</sup>, Bárbara Macedo Pena<sup>3</sup>, José Carlos Marques<sup>1</sup>

<sup>1</sup> Serviço de Radiologia, Instituto Português de Oncologia de Lisboa, Francisco Gentil, EPE – Lisboa, Portugal

Director: Dr. José Venâncio

<sup>2</sup> Serviço de Radiologia, Hospital Beatriz Ângelo, Loures, Portugal

Director: Dr. Luís Gargaté

<sup>3</sup> Serviço de Anatomia Patológica, Instituto Português de Oncologia de Lisboa, Francisco Gentil, EPE – Lisboa

Director: Dr. José Cabeçadas

**Correspondência**

Ana Loureiro

Serviço de Radiologia

Instituto Português de Oncologia de Lisboa,

Francisco Gentil, EPE

R. Prof. Lima Basto

1099-023 Lisboa, Portugal

email: analoureiro@claperm.com

**Abstract**

Ectopic breast tissue (EBT) is found in no more than 6% of the population. The axilla is the most common location.

We report a case of a 43-year-old woman that showed a painless small lump on her right anterior axillary line adjacent to the axilla, for three years. On ultrasound it corresponded to a growing unspecific hypochogenic subcutaneous nodule. A core biopsy was performed and the histologic diagnosis was that of an invasive lobular breast carcinoma in an aberrant EBT. A locoregional staging by magnetic resonance (MR) was performed showing no other lesions. Patient underwent wide local excision of the lesion followed by radiotherapy and hormone therapy. This article underlines the possibility of presentation of EBT as an invasive breast carcinoma, emphasizing its clinical and imaging features and the importance of its prompt recognition for a timely treatment.

**Keywords**

Breast cancer; Ectopic breast; Accessory breast tissue.

**Resumo**

A presença de tecido mamário ectópico é encontrada em menos de 6% da população e é sede de patologia benigna e maligna tal como o tecido mamário normal. A axila é a topografia mais frequente. Os autores descrevem um caso de uma paciente de 43 anos que se apresentou com uma massa palpável na linha axilar anterior, indolor e presente há 3 anos. Nos estudos de imagem correspondia a uma lesão nodular subcutânea hipocogénica, que mostrou crescimento ao longo do tempo. Foi efectuada biópsia que confirmou carcinoma lobular invasivo da mama em tecido mamário ectópico. O estadiamento locoregional com ressonância magnética (RM) não mostrou outras alterações. A paciente foi submetida a excisão local alargada seguida de radioterapia. Este artigo mostra uma apresentação rara de tecido ectópico mamário como carcinoma da mama, com ênfase nas características clínicas e imagiológicas e a importância de um diagnóstico atempado para implementação de terapêutica apropriada.

**Palavras-chave**

Cancro de mama; Tecido mamário ectópico; tecido mamário acessório.

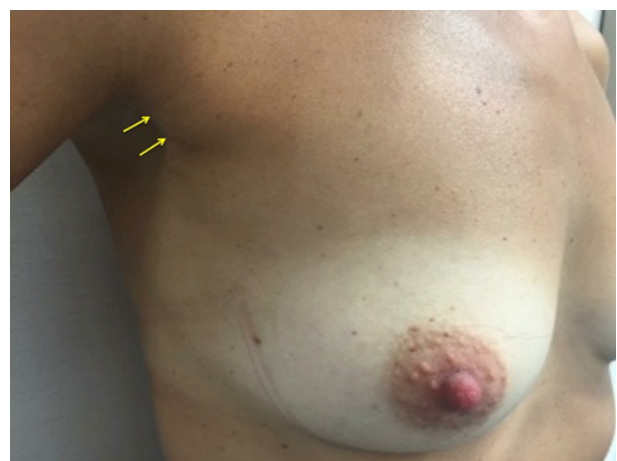**Case Presentation**

A 43-year-old white female with no relevant family history of breast cancer, presented to us with a 3-year history of a small lump on the superior aspect of the right anterior axillary line. The previous medical history was unremarkable.

In the previous years, there were no significant findings on the mammograms and on the breast ultrasound, the palpable lump corresponded to a 13 mm subcutaneous nodule, with features of benignity: oval shape and smooth contour, hypoechoic, with no acoustic shadow, nor involvement of the adjacent skin, with major axis parallel to the skin surface. The lesion had no internal signal on color Doppler ultrasound. This finding was already described on previous breast exams for the past three years and showed minimal growth.

**Investigations**

On physical examination, a small fixed and painless palpable lump was detected on her right anterior axillary line near the axilla (Fig. 1). There were no changes in the adjacent skin surface and absence of nipple or areolar complex. No palpable



**Figure 1** – On examination a small fixed palpable lump was detected on the right anterior axillary line near the axilla (arrows). The adjacent skin surface had no change.

bilateral breast or contralateral axillary lesions where found. In our breast evaluation, mediolateral oblique mammograms showed on the right axilla a discreet focal asymmetric density of isolated fibroglandular tissue containing small amounts of scattered fat tissue, with no connection with the remaining anatomic breast, suggestive of EBT in the right axilla (Fig. 2A). There were no other relevant mammographic findings.

On breast ultrasound, a lesion was identified showing irregular margins, increased size comparing with the previous ultrasounds, measuring 15.7 mm of major axis and no cleavage plane with adjacent skin surface. There was no posterior acoustic shadowing (Fig. 2B) or internal signal on color Doppler ultrasound (Fig. 2C).

Because of these suspicious findings, an uneventful ultrasound guided core biopsy was performed. The histologic diagnosis was that of an invasive lobular breast carcinoma in an aberrant EBT.

A magnetic resonance (MR) study was performed as locoregional staging, revealing on axial and sagittal T2-weighted MR images axillary ectopic breast tissue bilaterally, and a subcutaneous nodular lesion, with irregular borders and intermediate signal intensity, in the right anterior axillary line near the axilla, measuring 16.4 mm of longest axis (circle) (Fig. 3A). In the dynamic contrast-enhanced MR imaging the lesion demonstrated an early and progressive enhancement with an intensity peak after two minutes and a time-signal intensity curve not suggestive of malignancy (Fig. 3B, C e D). The lesion didn't show restricted diffusion. No other lesions were detected in both breast and axillary lymph nodes had normal size.

## Differential Diagnosis

The differential diagnosis of EBT carcinoma should include lipoma, excess axillary fat, fibroadenoma, sebaceous cyst, epidermoid cyst, benign lymphadenopathy, lymphadenitis, metastatic carcinoma, lymphoma, and hidradenitis suppurativa. In the presence of a pigmented axillary lesion, the differential diagnosis includes seborrhic keratosis, fibromas, and intradermal nevis.

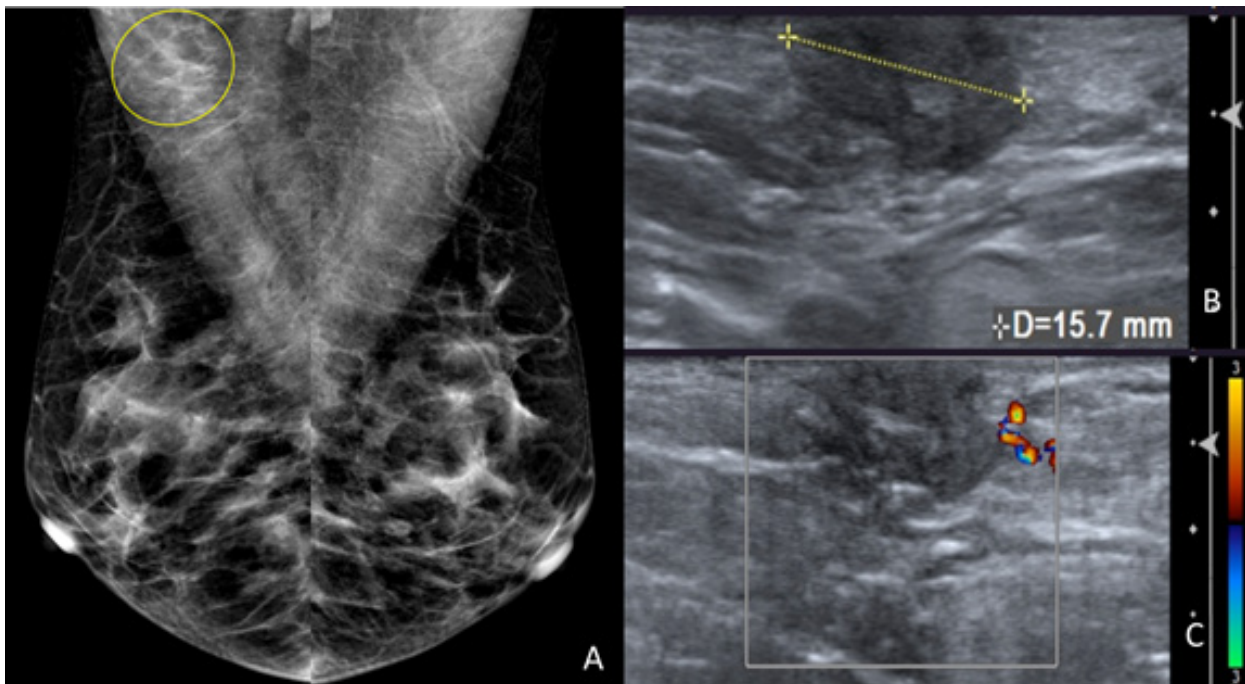
## Treatment

The patient underwent wide local excision with ipsilateral sentinel lymph node biopsy that was negative. The surgical margins were free. The lesion was staged as a pT1cN0M0. The patient was submitted to adjuvant radiotherapy and hormone therapy.

## Outcome and follow-up

The histopathologic examination of the specimen revealed the diagnosis of an invasive lobular carcinoma in ectopic breast tissue. The immunohistochemical evaluation results were positive for estrogen receptor (100%) and for progesterone receptor (50%), ERBB2 was negative (2+) and Ki67 was <1% in the tumoral cells. The estrogens receptors expression in the ectopic breast lobule was weaker than in the cancer cells.

The final pathologic diagnosis was of an invasive lobular carcinoma in aberrant ectopic breast tissue in the right anterior axillary line adjacent to the axilla.



**Figure 2** – (A) Bilateral mediolateral oblique mammogram views showed on the right axilla a discreet focal asymmetric density of isolated fibroglandular tissue containing small amounts of scattered fat tissue (circle), with no connection with the remaining anatomic breast tissue, suggestive of ectopic breast tissue in the right axilla. (B) On breast ultrasound, an oval palpable hypoechoic subcutaneous nodule was identified in the right anterior axillary line, presenting in the present study an irregular contour, increased size (15.7 mm of major axis) and no cleavage plane with adjacent skin surface. It showed no posterior acoustic shadowing. (C) This lesion had no internal signal on colour Doppler ultrasound.

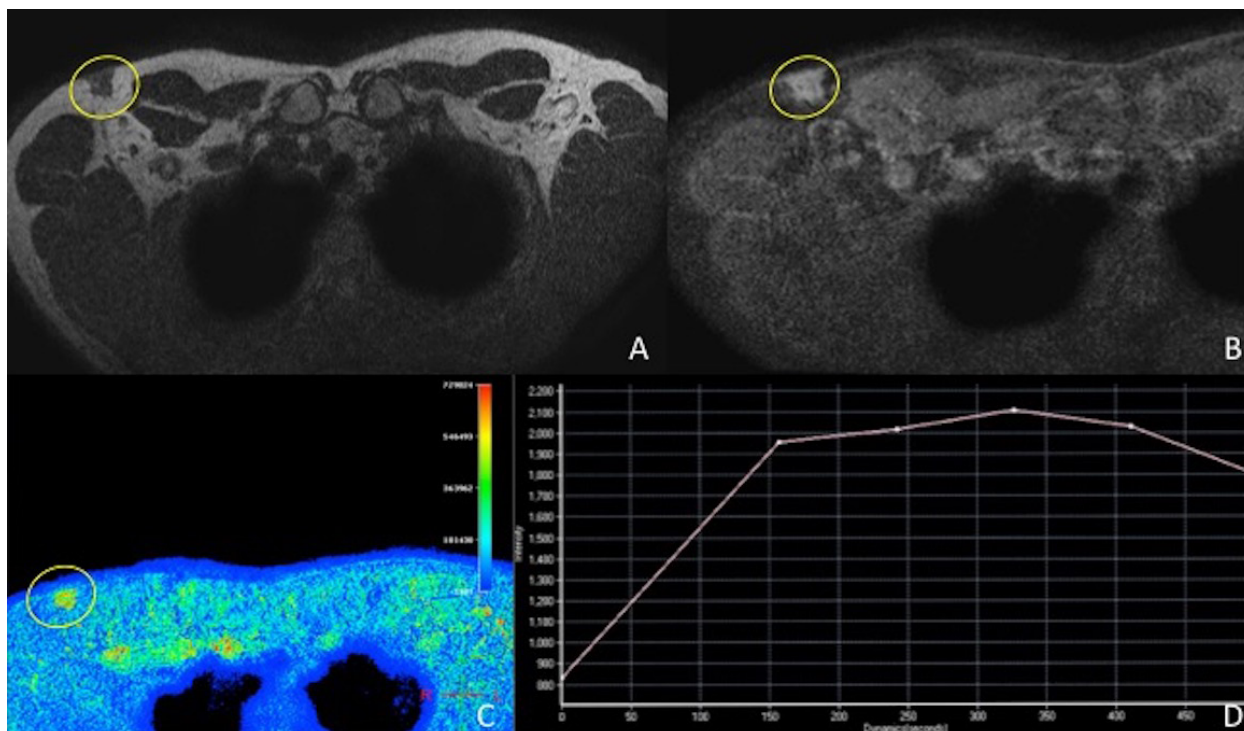


Figure 3 – Axial T2-weighted MR image (A) reveals a subcutaneous nodular lesion in axillary ectopic breast tissue in the right anterior axillary line (circle), with irregular borders, and intermediate to low signal intensity, measuring 16.4 mm of long axis. On axial (B, C) dynamic contrast-enhanced MR image this lesion (circle) shows early and progressive enhancement with an intensity peak after two minutes and a time-signal intensity curve with mild late washout (D).

The patient recovered from surgery and radiotherapy without complications and stays asymptomatic in eight months of follow-up.

## Discussion

EBT is synonymous of accessory breast tissue and polymastia. Its origin is related to the incomplete regression of the mammary ridges in embryogenesis process leading to the development of more than two breasts in one person.<sup>1,2,4-6</sup> It appears in the milk line, from the axilla (60-70%) to the vulva, which are the most common localizations of EBT.<sup>1-5</sup>

Up to 6% of the population presents EBT.<sup>1-4</sup> This finding is more frequent in women than in men, and as a higher prevalence in Asian population.<sup>6</sup>

EBT has two forms of presentation a supernumerary and an aberrant form. Supernumerary EBT vary in its components, and can have a nipple, areola, or both, associated to persistent or atrophic glandular tissue. It is histologically characterized by organized duct system communicating with the overlying skin. It is affected by the cycle hormonal changes.<sup>1,2,6,7</sup> Aberrant breast tissue (ABT) is defined on histology as isolated breast tissue without organized secretory system and with no relationship with the adjacent skin. ABT most frequent anatomical presentation is axillary, however it may appear in parasternal, subclavicular, submammary or vulvar locations. ABT is also influenced by hormonal variations. The true prevalence of ABT is unknown because is not visible or palpable in normal conditions. It is only detected when associated with clinically significant pathology.<sup>1,3,4,7</sup>

Benign and malignant pathologies of normally located breast tissue can occur in EBT.<sup>2,3</sup>

EBT carcinoma corresponds to 0.3-0.6% of all breast cancers.<sup>2,4,8</sup> Like on anatomic breast tissue, invasive ductal

carcinoma (79%) is the most common histological type, followed by medullary carcinoma, and less than 10% of these are lobular carcinomas.<sup>1-5</sup>

The axilla is the most common location of ABT carcinoma.<sup>7</sup> The correct preoperative diagnosis of ABT carcinomas is rarely achieved, because they have no associated nipple or areola, and are frequently mistaken with a subcutaneous nodule.<sup>5</sup>

The guidelines for anatomic breast cancer diagnosis showed be applied in EBT carcinoma, including diagnosis (core-needle biopsy), staging (clinical examination, mammography, ultrasonography, MR imaging), and treatment (surgery and adjuvant therapy).

EBT carcinomas most commonly present as a palpable lump on physical examination. Edema and tenderness can also be associated.<sup>5</sup>

Mammographic findings are nonspecific in most the cases, and best visualized on the mediolateral oblique or exaggerated craniocaudal views. Frequently, EBT appears as an axillary discrete focal asymmetric density of fibroglandular tissue mixed with fat tissue, showing no communication with the anatomic breast. When EBT carcinoma is present these features can become more dense, well circumscribed, assuming a nodular shape, and microcalcifications can also be found.<sup>6</sup>

On ultrasound EBT has the same appearance as normal glandular tissue. A poorly defined hypochogenic lesion, or with irregular margins and acoustic shadowing, without associated inflammation signs should be suspicious.<sup>5,6</sup>

To evaluate neoplasm locoregional extension a MRI should also be performed assessing both breasts and axilla.<sup>5,8,9</sup>

The evaluation of the contralateral axilla and breast is important, since 13% of anatomic breast cancers are bilateral.<sup>3,9</sup>

On histopathological analysis EBT carcinoma can be difficult to differentiate from axillary metastasis of another

primary origin carcinoma. The detection of estrogen and progesterone receptors and the visualization of normal ABT adjacent to the tumor are helpful factors in the accurate diagnosis of an EBT carcinoma.<sup>4,6,8</sup>

Anatomic breast carcinoma treatment approach should be the same for EBT carcinoma. Metastatic disease should be excluded. Surgical approach usually includes a wide local excision with sentinel lymph node biopsy. Adjuvant treatment for EBT carcinoma should follow the recommendations for normal breast cancers, including adjuvant radiotherapy to the EBT carcinoma site and to the regional lymph nodes.<sup>4-6,10</sup>

There is no proven benefit of radical or modified ipsilateral mastectomy or homolateral anatomic breast irradiation over local excision. However, in cases of undetermined origin of the tumor, axillary EBT carcinoma or axillary metastasis from unknown primary breast cancer, irradiation of the homolateral breast should also be performed.<sup>5,10</sup>

EBT carcinoma prognosis is thought to be worse than in normal breast tissue, mainly because of its rareness and difficulty in making an early diagnosis and also because metastasis to lymph nodes occur earlier and more commonly than in normal breast carcinoma.<sup>7,9,10</sup>

## Learning Points/Take Home Messages

A subcutaneous nodule of undetermined origin found at breast periphery should be evaluated very carefully.

Its evaluation should be performed similarly to breast examination, including physical exam, mammography and ultrasound.

In these situations, EBT carcinoma should always be excluded.

The early detection and treatment of EBT carcinoma is essential for its good outcome.

**Recebido / Received** 13/03/2017

**Aceite / Acceptance** 25/05/2017

### Divulgações Éticas / Ethical disclosures

*Conflitos de interesse:* Os autores declaram não possuir conflitos de interesse.

*Conflicts of interest:* The authors have no conflicts of interest to declare.

*Suporte financeiro:* O presente trabalho não foi suportado por nenhum subsídio ou bolsa.

*Financing Support:* This work has not received any contribution, grant or scholarship.

*Confidencialidade dos dados:* Os autores declaram ter seguido os protocolos do seu centro de trabalho acerca da publicação dos dados de doentes.

*Confidentiality of data:* The authors declare that they have followed the protocols of their work center on the publication of data from patients.

*Proteção de pessoas e animais:* Os autores declaram que os procedimentos seguidos estavam de acordo com os regulamentos estabelecidos pelos responsáveis da Comissão de Investigação Clínica e Ética e de acordo com a Declaração de Helsínquia da Associação Médica Mundial

*Protection of human and animal subjects:* The authors declare that the procedures followed were in accordance with the regulations of the relevant clinical research ethics committee and with those of the Code of Ethics of the World Medical Association (Declaration of Helsinki).

### References

1. Francone E, Nathan MJ, Murelli F, Bruno MS, Traverso E, Friedman D. Ectopic breast cancer: case report and review of the literature. *Aesth Plast Surg.* 2013;37:746–9.
2. Kahraman-Cetintas S, Turan-Ozdemir S, Topal U. Carcinoma originating from aberrant breast tissue. A case report and review of the literature. *Tumori.* 2008;94:440-3.

3. Devine C, Courtney C-A, Deb R, Agrawal A. Invasive lobular carcinoma arising in accessory breast tissue. *World Journal of Surgical Oncology* 2013;11:47.

4. DeFilippis EM, Arleo EK. The ABCs of Accessory breast tissue: basic information every radiologist should know. *American Journal of Roentgenology.* 2014;202:1157–62.

5. Soares A, Gonçalves J, Azevedo I, Pereira HG. Lobular ectopic breast carcinoma: A case-report. *Reports of Practical Oncology & Radiotherapy.* 2013;18:189–91.

6. Teke Z, Kabay B, Akbulut M, Erdem E. Primary infiltrating ductal carcinoma arising in aberrant breast tissue of the axilla: a rare entity. Report of a case. *Tumori.* 2008;94:577-83.

7. Rho JY, Juhng SK, Yoon KJ. Carcinoma originating from aberrant breast tissue of the right upper anterior chest wall. *J Korean Med Sci.* 2001;16:519-21.

8. Visconti G, Eltahir Y, Van Ginkel RJ, Bart J, Werker PMN. Approach and management of primary ectopic breast carcinoma in the axilla: Where are we? A comprehensive historical literature review. *Journal of Plastic, Reconstructive & Aesthetic Surgery.* 2011;64:e1–e11.

9. Dhebri A, Shah N, Sripadam R, Arora PK. Skin lesion in axilla: an unusual presentation of invasive lobular carcinoma of breast. *BMJ Case Reports.* 2012.

10. Sun L-M, Meng F-Y, Chang N-J, Lu C-Y, Lu T-H, Liang J-A, et al. Primary infiltrating ductal carcinoma of the axillary breast with metastasis to the contralateral chest wall. *Journal of the Chinese Medical Association.* 2013;76:354–7.