

Caso Clínico / Radiological Case Report

Pharyngeal Hairy Polyp Causing Respiratory Distress in Neonate

Hairy Polyp Faríngeo Causando Dificuldade Respiratória num Recém-Nascido

Maria Ana Serrado¹, João Lopes Dias², Ana Nunes², Eugénia Soares³

¹Interna do Internato Complementar em Radiologia, Serviço de Radiologia, Hospital Central do Funchal, SESARAM, E.P.E., Açores, Portugal

²Assistente Hospitalar, Serviço de Radiopediatria, Hospital Dona Estefânia, Centro Hospitalar de Lisboa Central, E.P.E., Portugal

³Coordenadora de Serviço, Serviço de Radiopediatria, Hospital Dona Estefânia, Centro Hospitalar de Lisboa Central, E.P.E., Portugal

Correspondência

Maria Ana Serrado
Rua Vale da Ajuda, nº9
9000-116 Funchal
Açores, Portugal
email: m_serrado@hotmail.com

Abstract

Pharyngeal hairy polyps are rare lesions that arise from the nasopharynx or oropharynx. It occurs predominantly in females, with predilection for the left side. Its etiology remains poorly understood. It typically presents in the neonatal period with respiratory distress and feeding difficulties. Imaging is fundamental to identify the high fat content of the lesion. Surgical resection is the treatment of choice. We report a case of a nasopharyngeal hairy polyp causing respiratory distress since birth.

Keywords

Neck; Nasopharynx; Oropharynx; Congenital, hereditary, and neonatal diseases and abnormalities; Pharyngeal neoplasms.

Resumo

Os hairy polyps faríngeos são lesões raras com origem na nasofaringe ou orofaringe. Ocorrem predominantemente no sexo feminino, com predileção para o lado esquerdo. A sua etiologia continua a ser mal compreendida. Apresenta-se tipicamente no período neo-natal com dificuldade respiratória e dificuldade na alimentação. Os métodos de imagem são fundamentais para identificar o conteúdo de gordura da lesão. A ressecção cirúrgica é a terapêutica de escolha. Apresentamos um caso clínico de um *hairy polyp* nasofaríngeo, causando dificuldade respiratória desde o nascimento.

Palavras-chave

Pescoço; Nasofaringe; Orofaringe; Doenças e alterações congénitas, hereditárias e neonatais; Neoplasias faríngeas.

Introduction

Despite being globally rare, hairy polyps are the most common congenital tumors of the naso-oropharynx. Imaging is fundamental in the differential diagnosis of neonatal pharyngeal masses. In the case of hairy polyps, the high fat content is the key.

We report the case of a 1-day-old girl with respiratory distress diagnosed with a nasopharyngeal hairy polyp after performing ultrasound (US), computed tomography (CT) and magnetic resonance imaging (MRI).

English language texts of the last 6 years (January 2011 to January 2017) were collected from PubMed/MEDLINE database using hairy polyp as key-word. Of 35 records, 29 full-text articles (mostly case reports/series) were selected, incorporating clinical data from 38 patients.

Case report

A new-born girl was delivered by caesarean section at 39 weeks and 6 days of gestation due to acute foetal distress. At birth, she presented with respiratory distress. APGAR scores at 1, 5 and 10 minutes were 6, 7 and 7, respectively. She was intubated at 5 minutes of life and extubated 5 minutes later. New intubation had to be performed and after several difficult attempts of extubation, steroid therapy was initiated, given the possibility of edema of the glottis. On the 4th day, a left, rounded, supra-glottic mass was identified during laryngoscopy.

US showed a well-defined, ovoid, pharyngeal lesion with mixed echogenicity, adjacent to the endotracheal tube. No vascularity was seen on colour Doppler (Fig. 1a and 1b). A contrast-enhanced CT was performed, showing a 35-mm, large lesion occupying the nasopharynx, displacing the endotracheal tube forward and to the left, and enveloping and displacing the naso-gastric tube to the left, extending from the base of the skull to the supra-glottis. It was hypodense, with a median density of 3 Hounsfield units (HU) and a minimum density of - 80 HU. No bony changes were identified (Fig. 2).

MRI confirmed the previous findings, depicting a cystic nasopharyngeal lesion, insinuating anteriorly into the choanas, and extending inferiorly to the level of the valleculae. It was hyperintense on T2-weighted images (T2WI). At the lower part of the lesion, spontaneous hyperintense content was found on T1-weighted images (T1WI), losing signal intensity with fat suppression. No intracranial extension was identified (Fig. 3a, 3b, 3c and 3d). Complete surgical resection was performed. The postoperative period was complicated by reopening of the ductus arteriosus. Favourable evolution with closure of the ductus arteriosus was achieved after conservative therapy. Macroscopically, a pink, pedunculated, polypoid lesion was documented. Histological examination showed a polypoid lesion covered by keratinizing stratified squamous epithelium, with hair follicles, sebaceous glands and a central core with adipose tissue, mature muscle tissue and

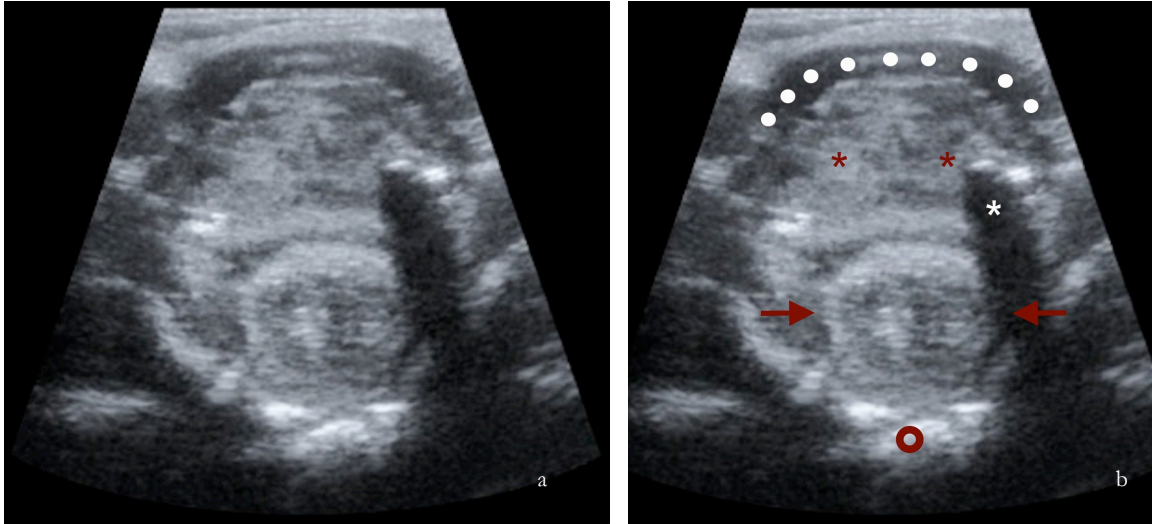


Figure 1 – (a, b) Transverse, oblique US image of the neck using a 13-5 MHz linear probe shows a well-defined ovoid lesion with mixed echogenicity within the pharynx (arrows), adjacent to the endotracheal tube (white asterisk). Mylo-hyoid muscles (white points); Tongue (red asterisks); Vertebral body (red circle).

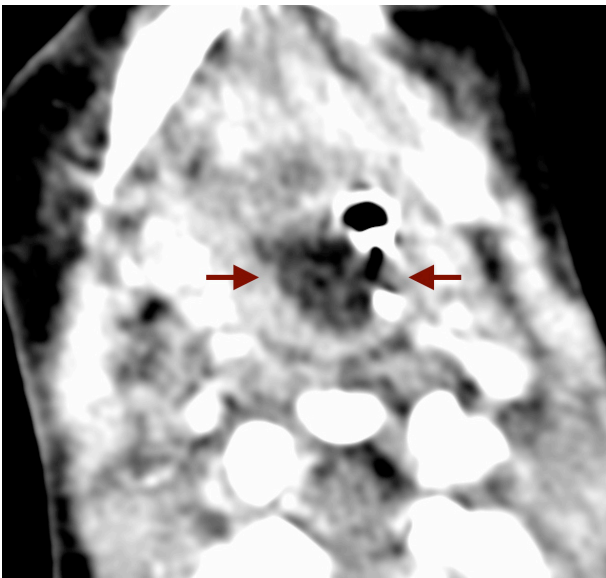


Figure 2 – Axial contrast-enhanced CT image shows a lesion occupying the nasopharynx (arrows), displacing the endotracheal tube forward and to the left, and enveloping and displacing the naso-gastric tube to the left.

cartilage. The distal margin of the tubular fragment was lined by respiratory epithelium, consistent with complete excision. These findings confirmed the diagnosis of hairy polyp.

Discussion

Hairy polyps are the most common congenital tumors of the naso-oropharynx. It derives from two germ layers, ectoderm and mesoderm. Ectoderm-derived tissues include keratinizing stratified squamous epithelium and skin appendages. Mesoderm component may include fibro-adipose tissue, muscle or cartilage. They are benign masses, with limited growth potential. Malignant transformation has never been reported. The incidence of hairy polyp is 1/40000 live births. It occurs predominantly in females, as seen in our case. Among cases in which there is reference to the laterality, a predilection by the left side was found.¹⁻⁴ It remains debatable whether hairy polyps are congenital defects like development malformations or primitive teratomas, or belong to the spectrum of neoplastic disorders.¹ Several theories about its origin have been

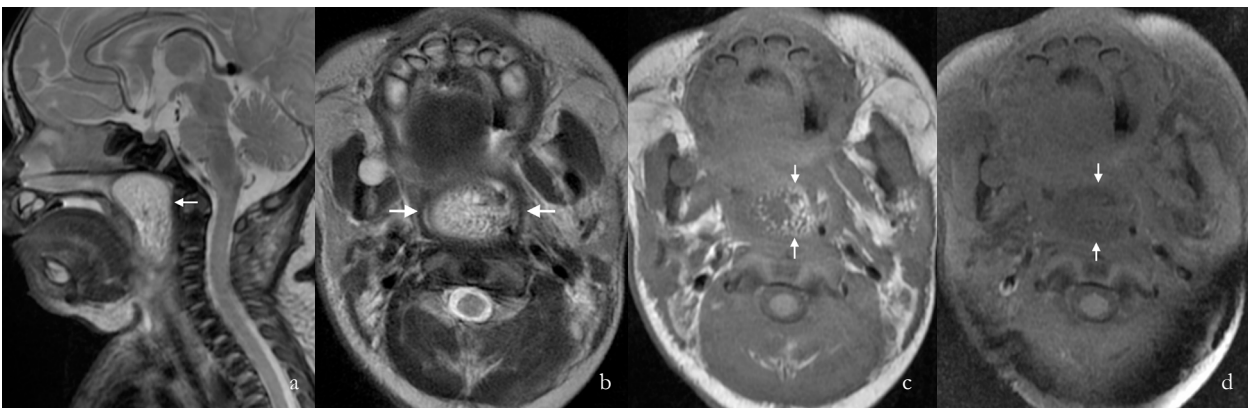


Figure 3 – (a,b) Sagittal and axial T2WI show a hyperintense lesion with epicenter in the nasopharynx (arrows), insinuating anteriorly through the choanas and extending inferiorly to the level of the valleculae. (c,d) Axial T1WI without and with fat-suppression show hyperintense fat content within the lesion, which loses signal intensity after fat suppression.

proposed. Burns et al⁵ suggested a second branchial arch origin, while Vaughn et al⁶ described a case associated with first branchial arch sinus. Interestingly, hairy polyps have also been described as accessory auricles^{7,8} Exceptionally, they can occur in adults.^{1,9}

In 2012, Yilmaz et al¹⁰ reviewed 35 cases corresponding to a period of 17 years. We performed a recent and larger review, including 38 cases from January of 2011 to January of 2017, a period of 7 years. We speculate that hairy polyps are not as rare as previously thought. More advanced methods of investigation, including imaging methods, may have permitted more diagnoses, mainly in less symptomatic patients.

Hairy polyps have been reported to arise from oropharynx, nasopharynx, soft palate, hard palate, tonsils, Eustachian tube, middle ear cavity, external auditory canal, and tongue.¹¹ In recent years, other locations have been described for the first time, such as the nasal vestibule, nasal septum, and lower lip.¹¹⁻¹⁴ They are usually solitary lesions, but there are some records of bilateral or two unilateral simultaneous lesions.^{9,15-17}

Hairy polyps do not represent any syndromic disorder nor have familiar predisposition, but are occasionally associated with cleft palate, uvular agenesis, ankyloglossia, facial hemihypertrophy, low-set ears, osteopetrosis, osteoporosis, hypospadias, left carotid artery atresia, agenesis of external auricle, bifurcation of tongue, branchial arch sinuses, and congenital hypothalamic hamartoma.^{1,11,18,19}

Clinical presentation depends on the size, location, shape and level of the hairy polyp, but it usually presents with respiratory distress and feeding difficulties in the neonatal period.¹ It can also be identified as a clinically detectable oral mass.^{4,20-22} Occasionally hairy polyp presents as masses with ischemic or hemorrhagic changes, presumably due to torsion.^{15,22-24}

Respiratory difficulties owing to blockage of upper respiratory tract can cause respiratory distress, cyanosis, stridor and acute airway emergency. Feeding problems often occurs in cases when it impinges the esophagus, thus leading to drooling, vomiting, coughing and gagging attacks.^{22,25} When the Eustachian tube is involved, chronic ear drainage, recurrent otitis media and hearing loss may occur.^{3,26,27} Neurological complications may occur secondary to vascular compressions and ischemia.^{2,10,20,28} Moreover, it is believed that the obstruction in fetal swallowing mechanisms may lead to polyhydramnios.^{21,22,25,29}

Koike et al³⁰ stated that polyps smaller than 3 cm in diameter have a higher risk of respiratory distress than do those bigger than 3 cm. Small hairy polyps are more difficult to diagnose and may be lethal because of delayed diagnosis.³⁰

In the workup of oropharynx or nasopharynx masses, imaging is essential to assess the origin and extent of the lesion, determine possible intra-cranial extension, exclude neurological and otorhynolaryngological complications, and plan surgery.²⁶

In newborns, US remains the first-line examination for the study of cervical masses. It is a safe and fast method of imaging that does not require sedation or anesthesia. However, US is operator-dependent and does not allow accurate visualization of deep structures. Hairy polyps typically show predominant high echogenicity due to the high fat content of the lesion. However, it often shows central low echogenicity, corresponding to its fibrous core, which may reveal vascularity on colour doppler.³¹

CT has the advantage of allowing for rapid acquisition times, thus avoiding deep sedation. Its main disadvantage is the use of ionizing radiation. Characteristic imaging features on CT include a smooth polypoid lesion with fat attenuation and a central linear soft tissue attenuation, that corresponds to the fibro-vascular stalk.^{26,31} It can also show bony changes.^{20-22,32-35}

MRI provides excellent depiction of soft tissues and does not use ionizing radiation.³⁶ The main disadvantage is the need of sedation or anesthesia. On MRI, a hairy polyp usually presents as a well-defined, non-enhancing mass with a relatively homogeneous matrix, surrounded by a smooth capsule.^{3,35} It is predominantly hyperintense on T1WI and T2WI, with loss of signal intensity with fat suppression techniques. The fibro-vascular stalk appears as a linear structure with intermediate signal on T2WI, which can enhance after intravenous contrast administration.²⁶ MRI is useful to delineate soft tissue extension and exclude intra-cranial involvement.^{33,35}

Typical imaging features can help narrow the differential diagnosis (Table 1). The high fat content is useful to exclude lesions such as neuroblastoma, meningo-encephaloceles, vascular anomalies, and embryonic cysts.^{22-24,31,34,37} At the same time, MRI narrows the differential diagnosis of a neonatal oropharyngeal or nasopharyngeal mass to hairy polyps, hamartomas, teratomas – which tend to be more heterogeneous –, and lipomas and their variants – which very infrequently occur not only in the pharynx but also in the neonate.²⁶

Cases of auto-amputation have rarely been reported.^{21,22-25} After ensuring the airway safety, the treatment of choice is surgical excision at the base of the stalk.^{10,25,34} The recurrence of hairy polyps is not usual. A case of progressive growth due to incomplete resection 6 years before was described.³⁸

Table 1 – Characteristic imaging features of hairy polyp

Lesion	Hairy polyp
US/Doppler	Hyperechogenic lesion, often with central low echogenicity. The central fibrous core may have flow signals on color Doppler.
CT	Smooth polypoid lesion with fat attenuation and a central linear soft tissue attenuation.
MR	Well-defined, homogeneous, non-enhancing mass, surrounded by a smooth capsule. Hyperintense on T1WI and T2WI, with loss of signal intensity with fat suppression. A linear central structure, with intermediate signal on T2WI, may enhance after intravenous contrast administration.

Conclusion

Although rare, hairy polyps should be considered in cases of respiratory distress at birth. In the workup of oropharynx or nasopharynx masses, imaging is essential to assess the origin and extent of the lesion, narrow the differential diagnosis, determine intra-cranial extension, exclude complications, and plan surgery. We believe that MRI is an excellent imaging method for characterizing nasopharyngeal lesions in neonates and assessing for their potential complications. After an initial US, which remains the first-line method in the study of cervical masses, MRI is preferable over CT due to lack of ionizing radiation and better depiction of soft tissues.

Divulgações Éticas / Ethical disclosures

Conflitos de interesse: Os autores declaram não possuir conflitos de interesse.
Conflicts of interest: The authors have no conflicts of interest to declare.

Suporte financeiro: O presente trabalho não foi suportado por nenhum subsídio ou bolsa.

Financing Support: This work has not received any contribution, grant or scholarship.

Confidencialidade dos dados: Os autores declaram ter seguido os protocolos do seu centro de trabalho acerca da publicação dos dados de doentes.

Confidentiality of data: The authors declare that they have followed the protocols of their work center on the publication of data from patients.

Proteção de pessoas e animais: Os autores declaram que os procedimentos seguidos estavam de acordo com os regulamentos estabelecidos pelos responsáveis da Comissão de Investigação Clínica e Ética e de acordo com a Declaração de Helsínquia da Associação Médica Mundial

Protection of human and animal subjects: The authors declare that the procedures followed were in accordance with the regulations of the relevant clinical research ethics committee and with those of the Code of Ethics of the World Medical Association (Declaration of Helsinki).

References

1. Dutta M, Roy S, Ghatak S. Naso-oropharynx choristoma (hairy polyps): an overview and current update on presentation, management, origin and related controversies. *Eur Arch Otorhinolaryngol.* 2014;272:1047-59.
2. Richter A, Mysore K, Schady D, Chandy B. Congenital hairy polyp of the oropharynx presenting as an esophageal mass in a neonate, a case report and literature review. *Int J Pediatr Otorhinolaryngol.* 2016;80:26-9.
3. Jin L, Zhang T. (2014) Surgical treatment of hairy polyp in the Eustachian tube. *Chin Med J.* 127:988-9
4. Seng S, Kieran SM, Vargas SO, McGill TJ. Caught on camera: hairy polyp of the posterior tonsillar pillar. *J Laryngol Otol.* 2013;127:528-30.
5. Burns BV, Axon PR, Pahade A. 'Hairy polyp' of the pharynx in association with an ipsilateral branchial sinus: evidence that the 'hairy polyp' is a second branchial arch malformation. *J Laryngol Otol.* 2001;115:145-8.
6. Vaughan C, Prowse SJ, Knight LC. Hairy polyp of the oropharynx in association with a first branchial arch sinus. *J Laryngol Otol.* 2012;126:1302-4.
7. Schuring AG. Accessory auricle in the nasopharynx. *Laryngoscope.* 1964;74:111-4.
8. Heffner DK, Thompson LD, Schall DG, et al. Pharyngeal dermoids ("hairy polyps") as accessory auricles. *Ann Otol Rhinol Laryngol.* 1996;105:819-24.
9. Franco V, Florena AM, Lombardo F, et al. Bilateral hairy polyp of the oropharynx. *J Laryngol Otol.* 1996;110:288-90.
10. Yilmaz M, Ibrahimov M, Ozturk O, et al. Congenital hairy polyp of the soft palate. *Int J Pediatr Otorhinolaryngol.* 2011;76:5-8.
11. Tariq MU, Din NU, Bashir MR. Hairy polyp, a clinicopathologic study of four cases. *Head Neck Pathol.* 2013;7:232-5.
12. Kim DH, Park SK, Kim B. Hairy polyp in Nasal Vestibule. *J Rhinol.* 2015;22:121-22.
13. White LJ, Shehata BM, Rajan R. Hairy polyp of the anterior nasal cavity. *Otolaryngol Head Neck Surg.* 2013;149:961-2.
14. Martín LP, Pérez MM, García EG, et al. Atypical case of congenital maxillomandibular fusion with duplication of the craniofacial midline. *Craniofacial Trauma Reconstr.* 2011;4:113-20.

15. Morgan J. A case of dermoid polypi of pharynx and nasopharynx. *J Laryngol Otol.* 1964;78:965-8
16. Chaudhry AP, Loré JM, Fisher JE, et al. So-called hairy polyps or teratoid tumours of the nasopharynx. *Arch Otolaryngol.* 1978;104:517-25.
17. Yilmazer R, Kersin B, Soyulu E, et al. Bilateral oropharyngeal hairy polyps: a rare cause of dyspnea in newborns. *Braz J Otorhinolaryngol.* 2017;83:117-8.
18. Cone BM, Taweevisit M, Shenoda S, et al. Pharyngeal hairy polyps: five new cases and review of the literature. *Fetal Pediatr Pathol.* 2012;31:184-9.
19. Desai A, Kumar N, Wajpayee M, et al. Cleft palate associated with hairy polyp: a case report. *Cleft Palate Craniofac J.* 2012;50:610-3.
20. Kelly A, Bough ID, Luft JD, et al. Hairy polyp of the oropharynx: case report and literature review. *J Pediatr Surg.* 1996;31:704-6.
21. Cheriathu JJ, Mohamed K, D'souza IE, Shamseldeen M. Autoamputation of congenital hairy polyp in neonate with stridor and respiratory failure. *WebmedCentral Paediatrics.* 2012;3:WMC003379.
22. Unal S, Eker S, Kibar A, et al. Autoamputation of a pharyngeal hairy polyp in a neonate with intermittent respiratory distress. *International Journal of Pediatric Otorhinolaryngology Extra.* 2008;3:90-3.
23. Varshney R, Pitaro J, Alghonaim Y, et al. Hemorrhagic hairy polyp causing velopharyngeal dysfunction in a newborn. *Cleft Palate Craniofac J.* 2015;52:625-8.
24. De Caluwé D, Kealey SM, Hayes R, Puri P. Autoamputation of a congenital oropharyngeal hairy polyp. *Pediatr Surg Int.* 2002;18:548-9.
25. Ince D, Turan O, Gemici HB, et al. Congenital hairy polyp and autoamputation in an infant with acute otitis media. *Turk J Pediatr.* 2014;56:324-6
26. Wu J, Schulte J, Yang C, et al. Hairy polyp of the nasopharynx arising from the eustachian tube. *Head Neck Pathol.* 2016;10:213-6.
27. Nalavenkata S, Meller C, Forer M, et al. Dermoid cysts of the Eustachian tube: a transnasal excision. *Int J Pediatr Otorhinolaryngol.* 2012;77:588-93.
28. Gambino M, Cozzi DA, Aceti MGR, et al. Two unusual cases of pharyngeal hairy polyp causing intermittent neonatal airway obstruction. *Int J Oral Maxillofac Surg.* 2008;37:761-2.
29. Mirshemirani A, Khaleghnejad A, Mohajerzadeh L, et al. Congenital nasopharyngeal teratoma in a neonate. *Iran J Pediatr.* 2011;21: 249-52.
30. Koike Y, Uchida K, Inoue M, et al. Hairy polyp can be lethal even when small in size. *Pediatr Int.* 2013;55:373-6.
31. Kraft JK, Knight LC, Cullinane C. US and MRI of a pharyngeal hairy polyp with pathological correlation. *Pediatr Radiol.* 2011;41:1208-11.
32. Christianson B, Ulualp SO, Koral K, et al. Congenital hairy polyp of the palatopharyngeus muscle. *Case Rep Otolaryngol.* 2013;374681.
33. Ibrahim N, Wooles NR, Elloy M, et al. A hairy situation. *BMJ Case Rep.* 2015.
34. Lepera D, Volpi L, De Bernardi F, et al. Endoscopic transnasal resection of Eustachian-tube dermoid in a new-born infant. *Auris Nasus Larynx.* 2015;42:235-40.
35. Zakaria R, Drinnan NR, Natt RS, et al. Hairy polyp of the nasopharynx causing chronic middle ear effusion. *BMJ Case Rep.* 2011.
36. Agrawal N, Kanabar D, Morrison GA. (2009) Combined transoral and nasendoscopic resection of an eustachian tube hairy polyp causing neonatal respiratory distress. *Am J Otolaryngol.* 2009;30:343-6.
37. Fawziyah A, Linder T. (2010) Oropharyngeal hairy polyps: An uncommon cause of infantile dyspnea and dysphagia. *Otolaryngol Head Neck Surg.* 2010;143:706-7.
38. Chang SS, Halushka M, Meer JV, et al. Nasopharyngeal hairy polyp with recurrence in the middle ear. *Int J Pediatr Otorhinolaryngol.* 2008;72:261-4.