

## Caso Clínico / Radiological Case Report

**ATYPICAL PRESENTATION OF COLON CANCER:  
PERFORATION WITH HEPATIC FISTULIZATION****APRESENTAÇÃO ATÍPICA DE NEOPLASIA DO CÓLON: PERFURAÇÃO COM  
FISTULIZAÇÃO HEPÁTICA****Joana Ruivo Rodrigues<sup>1</sup>, Bernardete Rodrigues<sup>1</sup>, Nuno Ribeiro<sup>1</sup>, Carla Filipa Ribeiro<sup>1</sup>, Ângela Figueiredo<sup>1</sup>, Alexandre Mota<sup>1</sup>, Daniel Cardoso<sup>1</sup>, Pedro Azevedo<sup>1</sup>, Duarte Silva<sup>1</sup>**<sup>1</sup>Serviço de Radiologia do Centro Hospitalar Tondela-Viseu, Viseu  
Diretor: Dr. Duarte Silva**Correspondência**Joana Ruivo Rodrigues  
Rua Dr. Francisco Patrício Lote 2 Fração A  
6300-691 Guarda  
e-mail: joana.ruivo130@gmail.comRecebido a 16/11/2015  
Aceite a 05/01/2016**Abstract**

One of the known and rare complications of the colon cancer is perforation, with fistulas or abscesses formation. In this paper it is reported the case of a 61 year old man who presented himself with pain and a palpable mass in the right upper abdominal quadrant in association with fever and weight loss. The radiological investigation showed findings compatible with perforated colon cancer and hepatic fistulization. An emergent surgery was performed and confirmed the radiologic suspicion.

**Key-words**

Colon cancer; Perforation; Hepatic fistulization.

**Resumo**

Uma das complicações conhecidas e raras da neoplasia do cólon é a perfuração com formação de fistulas ou abscessos. Neste artigo relata-se o caso de um homem de 61 anos de idade, que apresentava dor abdominal e uma massa palpável no quadrante superior direito, em associação com febre e perda ponderal. A investigação radiológica mostrou achados compatíveis com perfuração de neoplasia do cólon e fistulização hepática. Foi realizada uma cirurgia emergente que confirmou a suspeita radiológica.

**Palavras-chave**

Cancro do cólon; Perfuração; Fistulização hepática.

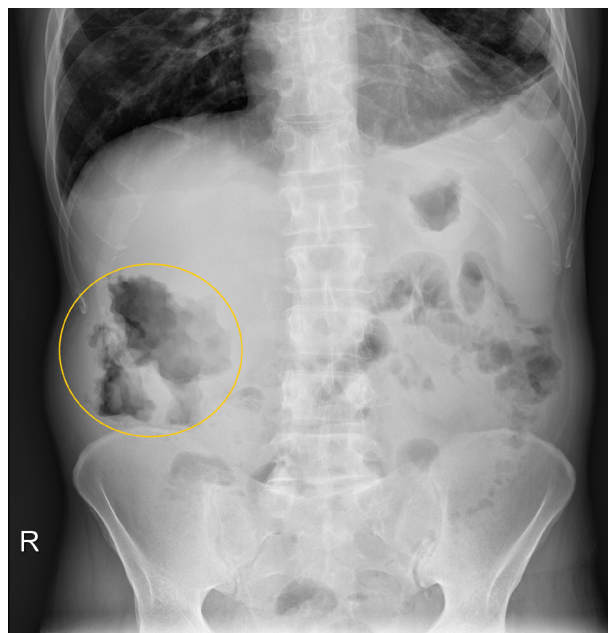
**Introduction**

The incidence of colon cancer has increased among colorectal cancers<sup>1</sup>. Many complications can appear in patients with colon cancer which requires emergent surgical management such as acute bowel obstruction, perforation, ischemic colitis and intussusception<sup>2</sup>. These complications can obscure clinically and/or radiologically the underlying colon cancer and they may result in a delayed diagnosis and treatment<sup>3</sup>. Perforation and penetration of adjacent organs with intra-abdominal abscess<sup>4</sup> or fistula formation are rare initial presentations of the colon cancer, being the carcinoma the minor cause of gastrointestinal fistula<sup>5</sup>.

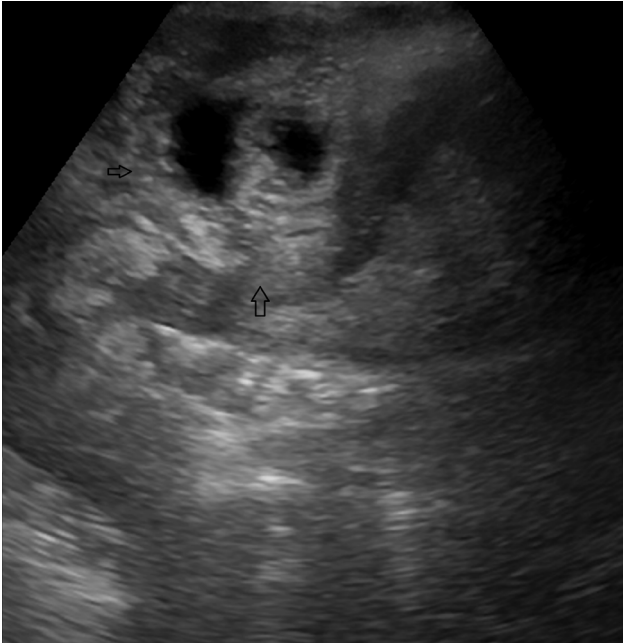**Case Presentation**

A 61-year-old man presented to our department with abdominal pain in the right upper quadrant, for two weeks, in association with fever and weight loss. At physical examination the patient had a palpable tumefaction in the right upper quadrant. Laboratorial investigation revealed anemia, mild hypoalbuminemia, elevated white cell blood count and C-reactive protein. The abdominal X-ray showed pocketed air collections, with round shape and irregular borders, in the topography of the right upper quadrant (Fig. 1).

An ultrasound scan was performed. It revealed a heterogeneous mass adjacent to the hepatic parenchyma and to colonic loops, at the right upper quadrant (Fig. 2). In order to characterise the lesion an abdominal Computed Tomography (CT) was



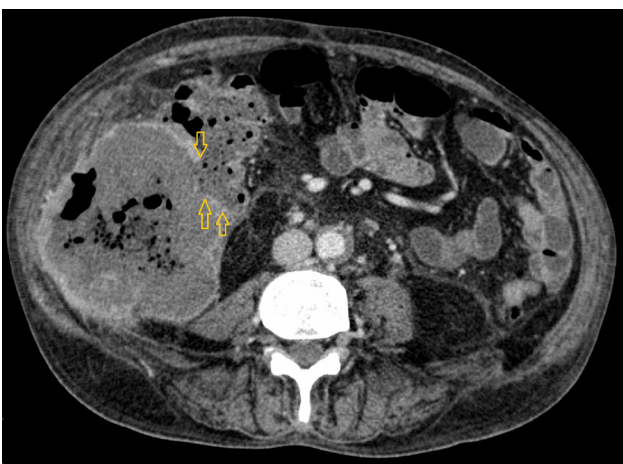
**Figure 1** – Abdominal radiography depicting loculated air collections (circle) at the right upper quadrant.



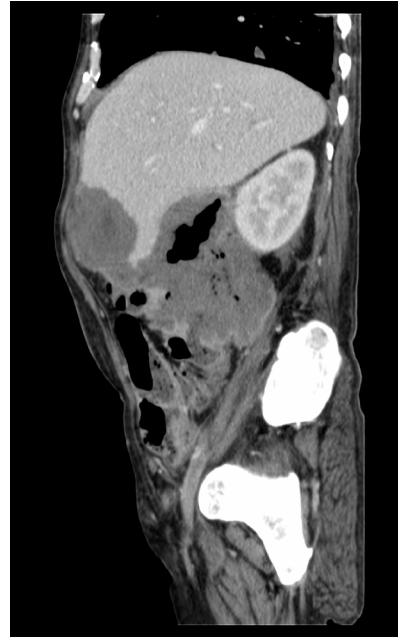**Figure 2** – Ultrasound image showing a heterogeneous mass (arrows) between the hepatic parenchyma and colonic loops.

performed. The CT showed a collection with multiloculated and heterogeneous appearance located in the hepatic parenchyma with a sinus tract to the adjacent loop of the ascending colon. It also showed stranding of the pericolic fat and free peritoneal fluid. (Figs. 3, 4, 5).

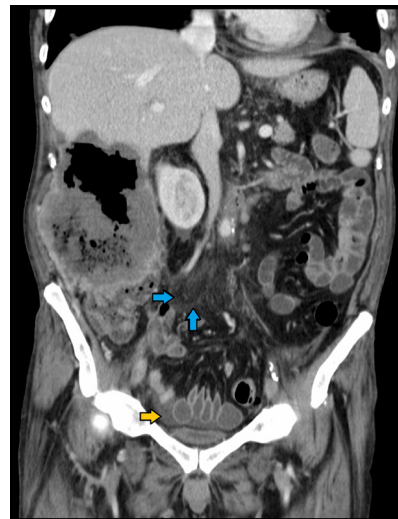An emergent surgery was performed and confirmed the presence of a mass involving the hepatic colonic angle, the liver and the abdominal wall. During the surgery faecal material was drained and two drain tubes were placed, one in sub-hepatic position and another one was placed adjacent to the colonic perforation. A loop ileostomy was performed. The histological result of the intraoperative collected material that revealed necrotic tissue and architectural aspects that suggested neoplastic etiology. The patient died a few days after the surgery.



**Figure 3** – Contrast enhanced Computed Tomography axial image depicting the fistulous tract (arrows) between the colon wall and the collection.



**Figure 4** – Contrast enhanced Computed Tomography sagittal image showing a heterogeneous multiloculated collection, due to the presence of fecal material, air and fluid.



**Figure 5** – Contrast enhanced Computed Tomography coronal image showing fat stranding (blue arrows) adjacent to the collection and free peritoneal fluid (yellow arrow).

## Discussion

Perforation caused by colon cancer is rare in clinical practice<sup>1</sup>, its frequency rounds 2.5-10%, of patients with colon cancer<sup>3</sup>. The majority of perforation cases occur in patients with acute obstruction. Only in a few amount of colonic cancer cases ulcerations are present, usually due to penetration of the tumour mass through the intestinal wall<sup>1</sup>. Perforation can appear as a free perforation to the peritoneum or as a localized perforation with an abscess or fistula formation<sup>4</sup>. Haldane in 1862<sup>6</sup> was the first author to describe malignant fistula of the gastrointestinal tract. When the fistulous tract occurs between the colon and adjacent structures, it can result in an abscess formation<sup>3</sup>, as occurs in the case here reported.

Clinical presentation of a perforated colon cancer is characterized by a palpable abdominal mass, abdominal pain, and anemia<sup>4</sup>.

There are many potential causes of colonic perforation, including malignant neoplasm, diverticulitis, trauma, ischemia, inflammatory bowel disease and stercoral colitis.

---

These causes of colonic perforation can be diagnosed by CT. When colonic perforation is present, CT can show a focal defect in the colon wall that may be accompanied by a fluid-density abscess, pneumoperitoneum or stranding of the pericolic fat<sup>3</sup>. There are some specific CT findings that are more commonly found in colon cancer than in benign conditions, such as irregular wall colon thickening, pericolic lymphadenopathy<sup>3</sup> and gas within the tumour<sup>2</sup>.

A perforated colon carcinoma has a poor prognosis and a higher surgical mortality<sup>7</sup>, associated with intra-abdominal sepsis and locally advanced malignancy<sup>8</sup>. The best patient management depends on the establishment of the diagnosis of both neoplasia and perforation<sup>7</sup>. When a colon cancer

perforation is confirmed, an emergency surgery should be done immediately, in association with systemic support and antibiotic treatment. In the presence of a ruptured and unresectable tumour, a proximal double-lumen colostomy should be performed, during which the lesion should be adequately repaired and washed, along with adequate drainage<sup>1</sup>.

Perforation of a colon cancer with hepatic fistulization is an atypical presentation of colon cancer, which requires a prompt diagnosis and management. CT is the best imaging modality to diagnose this complication. Furthermore we believe that this modality is reliable for facilitating a pre-operative diagnosis in this type of colon cancer complications.

#### References

1. Yang XF, Pan K. Diagnosis and management of acute complications in patients with colon cancer: bleeding, obstruction, and perforation. *Chin J Cancer Res.* 2014;26(3):331-40.
2. Katabathina VS, Restrepo CS, Cuellar SLB, Riascos RF, Menias CO. Imaging of Oncologic Emergencies: What Every Radiologist Should Know. *RadioGraphics.* 2013;33:1533-53.
3. Kim SW, Shin HC, Kim IY, Kim YT, Kim CJ. CT findings of colonic complications associated with colon cancer. *Korean J Radiol.* 2010;11(2):211-21.
4. Tsai HL, Hsieh JS, Yu FJ, Wu DC, Chen FM, Huang CJ, et al. Perforated colonic cancer presenting as intra-abdominal abscess. *Int J Colorectal Dis.* 2007;22(1):15-9.
5. Takahashi M, Fukuda T. Ileorectal fistula due to a rectal cancer—A case report. *Int J Surg Case Rep.* 2011;2(2):20-1.
6. Haldane DR. Case of cancer of the cecum accompanied with cecoduodenal and cecocolic fistulae. *Med J Edinburgh.* 1862;7:624-9.
7. Hulnick DH, Megibow AJ, Balthazar EJ, Gordon RB, Surapenini R, Bosniak MA. Perforated colorectal neoplasms: correlation of clinical, contrast enema, and CT examinations. *Radiology.* 1987;164(3):611-5.
8. Mandava N, Kumar S, Pizzi WF, Aprile IJ. Perforated colorectal carcinomas. *Am J Surg.* 1996;172:236-8.