

Images of Interest / Imagens de Interesse

Infarction of Torsed Lipomatous Appendage of the Falciform Ligament*Enfarte de apêndice lipomatoso torcido do ligamento falciforme***Carlos Francisco Silva, Vanessa Praxedes, Ana André**Centro Hospitalar de Setúbal, Serviço de
Imagiologia, Setúbal, Portugal**Address**Carlos Francisco Silva
Centro Hospitalar de Setúbal
Serviço de Radiologia
Rua Camilo Castelo Braco
2910-446 Setúbal, Portugal
email: carlos.f.silva@chs.min-saude.pt**Abstract**

A 46-year-old man presented sudden onset of severe pain in the right upper quadrant. On abdominal examination, a well-defined pain and a subtle lump were obvious. Abdominal x-ray, ultrasound and laboratory tests were unremarkable. An abdominal CT scan was then requested, showing fat stranding and a torsed appearance of a lipomatous appendage of the falciform ligament, compatible with infarction. The pathophysiology of this entity is similar to the more commonly seen omental infarction and epiploic appendagitis, covering the spectrum of intra-abdominal focal fat infarction, recently described in literature.

Keywords

Infarction; Lipomatous appendage; Falciform ligament.

Resumo

Homem de 46 anos, apresentando forte dor súbita no hipocôndrio direito. Na avaliação abdominal evidenciava-se um ponto algíco e pequena tumefação bem definidos. Radiografia abdominal, ecografia e exames laboratoriais sem alterações dignas de registo. Foi então solicitada uma tomografia computadorizada abdominal, demonstrando sinais inflamatórios e aspetos de torção num apêndice lipomatoso do ligamento falciforme compatível com enfarte. A fisiopatologia desta entidade é semelhante ao enfarte omental mais comumente observado e à apendicite epiploica, abrangendo o espectro do enfarte focal de gordura intra-abdominal, recentemente descrito na literatura.

Palavras-chave

Enfarte; Apêndice lipomatoso; Ligamento falciforme.

A 46-year-old male presented sudden onset of severe pain in the right upper quadrant. On abdominal examination, a well-defined point of focal tenderness and a subtle lump were evident. Abdominal x-ray, ultrasound and laboratory tests were unremarkable. An abdominal CT scan was then requested, however, the report from an outsourced company suggested normal findings. After revision, the following morning, by a local attending radiologist and multidisciplinary discussion, the diagnosis was performed with ease. CT showed fat stranding in a lipomatous appendage of falciform ligament compatible with infarction (Fig.1 and 2). Although without surgical or histopathological proof, the similarities with other reported cases are striking.¹⁻³

The pathophysiology of this condition is similar to the more commonly seen omental infarction and epiploic appendagitis, encompassing the spectrum of intra-abdominal focal fat infarction (IFFI) that has recently been described.^{2,4}

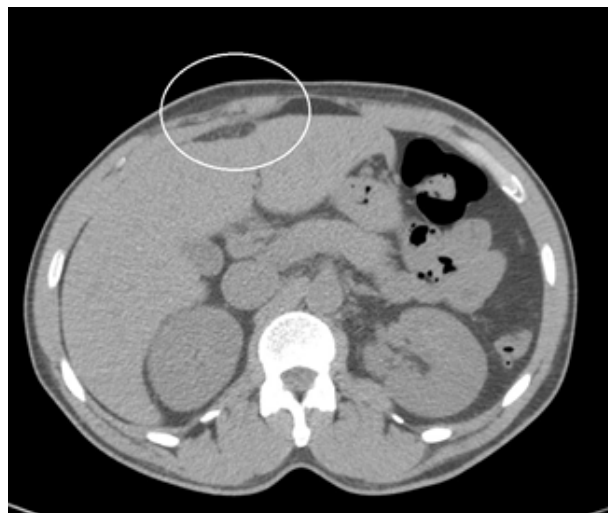

Figure 1 – Axial CT image showing fat stranding in a lipomatous appendage of the falciform ligament compatible with infarction. The surrounding inflammatory changes in the adjacent fat and myofascial planes give rise to a subtle focal cutaneous lump, evident if we compare it with the contralateral side.

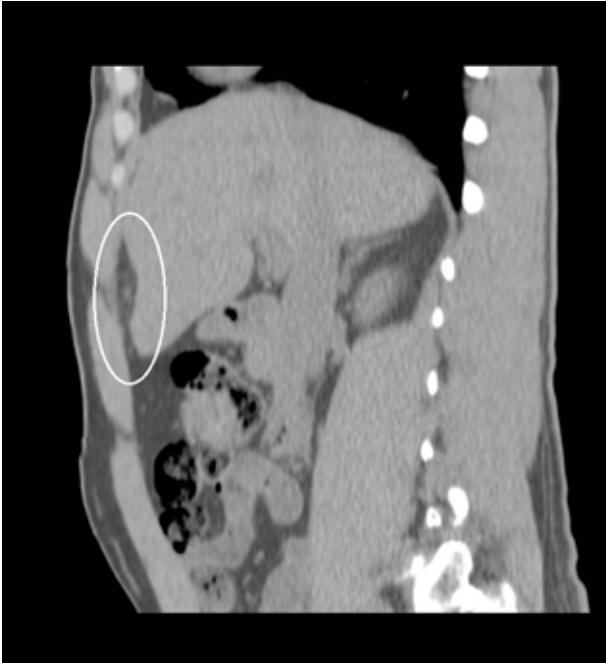


Figure 2 – Sagittal CT image depicting the longitudinal extent of the lipomatous appendage and the mass effect on liver surface with a prominent inward bulging. Also in better detail the extent of the fat stranding, and the “dot sign”, as similarly described by Uyttenhove F et al. in their case report³, caused by thrombosis of the vessels in the center of the lipomatous appendage.

Received / Recebido 13/03/2017

Acceptance / Aceite 25/05/2017

Ethical disclosures / Divulgações Éticas

Conflicts of interest: The authors have no conflicts of interest to declare.

Conflitos de interesse: Os autores declaram não possuir conflitos de interesse.

Financing Support: This work has not received any contribution, grant or scholarship.

Suporte financeiro: O presente trabalho não foi suportado por nenhum subsídio ou bolsa.

Confidentiality of data: The authors declare that they have followed the protocols of their work center on the publication of data from patients.

Confidencialidade dos dados: Os autores declaram ter seguido os protocolos do seu centro de trabalho acerca da publicação dos dados de doentes.

Protection of human and animal subjects: The authors declare that the procedures followed were in accordance with the regulations of the relevant clinical research ethics committee and with those of the Code of Ethics of the World Medical Association (Declaration of Helsinki).

Proteção de pessoas e animais: Os autores declaram que os procedimentos seguidos estavam de acordo com os regulamentos estabelecidos pelos responsáveis da Comissão de Investigação Clínica e Ética e de acordo com a Declaração de Helsínquia da Associação Médica Mundial

References

1. Swienton D, Shah V. Infarction of a fatty appendage of the falciform ligament - a case report. EuroRad Online 11 April 2013. Available from: <http://www.eurorad.org/case.php?id=10799>.
2. Maccallum C, Eaton S, Chubb D, Franzl S. Torsion of fatty appendage of falciform ligament: Acute abdomen in a child. Case Rep Radiol. 2015;293491
3. Uyttenhove F, Leroy C, Nzamushe L, Lapan M, Mabl JR, Ernst O. Torsion of a fatty fringe of the falciform ligament, a rare cause of right hypochondrial pain. Diagn Interv Imaging. 2013;94:637-9.
4. Van Breda Vriesman AC, Lohle PN, Coerkamp EG, Puylaert JB. Infarction of omentum and epiploic appendage: diagnosis, epidemiology and natural history. Eur Radiol 1999;9:1886-92.