

## Caso Clínico / Radiological Case Report

# RESECTOSCOPIC RESECTION OF A LARGE SUBMUCOUS UTERINE MYOMA

## RESSECÇÃO RESSECTOSCÓPICA DE UM MIOMA SUBMUCOSO DE GRANDES DIMENSÕES

Gonçalo Inocêncio<sup>1</sup>, António Braga<sup>1</sup>, Ana Galvão<sup>1</sup>, Rosa Zulmira<sup>1,2</sup>

1 - Serviço de Ginecologia e Obstetrícia, Departamento da Mulher e da Medicina Reprodutiva do Centro Hospitalar do Porto  
2 - Coordenadora da Cirurgia Ginecológica em Ambulatório (Centro Integrado de Cirurgia de Ambulatório do Porto-CICA)

### Correspondência

Gonçalo Inocêncio  
Address: Rua Calouste Gulbenkian, n53, 5H5  
4050 Porto  
e-mail: dr.inocencio@gmail.com

Recebido a 05/06/2014  
Aceite a 06/07/2014

### Abstract

Submucous myoma(s) can decrease the chances of a spontaneous conception and, therefore, be a cause of reproductive failure. There are many different methods for submucous myoma(s) treatment. The choice for the best treatment approach should take into account the characteristics of the myoma: the size, number (single or multiple), location and its relationship with the myometrium/uterine cavity; Also, the age of the woman and her desire for procreation have great influence when choosing the best treatment method.

The intrauterine endoscopic techniques are currently widely used and considered minimally invasive surgical procedures. We present a case of a 32-year-old nulliparous woman, attempting to get pregnant, who was diagnosed with a large submucous uterine myoma. A successful resection, of a 5,8 cm greater diameter submucous myoma, was made by resectoscopic surgery.

### Key-words

Fibroid; Imaging mapping of uterine myoma; Myoma; Resectoscope.

### Resumo

Mioma submucoso pode diminuir a probabilidade de uma concepção espontânea e, portanto, ser uma causa de falha reprodutiva.

Existem variados métodos para tratamento de mioma(s) submucoso(s). A escolha da melhor forma de tratamento deve ter em conta as características do mioma: o tamanho, número (único ou múltiplo), localização e sua relação com a cavidade uterina/miométrio; Além disso, a idade da mulher e seu desejo de procriação têm grande influência na escolha do melhor método de tratamento.

As técnicas endoscópicas intra-uterinas são actualmente amplamente utilizadas e consideradas procedimentos cirúrgicos minimamente invasivos.

Apresentamos um caso de uma mulher nulípara de 32 anos, a tentar engravidar, diagnosticada com um grande mioma uterino submucoso (5,8 cm de maior diâmetro). Foi realizada a ressecção do mioma por ressectoscopia cirúrgica com sucesso.

### Palavras-chave

Fibromioma; Caracterização imagiológica de mioma uterino; Mioma; Ressectoscopia.

## Introduction

Uterine fibroids, also known as uterine myoma, leiomyoma, fibromyoma or fibroleiomyoma, are the most common benign tumours found in the female genital tract. They can be detected in approximately 20–25% of women in reproductive age. [1,2] Of all characteristics of a myoma, it is believed that location is the main factor determining the frequency and severity of symptoms. Submucous myomas represent 5-10% of all uterine fibroids [3] and they are one of the causes responsible for signs/symptoms such as: increased blood loss during menstrual period causing, subsequently, anemia, dysmenorrhoea and/or infertility.[1-2, 4]

Submucous myomas can be classified according to its extent of penetration into the myometrium. Therefore, submucous myoma G0 is the one that is completely within the uterine cavity, connected only by a thin pedicle to the uterine wall; G1

has its larger part >50% protruding into the uterine cavity, while G2 has its larger part >50% within the myometrium.[5] Laparotomic myoma excision or hysterectomy, have long been the common surgical treatment approaches for symptomatic submucous myomas.[6]

However, due to creation of new/better instruments and development of new surgical techniques, endoscopic myomectomy has spread worldwide as a standard treatment method for submucous myomas.[7]

We present a successful case of a resectoscopic resection of a large submucous uterine myoma in a nulliparous woman.

## Case report

Nulliparous 32-year-old woman, with irrelevant medical history, trying to get pregnant during the last 2 years. She came to the urgency department because of heavy and prolonged

menstrual period. The physical gynaecological examination was completely normal, except for the confirmation of heavy bleeding. She referred that her cycles were regular (28 days), but her menstrual period duration was getting longer, superior to 8 days in the last 3-6 months, associated with heavy bleeding. She did not refer other symptoms such as dysmenorrhoea or dyspareunia. She also denied history of epistaxis, gingivorrhagia or easy bruising after trauma.

The blood count was normal except for haemoglobin of 10.9gr/dL normocytic normochromic.

A transvaginal ultrasound scan was performed and revealed the suspicion of a submucous myoma with 5 cm greater diameter.

She was discharged from the urgency department on the same day, medicated with continuous combined oral estroprogestative and iron, up to her gynaecological consultation. A hysterosonography was performed and confirmed the existence of a submucous myoma, located in the anterior-left uterine wall, with 5,8 cm greater diameter, with its larger part (>50%) in the uterine cavity (G1) – see figure 1 and 2. After explaining the advantages and disadvantages of the various options of treatment, the removal of the myoma by resectoscopic surgery in one or two-step procedure was proposed and accepted by the patient.

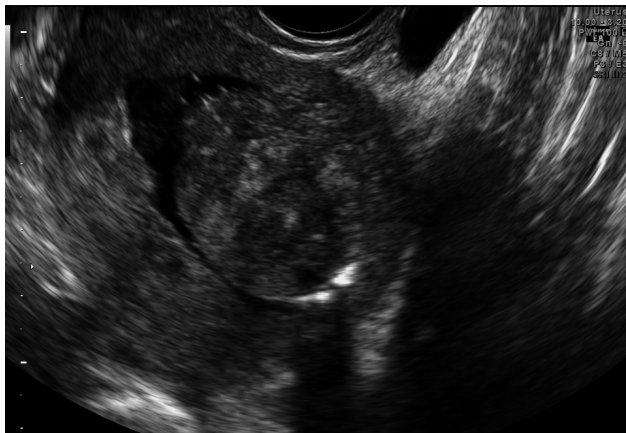The resectoscope chosen for surgery was the bipolar Fr resectoscope (Gynecare) with the 2.5mm cutting loop.

After entering the uterine cavity, the G1 submucous myoma was visualized measuring subjectively 6 cm greater diameter. The myoma was completely removed after this single, 55 minutes duration, surgical approach. There were no complications during the procedure. The patient was discharged on the same day, 7 hours after the surgery.

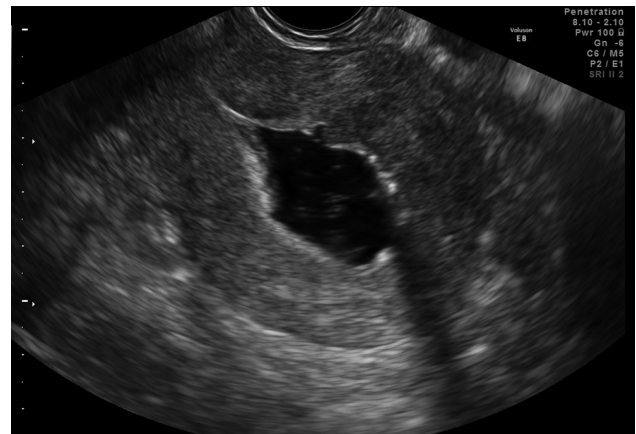Continuous combined oral estroprogestative and iron were maintained till the 21<sup>st</sup> pos-operative day.

The pathological examination revealed leiomyoma.

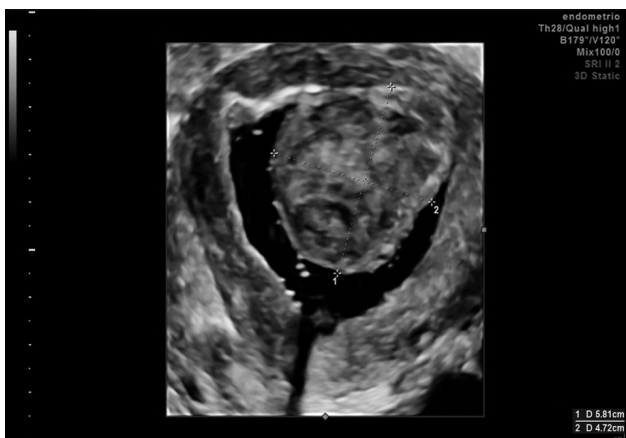
A transvaginal ultrasound scan/hysterosonography was performed after her first pos-operative menstrual period, which occurred immediately after the suspension of the combined oral estroprogestative therapy. There were no abnormal findings during the imaging examination, confirming the surgery success in the complete removal of submucous myoma - see figure 3.



**Fig. 1 -** 2D hysterosonography of the submucous myoma (Voluson E8 system (GE Healthcare, Zipf, Austria))



**Fig. 3 -** Empty uterine cavity, confirmed by hysterosonography, after successful resectoscopic resection of the submucous uterine myoma (Voluson E8 system (GE Healthcare, Zipf, Austria))



**Fig. 2 -** 3D hysterosonography of the same submucous myoma (Voluson E8 system (GE Healthcare, Zipf, Austria))

## Discussion

Nowadays there is sufficient scientific evidence that allows us to state that myomas, especially those with submucous component, can have a negative impact on fertility.[8] Our case represents a nulliparous woman, trying to get pregnant, with heavy and prolonged menstrual periods.

After making the diagnosis of submucous myoma by transvaginal ultrasound scan, we decided to perform also a hysterosonography in order to better characterize the myoma location, size and its relationship with the uterine cavity/myometrium. Using the STEP-W submucous fibroid classification proposed by Lasmar RB[9], our case would be classified as: Size >5cm (score 2); Upper topography (score 2); Extension of the base <1/3 (score 0); Penetration <50% (score 1); reaching the uterine lateral wall (score 1); total score: 6, which corresponds to group II – high complexity hysteroscopic myomectomy. Hysteroscopy could be another possibility, with advantages such as allowing performing biopsy of the neof ormation or characterizing the endometrium. However, in our point of view, besides being a more expensive, painful and technically more difficult exam when compared with hysterosonography, there is the possibility of the myoma to sink into the myometrium/uterine wall due to an increase intracavitary uterine pressure by the distension medium,[10] leading to an erroneous classification of the myoma.

There are many different surgical treatment approaches for submucous myoma removal. Abdominal hysterectomy and uterine artery embolization were immediately excluded towards a nulliparous woman who aims to become pregnant. We also decided not to opt for laparoscopic myomectomy, since this would involve the opening of the uterine wall till the cavity, which may distort the uterine cavity and/or create endometrial or pelvic adhesions compromising fertility and/or the woman's future obstetric outcome, since the risk of uterine rupture is not negligible and the mode of delivery would probably be an elective caesarean section.

Intrauterine endoscopic myomectomy is a recent treatment option with high efficiency rate and the advantage of being a minimally invasive surgical procedure. There are several different techniques for this kind of surgical approach: resectoscopic myoma removal; ablation by neodymium-yttrium-aluminum-garnet (Nd:YAG) laser; vaporization of myoma; intra-uterine morcellation. Of these methods we chose to perform a resectoscopic excision of the submucous myoma since: vaporization or laser ablation besides being more costly methods and technically more difficult to perform because of gas bubbles formation that can reduce operator visibility, they also do not allow to collect material for histopathologic examination; when compared with resectoscopic myomectomy, hysteroscopic morcellation seems to reduce intraoperative time in 8 to 26 minutes.[11, 12] Nevertheless, this technique is limited to treat myomas with intramural component and is still lacking data about long term outcome and/or comparison of perioperative complications.[13]

The resectoscopic myoma removal was performed using the classical technique of ablation by slicing, characterized by repeated and progressive movements of the cutting loop, starting on the top and distal part of the myoma, towards proximal part till the base of the myoma.

Hysteroscopic myomectomy may be associated with various complications, such as: laceration of the cervix, uterine wall perforation, haemorrhage, excessive fluid absorption, urinary tract and/or bowel lesions. In our case, excessive fluid absorption was one of our main concerns, mainly due to the fact that myomectomy of larger fibroids are usually more time-consuming procedures. Precautions were taken in order to avoid this kind of complication: we tried to maintain the intrauterine fluid pressure as low as possible as long as we had

optimal visualization and stop the procedure, either if the operating time exceeds more than 1 hour, or if the fluid deficit reaches 1 or 2 liters maximum, especially in young healthy patients, like in our case. Furthermore, the fibroid resection of our case neither had moderate or major bleeding, nor had the need of large endometrium ablation that are two main risk factors responsible for complications related to increased absorption of fluid.

The best surgical approach regarding the size of the myoma is still controversial. Myomas G1 should not be bigger than 5–6cm, while myomas G2 should not exceed 4–5 cm, to be removed by intra uterine endoscopic techniques.[14]

There is also a debate whether women with submucous myomas should be treated or not with GnRH analogs prior to surgery. Donnez[15] *et al* suggested that myomas with less than 2cm diameter do not require any pre surgical treatment. Moreover, GnRH agonist should be a treatment option for those women with myomas exceeding 4cm. Okohue[16] made a literature review about if there is a role for preoperative treatment with GnRH agonist and concluded that GnRH agonist used prior to hysteroscopic myomectomy probably helps reducing the size of the myoma and improving haemoglobin level, especially in anemic patients. Nevertheless, Campo[6] *et al* after comparing resectoscopic myomectomy with and without pretreatment with GnRH analogs in premenopausal women stated that the administration of GnRH agonist, although improving haemoglobin values in women with secondary anemia, did not result in better short and/or long term outcome following the intra uterine endoscopic procedure. Since the level of the haemoglobin of our patient was not a concern, we decided not to administer GnRH agonist. Instead we opted for continuous combined oral estroprogestative and iron therapy in an attempt to induce amenorrhea, to recuperate haemoglobin to normal values and better possibility of surgical scheduling.

In conclusion, preoperatively characterization / imaging mapping of the myoma (size, topography, extension of the base of the myoma, penetration into the myometrium) is essential for surgical planning. Also, resectoscopic myomectomy can be a safe and minimally invasive surgical approach for large submucous myomas, especially in nulliparous women that are attempting to become pregnant.

## Acknowledgments

The authors would like to acknowledge Prof Dr António Tomé (Director of Gynecology Department), Dr Serafim Guimarães (Director of Departamento da Mulher e da Medicina Reprodutiva do Centro Hospitalar do Porto), and to the Director of – Centro Materno Infantil do Norte – Dr António Marques.

## Reference List

- 1 - Fernandez, H.; Sefrioui, O.; Virelizier, C. et al. - *Hysteroscopic resection of submucosal fibroids in patients with infertility*. Hum Reprod, 2001, 16:1489-1492.
- 2 - Valle, R. F.; Baggish, M. S. - *Hysteroscopic myomectomy*. Hysteroscopy. Visual Perspectives of Uterine Anatomy, Physiology and Pathology Diagnostic and Operative Hysteroscopy, 3rd edn. Philadelphia: Lippincott Williams & Wilkins, a Wolters Kluwer business, 2007, 385-404.
- 3 - Ubaldi, F.; Tournaye, H.; Camus, M. et al. - *Fertility after hysteroscopic myomectomy*. Hum Reprod Update, 1995, 1:81-90.
- 4 - Sutton, C. - *Hysteroscopic surgery*. Best Pract Res Clin Obstet Gynaecol, 2006, 20:105-137.
- 5 - Salim, R.; Lee, C.; Davies, A. et al. - *A comparative study of three-dimensional saline infusion sonohysterography and diagnostic hysteroscopy for the classification of Submucous fibroids*. Hum Reprod, 2005, 20:253-57.

- 6 - Campo, S.; Campo, V.; Gambadauro, P. - *Short-term and long-term results of resectoscopic myomectomy with and without pretreatment with GnRH analogs in premenopausal women*. Acta Obstet Gynecol Scand, 2005, 84:756-760.
- 7 - Takeda, A.; Manabe, S.; Hosono, S. et al. - *Preoperative evaluation of submucosal fibroid by virtual hysteroscopy*. J Am Assoc Gynecol Laparosc, 2004, 11:404-409.
- 8 - Somigliana, E.; Vercellini, P.; Daguati, R. et al. - *Fibroids and female reproduction: a critical analysis of the evidence*. Hum Reprod Update, 2007, 13:465-476.
- 9 - Lasmar, R. B.; Xinmei, Z.; Indman, P. D. et al. - *Feasibility of a new system of classification of submucous myomas: a multicenter study*. Fertil Steril, 2011, 95(6):2073-7.
- 10 - Murakami, T.; Tamura, M.; Ozawa, Y. et al. - *Safe techniques in surgery for hysteroscopic myomectomy*. J Obstet Gynaecol Res, 2005, 31:216-223.
- 11 - van Dongen, H.; Emanuel, M. H.; Wolterbeek, R. et al. - *Hysteroscopic morcellator for removal of intrauterine polyps and myomas: a randomized controlled pilot study among residents in training*. J Minim Invasive Gynecol, 2008, 15:466.
- 12 - Emanuel, M. H.; Wamsteker, K. - *The Intra Uterine Morcellator: a new hysteroscopic operating technique to remove intrauterine polyps and myomas*. J Minim Invasive Gynecol, 2005, 12:62.

---

13 - Sardo, A. S.; Mazzon, I.; Bramante, S. et al. - *Hysteroscopic myomectomy: a comprehensive review of surgical techniques*. Hum Reprod Update, 2007,14:101-119.

14 - Phillips, D. R.; Nathanson, H. G.; Meltzer, S. M. et al. - *Transcervical electrosurgical resection of submucous leiomyomas for chronic menorrhagia*. J Am Assoc Gynecol Laparosc, 1995, 2:147-153.

15 - Donnez, J.; Polet, R.; Smets, M. et al. - *Hysteroscopic myomectomy*. Curr Opin Obstet Gynecol, 1995, 7:311-16.

16 - Okohue, J. - *Hysteroscopic Myomectomy: Is There a Place for Pretreatment with GnRH Agonist?* World Journal of Laparoscopic Surgery, 2009, 2(2):53-56.