ACTA RADIOLÓGICA PORTUGUESA
May-August 2018 | Vol 30 nº 2 | 39-41

Radiological Case Report / Caso Clínico

Sonographic Characteristics of Apocrine Hidradenoma of the Skin: A Case Report

Características Ecográficas do Hidradenoma Apócrino Cutâneo: Descrição de um Caso Clínico

A. Serafim[1,2], A. Ferreira[3], R. Company[1,2], A. Carneiro[4], P. Agostini[4], T. Figueiredo[2,5]

*1 University of Algarve. CIMA. Faculty of Sciences & Technology. Faro, Portugal
2 University of Algarve. Department of Biomedical Sciences and Medicine. Faculty of Sciences & Technology. Faro, Portugal
3 Hospital de Loulé, Loulé, Portugal
4 Centro Hospitalar Universitário do Algarve - CHUA, Portimão, Portugal
5 Hospital Particular do Algarve, Faro, Portugal

Address

Maria Angela Pereira Serafim
University of Algarve, CIMA
Faculty of Sciences & Technology
Campus de Gambelas
8005-139 Faro, Portugal
email: aserafim@ualg.pt

Abstract

Nodular hidradenoma is a benign sweat gland-derived rare tumour. Histologically, these tumours can be classified into eccrine and apocrine subtypes. In most cases, the diagnosis is made after surgical excision and hidradenomas generally follow a benign course, although malignant transformation is also documented. We present here a new case of apocrine hidradenoma with lymph vessel permeation.
We describe the ultrasound findings of clear cell hidradenoma of the arm in an 82 year old man. The lesion involved the dermis and hypodermis and presented a well-defined oval structure with solid-cystic appearance that showed a hypoechoic rim and an inner mixed structure with hypoechoic solid nodule with marked vascularisation and anechoic lacunar fluid-filled cyst.
In comparison with other common cutaneous lesions, apocrine nodular hidradenomas present sonographic characteristics which may support their earlier and more precise sonographic diagnosis and also avoid clinical and dermatoscopic misdiagnosis.

Keywords

Nodular hidradenoma; Clear cell hidradenoma; Benign tumour; Skin ultrasound.

Resumo

O hidradenoma nodular é um raro tumor benigno derivado de glândulas sudoríparas. Histologicamente, estes tumores podem ser classificados em dois subtipos: écrinos e apócrinos. Na maioria dos casos, o diagnóstico é feito após a excisão cirúrgica e embora sigam geralmente um curso benigno, a sua transformação maligna foi já documentada. Apresentamos um caso de hidradenoma apócrino com envolvimento dos vasos linfáticos. Descrevemos os achados ecográficos do hidradenoma de células claras do braço num homem de 82 anos. A lesão envolveu a derme e a hipoderme e apresentou-se como uma estrutura ovóide bem definida com aparência sólido-quística com bordos hipoecoicos e uma estrutura interna contendo um nódulo sólido hipoecoico com vascularização marcada e uma estrutura quística com conteúdo líquido lacunar anecoico. Em comparação com outras lesões cutâneas comuns, os hidradenomas nodulares apócrinos apresentam características ecográficas típicas, o que pode suportar o diagnóstico ecográfico antecipado e mais preciso, evitando erros diagnósticos clínicos e dermatoscópicos.

Palavras-chave

Hidradenoma nodular; Hidradenoma de células claras; Tumor benigno; Ultrassonografia da pele.

Introduction

Nodular hidradenoma, also called acrospiroma, is a benign rare skin tumour derived from sweat glands.[1] Histologically, these tumours can show eccrine or apocrine differentiation. Due to the complex and variable histology there has been some controversy on their categorisation.[2] Clinically, lesions usually manifest as solitary, flesh coloured or red to blue, solid or cystic nodules; they occur on the head, neck or limbs, but any location may be affected;[1,3] and appear more commonly in middle-aged adults and older patients, with a slight predominance in females (2:1 female:male ratio).[4]
The use of sonography in hidradenoma case reports has shown solid papillary lesions protruding from the wall, or well-defined hypoechoic solid tumours with hypervascularity.[1,3,5,6,7,8] These tumours rarely show malignant transformation[9] and extremely rare cases of benign hidradenoma with lymphatic invasion have been reported.[10] We present here a case of apocrine hidradenoma with lymph vessel permeation.

Case Report

An 82-year-old man presented with a solitary nodule on the arm, with one year of evolution. Physical examination showed a bleeding ulcerated tumour with 4 cm of diameter. There was no associated lymphadenopathy. Trauma history was unremarkable. The patient had a personal medical history of diabetes, hypertension and benign prostatic hypertrophy. He was taking metformin, ramipril, and tamsulosin hydrochloride for each condition, respectively.
The ultrasound assessment was performed with a linear 14-MHz probe (Siemens Acuson Antares). The lesion involved the dermis and hypodermis and presented as a well-defined oval structure with solid-cystic appearance that showed a hypoechoic rim and an inner mixed structure with hypoechoic solid nodule with 20 mm diameter with marked vascularisation and anechoic lacunar fluid-filled cystic area measuring 30x22x20 mm with signs of bleeding (Fig. 1 and Fig. 2). It showed smoothly lobulated borders and moving

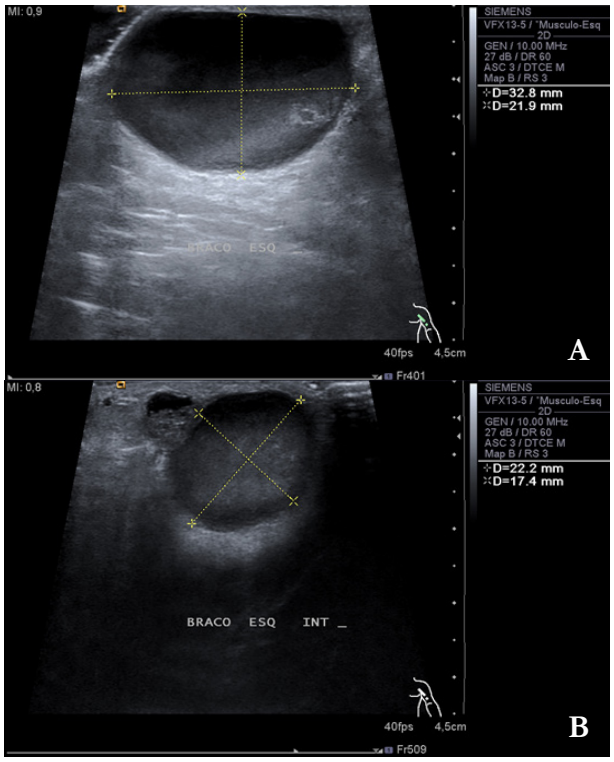

Figure 1 – Ultrasound image of the skin lesion showing A) a well defined cystic mass; B) a mural nodule in the periphery of the lesion.

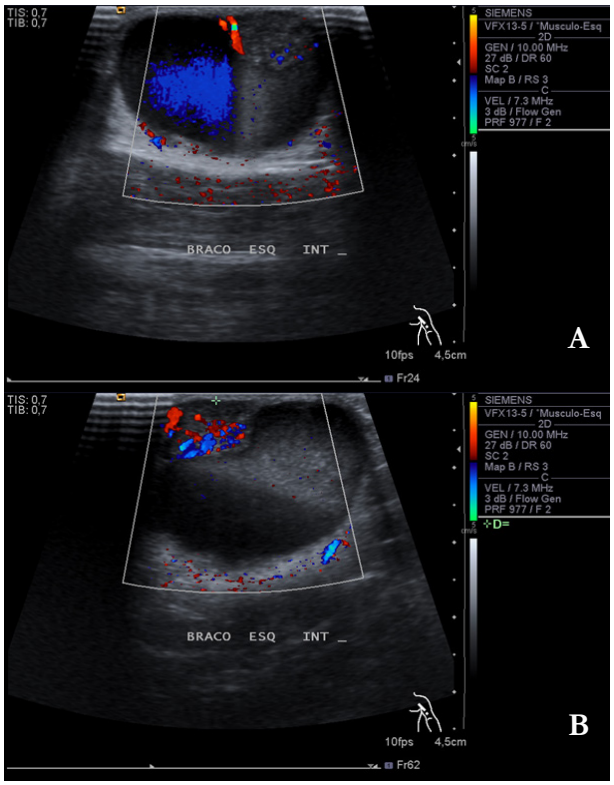

Figure 2 – Power Doppler study revealed increased vascularity in the solid portion of mass.

echoes that resemble the falling of snow. Wortsman et al. (2017)[3] named it "snow falling" sign. There was no sign of fascicular infiltration in the adjacent subcutaneous tissues, nor any sign of axillary adenomegaly. Vascularity was detected within the hypoechoic inner solid component.

The patient underwent surgical resection of the nodule (Fig. 3), with no complications and was discharged from

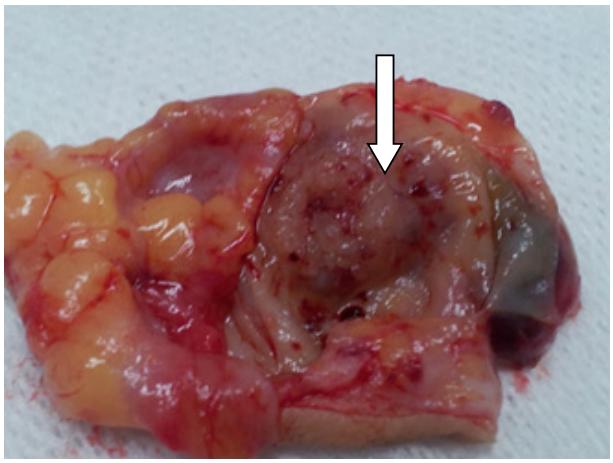

Figure 3 – Photograph of the specimen immediately after excision. The periphery of the cystic component is seen and the mural mass is highlighted. (arrow)

the Hospital on the same day. The microscopic sections showed a dermal and subcutaneous, fairly well-defined lobular tumour with extensive areas of cystic changes (Fig. 4-A). The cystic spaces were lined by cells that had decapitation secretion suggesting an apocrine line of differentiation. Most of the tumour consisted of sheets of cells that had pale pink cytoplasm or clear cell change (Fig. 4-B). The latter tended to be quite prominent. Within the tumour, there were areas of sclerosis, but no mass necrosis. Cytological atypia was not a feature and mitotic figures were very rare. Mild to moderate mononuclear inflammatory cell infiltrate composed of lymphocytes and plasma cells could be seen at the background along with hemosiderin deposition. A dilated vascular channel containing abundant red blood cells displayed a nest of bland epithelial cells derived from the tumour within the lumen (Fig. 4-C). The immunohistochemical stain showed strong positivity of the tumoral cells to AE1/AE3 cytokeratins, focal stain for EMA and it was negative to S100, HMB-45, actin and desmin. At a follow-up consultation, 18-months after surgery, clinical and radiological postoperative work-up showed no further evidence of disease.

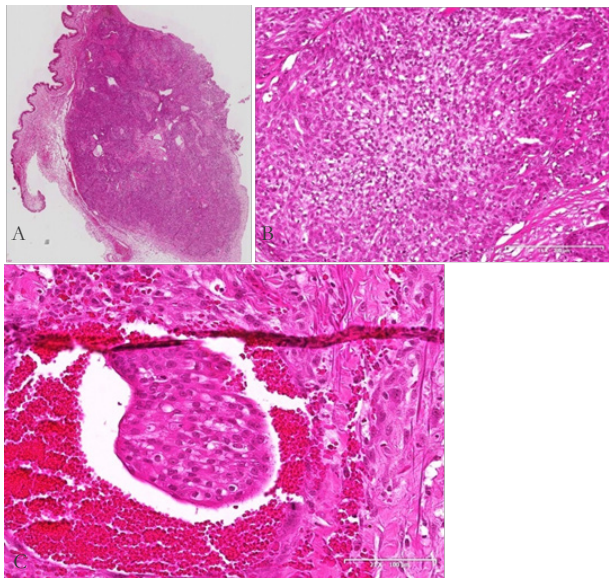

Figure 4 – Apocrine hidradenoma: (A) Dermal and subcutaneous, fairly well-defined lobular tumour (B); Clear cells predominated on the solid component (Hematoxylin-eosin, x200); (C) Angiolymphatic permeation in the dermis (Hematoxylin-eosin, x200).

Discussion

Hidradenoma is a benign adnexal skin neoplasm. Traditionally most investigators have considered these neoplasms to show eccrine derivation. Recently, a subdivision of hidradenoma into 2 groups has been suggested with those of eccrine differentiation (poroid hidradenomas) and those exhibiting apocrine differentiation (clear cell hidradenomas).[2] The present case showed apocrine differentiation with clear cell change and was classified as clear cell hidradenoma. The great majority of hidradenomas have a benign behaviour but rare publications seem to prove that morphologically benign hidradenoma can be associated with recurrences and malignant transformation, when hidradenocarcinoma is contiguous to a hidradenoma. In the vast majority of cases, the diagnosis is made after surgical excision.

The present tumour was classified histologically as benign, according to the classical criteria of benignity, atypical or malignant features as explained by Nazarian et al. (2009).[11] The present case seems to suggest that the involvement of the angiolymphatic system by a morphologically benign hidradenoma does not prove its malignant nature. Similar findings have already been reported by Stefanato et al. (2012),[10] where authors suggested that the term "benign metastasis" can be explained by a mechanic squeezing of neoplastic cells into the lymph vessels after neoplastic overgrowth and/or trauma. In light of these results and in the absence of better techniques to classify clear cell nodular hidradenoma, at this moment, as benign or "tumour of uncertain biological malignant potential" with the possibility of recurrence and/or malignant transformation, we argue that benign hidradenoma should be completely excised and a long clinical follow-up should be performed.

On ultrasound, the most commonly reported appearance is a well defined predominantly cystic mass with a solid component or a mural nodule[3] showing vascularity which is similar to the present report. The sonographic pattern of apocrine nodular hidradenoma differs from the sonographic features of other dermatologic lesions that have been reported to be clinically confused with hidradenoma. The differential diagnosis is wide and includes some variants of dermatofibromas, angiomatous tumours, ganglion cysts, malignant tumours such as basal cell carcinomas, squamous cell carcinomas, and melanomas, among others.[12] The "snow falling" and "fluid-fluid level" sonographic signs probably reflect intra-cystic bleeding and have recently been reported in nodular hidradenomas. To our knowledge, they have not been described in other dermatologic conditions.

In conclusion, apocrine nodular hidradenomas present different sonographic characteristics in comparation with other common cutaneous lesions, which may support their earlier and more precise sonographic diagnosis and also avoid clinical and dermatoscopic misdiagnosis.

Received / Recebido 18/01/2018
Acceptance / Aceite 27/03/2018

Ethical disclosures / Divulgações Éticas

Conflicts of interest: The authors have no conflicts of interest to declare.
Conflitos de interesse: Os autores declaram não possuir conflitos de interesse.
Financing Support: This work has not received any contribution, grant or scholarship.
Suporte financeiro: O presente trabalho não foi suportado por nenhum subsídio ou bolsa.
Confidentiality of data: The authors declare that they have followed the protocols of their work center on the publication of data from patients.
Confidencialidade dos dados: Os autores declaram ter seguido os protocolos do seu centro de trabalho acerca da publicação dos dados de doentes.
Protection of human and animal subjects: The authors declare that the procedures followed were in accordance with the regulations of the relevant clinical research ethics committee and with those of the Code of Ethics of the World Medical Association (Declaration of Helsinki).
Protecção de pessoas e animais: Os autores declaram que os procedimentos seguidos estavam de acordo com os regulamentos estabelecidos pelos responsáveis da Comissão de Investigação Clínica e Ética e de acordo com a Declaração de Helsínquia da Associação Médica Mundial.

References

1. Mullaney PJ, Becker E, Graham B, Ghazarian D, Riddell RH, Salonen DC. Benign hidradenoma: magnetic resonance and ultrasound features of two cases. Skeletal Radiol. 2007;36:1185-90.
2. Nandeesh BN, Rajalakshmi T. A study of histopathologic spectrum of nodular hidradenoma. Am J Dermatopathol. 2012;34:461-70.
3. Wortsman X, Reyes C, Ferreira-Wortsman C, Uribe A, Misad C, Gonzalez S. Sonographic characteristics of apocrine nodular hidradenoma of the skin. J Ultrasound Med. 2018;37:793-801.
4. Kasbekar PU, Jadhav SP. Case study of a rare case of nodular hidradenoma of the finger. International Journal of Scientific and Research Publications. 2013;3:1-4.
5. Obaidat NA, Alsaad KO, Ghazarian D. Skin adnexal neoplasms-part 2: an approach to tumours of cutaneous sweat glands. J Clin Pathol. 2007;60:145-59.
6. Takasaka M, Saeki H, Ito K, Matsuo K, Ishiji T, Nakagawa H. Skin ultrasound examination proves useful in diagnosing two cases of solid cystic hidradenoma. Int J Dermatol. 2014;53:e146-7.
7. Horie K, Ito K. Ultrasonographic diagnosis of nodular hidradenoma. J Dermatol. 2016;43:449-50.
8. Lee HH, Park SH, Choi HY, Park HK. Eccrine spiradenoma arising in the breast misdiagnosed as an epidermal inclusion cyst. Korean J Radiol. 2011;12:256-60.
9. Demirci GT, Atis G, Altunay IK, Sakiz D. A giant benign clear cell hidradenoma on the anterior trunk. Dermatol Reports. 2011;3:e45.
10. Stefanato CM, Ferrara G et al. Hidradenoma involving the lymphatic system. Am J Surg Pathol. 2012;36:1835-40.
11. Nazarian RM, Kapur P, Rakheja D, et al. Atypical and malignant hidradenomas: a histological and immunohistochemical study. Mod Pathol. 2009;22:600-10.
12. Serrano P, Lallas A, Del Pozo LJ, Karaarslan I, Medina C, Thomas L, Landi C, Argenziano G, Zaballos P Dermoscopy of nodular hidradenoma, a great masquerader: a morphological study of 28 cases. Dermatology. 2016;232:78-82.