

## ARP Case Report n° 14: What is your diagnosis?

*Caso Clínico ARP n°14: Qual o seu diagnóstico?*

**Luísa Costa Andrade, Carlos Bilreiro**

Department of Radiology, Centro Hospitalar Universitário do Algarve, Faro, Portugal

### Presentation of the Case

A 73-year-old woman presented with complaints of vague abdominal pain since 3 months.

Routine laboratory investigations were unremarkable, except for slight anemia. Serum alfa fetoprotein (AFP) level, serum lactate dehydrogenase (LDH) level and serum carcinoembryonic antigen (CEA) levels were within normal

limits. Liver function tests were altered, showing elevated alanine transferase level, alkaline transferase level and alkaline phosphatase level.

The ultrasound was inconclusive due to bowel gas interposition.

A computed tomography (CT) scan of the abdomen and a MRI were performed.

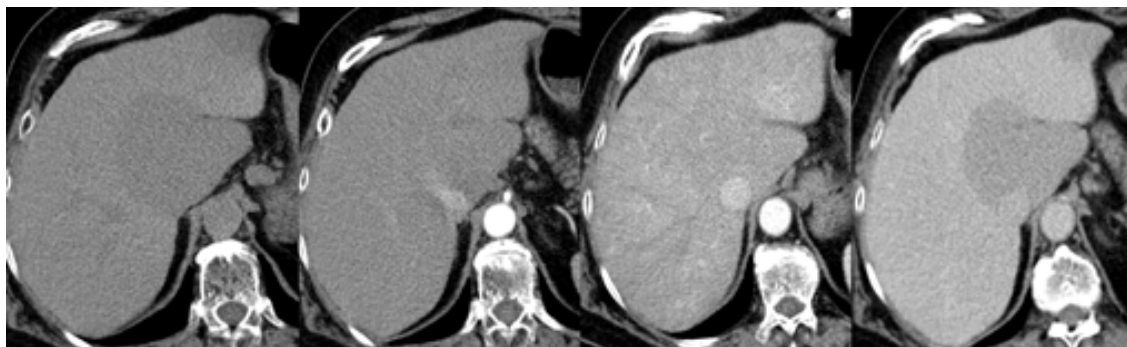

Figure 1 – CT findings

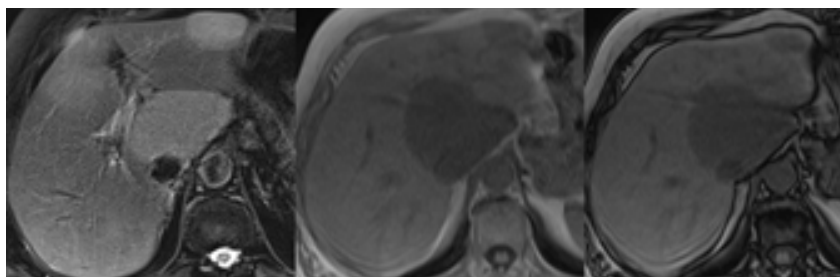


Figure 2 – MR: T2 FS and T1 In-Out

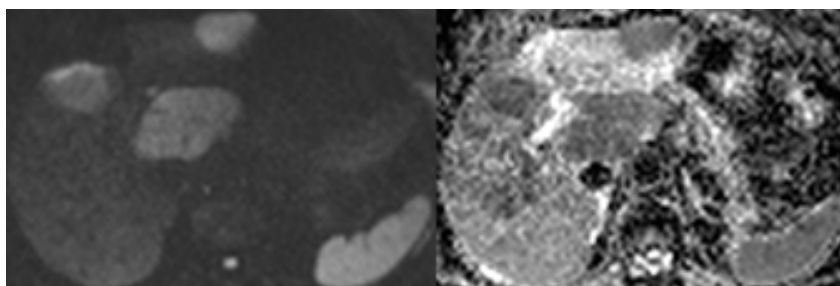
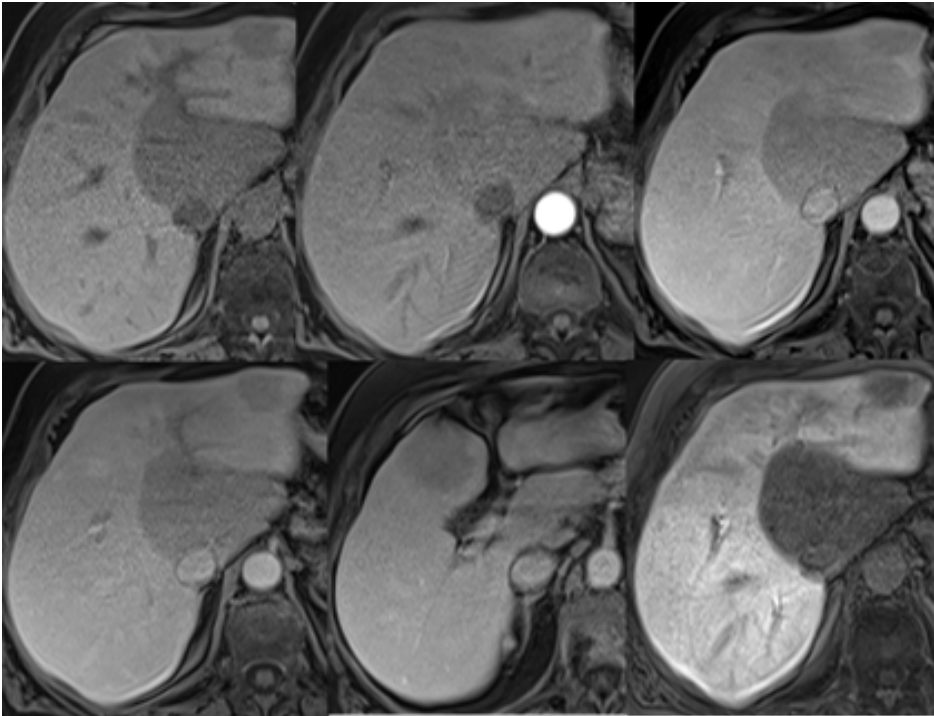


Figure 3 – MR: DWI (B=800) and ADC map

Send your answer containing the diagnosis (s) to the email address [actarp.on@gmail.com](mailto:actarp.on@gmail.com).  
The names of the authors of the correct answers will be published in the next issue of the ARP in the case solution.



**Figure 4** – MR: Enhanced study with Gd-EOB-DTPA