

ARP Case Report n° 15: What is your diagnosis?

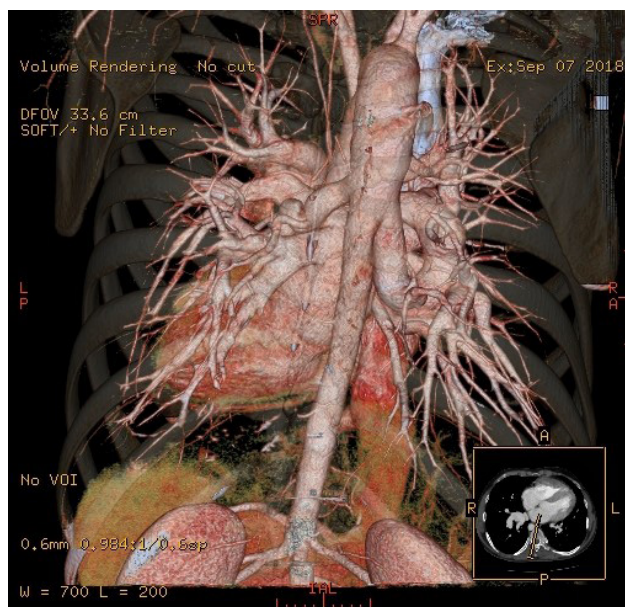
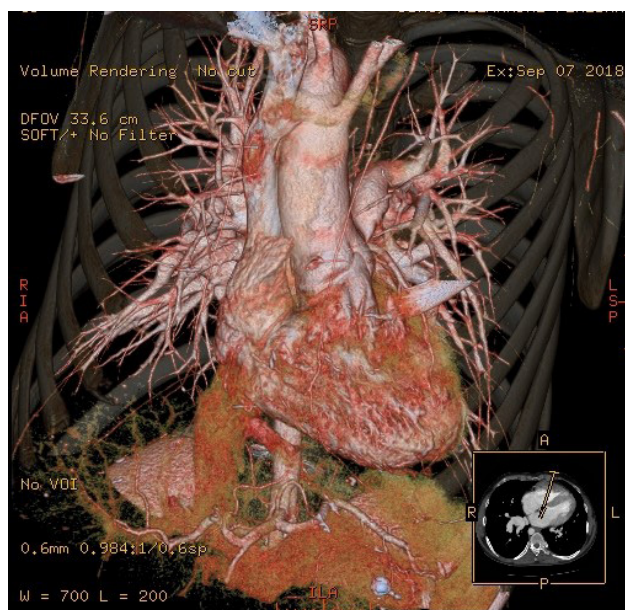
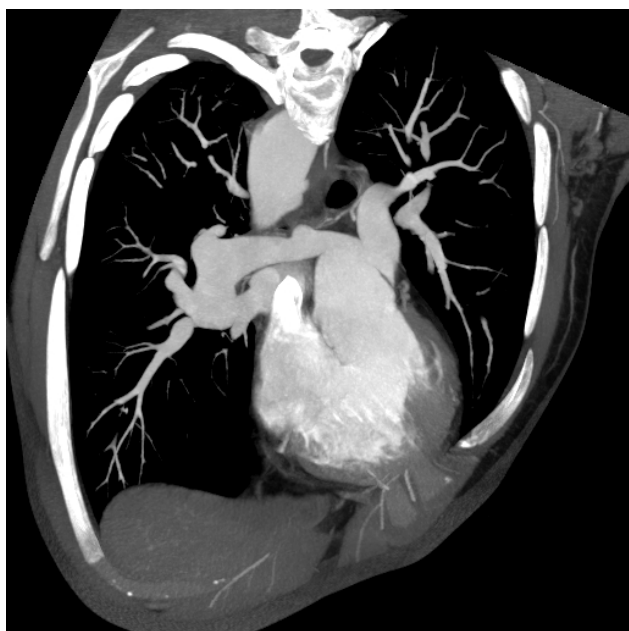
Caso Clínico ARP n° 15: Qual o seu diagnóstico?

Nuno Pereira da Silva, Paulo Donato

Imaging Department, University Centre Hospitals of Coimbra. Faculty of Medicine, University of Coimbra, Portugal

Presentation of the Case

A 21-year-old male is admitted to our hospital's emergency ward with cyanosis. Laboratory routines revealed severe hypoxia. The patient had an history of congenital heart defect. Computer tomography angiography with ECG gating was performed.



Send your answer containing the diagnosis (s) to the email address actarp.on@gmail.com.
The names of the authors of the correct answers will be published in the next issue of the ARP in the case solution.