

ARP Case Report n° 16: What is your diagnosis?

Caso Clínico ARP n° 16: Qual o seu diagnóstico?

Isabel Candelária, Rui Alves Costa

Department of Radiology, Unidade Local de Saúde de Castelo Branco, Castelo Branco, Portugal

Presentation of the Case

69 year-old female referred to our institution for abdominal discomfort, epigastric pain and weight loss (10Kg in 6 months).

Abdominal e thoracic CT was performed and later on additional abdominal MR.

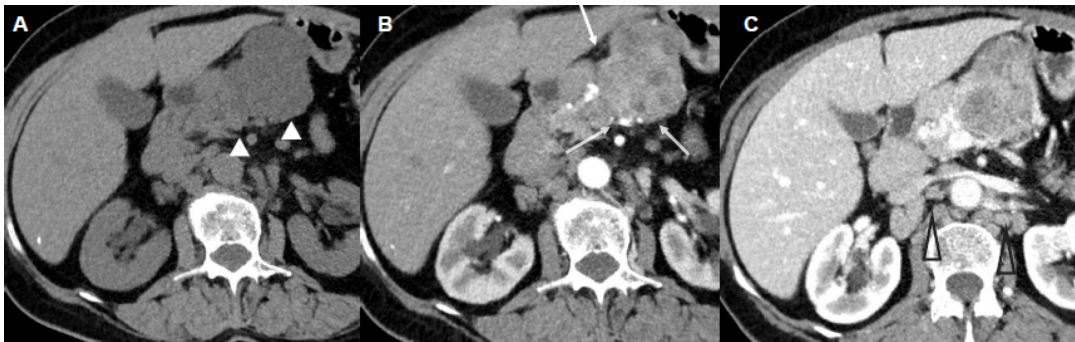


Figure 1

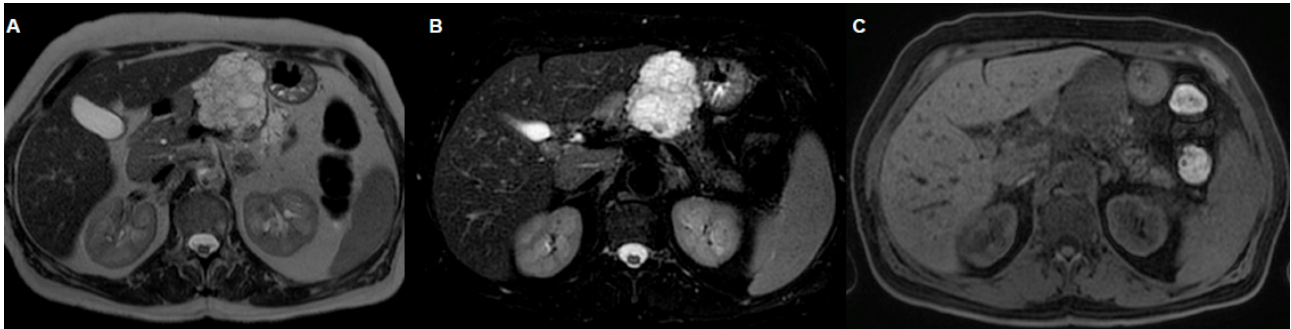


Figure 2

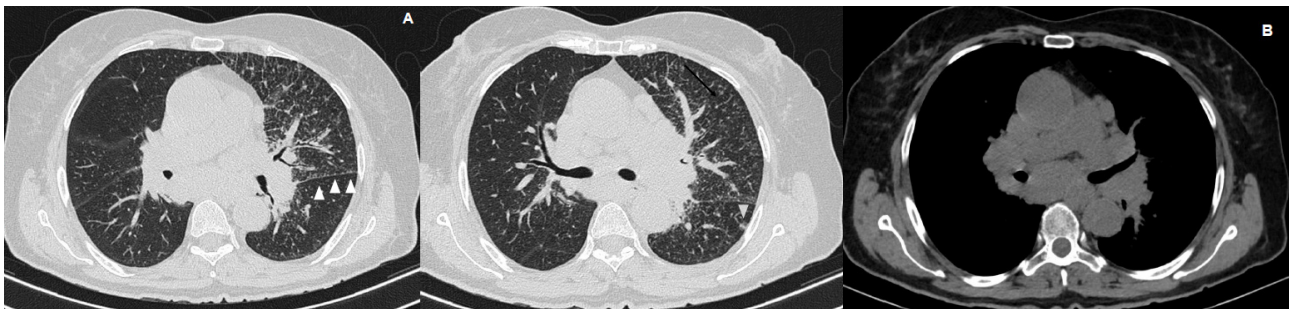


Figure 3

Send your answer containing the diagnosis (s) to the email address actarp.on@gmail.com.
The names of the authors of the correct answers will be published in the next issue of the ARP in the case solution.