

## Images of Interest / Imagens de Interesse

**Silicone Radial Head Prosthesis Fracture***Fratura da Prótese de Silicone da Cabeça do Rádio*Andrey Cabral Paes<sup>1</sup>, Ralf Mallmann<sup>1</sup>, Márcio Luís Duarte<sup>1,2</sup><sup>1</sup>WEBIMAGEM Telerradiologia, São Paulo, São Paulo, Brazil.<sup>2</sup>WEBIMAGEM Telerradiologia, São Paulo, São Paulo, Brasil. Master Degree in Evidence-Based Health, UNIFESP, São Paulo, São Paulo, Brasil.**Address**Márcio Luís Duarte  
WEBIMAGEM  
Avenida Marquês de São Vicente 446  
São Paulo, Brasil.  
e-mail: marcioluisduarte@gmail.com**Received:** 12/11/2019**Accepted:** 07/12/2020**Published:** 30/04/2021© Author(s) (or their employer(s)) and ARP  
2021. Re-use permitted under CC BY-NC. No  
commercial re-use.**Abstract**

The radial head is an important secondary stabilizer of the elbow and can bear up to 60% of the load transmitted from the forearm. Replacement of the radial head is advised in cases in which the extent of ligamentous injury calls for this secondary stabilizing function and it is not possible to reconstruct the radial head. The inability of a silicone radial head to resist compressive loads or valgus stress is evidence that the implant does not restore normal radiocapitellar load transmission, which is believed to be imperative for normal elbow function. We report a complication of the silicone prosthesis of the radial head diagnosed by computed tomography.

**Keywords**

Radius; Elbow joint; Replacement arthroplasty; X-Ray computed tomography; Radius fractures.

**Resumo**

A cabeça radial é um importante estabilizador secundário do cotovelo e pode suportar até 60% da carga transmitida pelo antebraço. A substituição da cabeça radial é recomendada nos casos em que a extensão da lesão ligamentar exige essa função estabilizadora secundária e não é possível reconstruir a cabeça radial. A incapacidade de uma cabeça radial de silicone de resistir às cargas compressivas ou ao estresse em valgo é evidência de que o implante não restaura a transmissão normal da carga radiocapitelar, que se acredita ser um imperativo para a função normal do cotovelo. Relatamos uma complicação da prótese de silicone da cabeça do rádio diagnosticada pela tomografia computadorizada.

**Palavras-chave**

Rádio (anatomia); Articulação do cotovelo; Artroplastia de substituição; Tomografia computadorizada por raios X; Fraturas do rádio.

**Case Presentation**

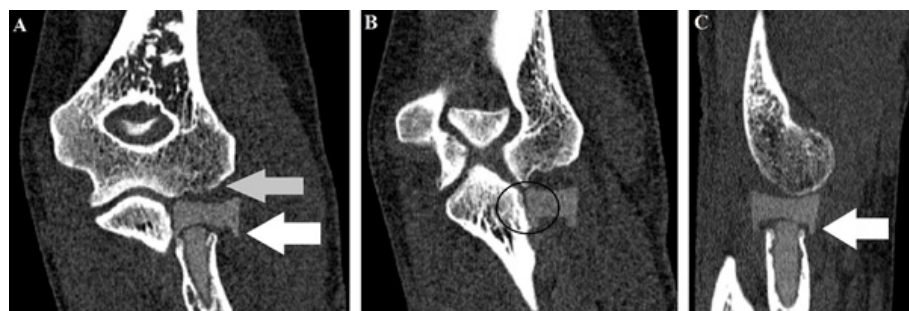
A 54-year-old man with left elbow pain 2 months. Denies recent trauma and diseases, referring to being a handyman. He reports fracture of the radial head performing replacement with silicone prosthesis nine years ago, without complications since then. Physical examination shows elbow edema with reduced strength in the affected upper limb, without signals of numbness. No limitation of movement.

The computed tomography scan demonstrates a fracture of the neck of the silicone prosthesis of the radius head, with slight lateral displacement of the prosthesis head, irregularity of the capitellum, and of the radial notch (Figure 1). The patient was referred to the orthopedics department for scheduling surgery.

**Discussion**

The radial head is an important secondary stabilizer of the elbow and can bear up to 60% of the load transmitted from the forearm.<sup>1,2</sup> Replacement of the radial head is advised in cases in which the extent of ligamentous injury calls for this secondary stabilizing function and it is not possible to reconstruct the radial head.<sup>1</sup>

The goals of treating radial head fractures are to restore stability, preserve motion, and maintain the length of the radius.<sup>2</sup> If preservation of the head is not possible, prosthetic replacement has been advocated to preserve the radiocapitellar articulation.<sup>2</sup> Many radial head implant materials are possible, including metal, pyrolytic carbon (pyrocarbon), and silicone.<sup>2,3</sup> Silicone was introduced by Swanson in 1969.<sup>3</sup>



**Figure 1** – CT Scan of the left elbow in coronal section in **A** and **B**, and in sagittal section in **C**, demonstrating fracture of the neck of the silicone prosthesis with slight lateral displacement (white arrow), irregularity of the capitellum (grey arrow) and of the radial notch (black circle).

---

A head and neck segment that is made of silicone is embedded after radial head resection.<sup>3</sup> Silicone hemiarthroplasty is barely executed because of a huge percentage of loosening, fracture, and silicone synovitis.<sup>3</sup> Nevertheless, radiologists, sometimes, encounter patients who received this sort of implant during the 1970s and 1980s.<sup>3</sup>

The inability of a silicone radial head to resist compressive loads or valgus stress is evidence that the implant does not restore normal radiocapitellar load transmission, which is believed to be imperative for normal elbow function.<sup>4</sup> At radiography, it is essential the evaluation for fracture of the silicone and silicone synovitis, which are seen as periprosthetic lucencies and soft-tissue swelling.<sup>3</sup> The fractures of silicone radial head implant arthroplasty include prosthetic fracture at the head, stem-head junction, or stem.<sup>4</sup>

After implant failure, bone resorption has been reported around silicone finger-joint implants and wear particles have been implicated as causing synovitis and subchondral bone cysts.<sup>5</sup> An irregular capitellum may cause fraying of the implant surface and release of particulate silicone debris because of shear and abrasive wear, evidenced clinically by the high incidence of squeaking sounds with forearm rotation.<sup>4</sup> Silicone prosthesis turned out to be biologically and biomechanically insufficient.<sup>5</sup>

## Conclusion

In summary, the fracture of a radial head prosthesis is a rare complication but, the silicone prosthesis has a higher rate of complications like the fracture reported when compared with other materials.

---

### Ethical disclosures / Divulgações Éticas

*Conflicts of interest:* The authors have no conflicts of interest to declare.

*Conflitos de interesse:* Os autores declaram não possuir conflitos de interesse.

*Financing Support:* This work has not received any contribution, grant or scholarship.

*Suporte financeiro:* O presente trabalho não foi suportado por nenhum subsídio ou bolsa.

*Confidentiality of data:* The authors declare that they have followed the protocols of their work center on the publication of data from patients.

*Confidencialidade dos dados:* Os autores declaram ter seguido os protocolos do seu centro de trabalho acerca da publicação dos dados de doentes.

*Protection of human and animal subjects:* The authors declare that the procedures followed were in accordance with the regulations of the relevant clinical research ethics committee and with those of the Code of Ethics of the World Medical Association (Declaration of Helsinki).

*Proteção de pessoas e animais:* Os autores declaram que os procedimentos seguidos estavam de acordo com os regulamentos estabelecidos pelos responsáveis da Comissão de Investigação Clínica e Ética e de acordo com a Declaração de Helsínquia da Associação Médica Mundial.

### References

1. Heijink A, Kodde IF, Mulder PG, Veltman ES, Kaas L, van den Bekerom MP, Eygendaal D. Radial head arthroplasty: a systematic review. *JBJS Rev.* 2016;18;4.
2. Maghen Y, Leo AJ, Hsu JW, Hausman MR. Is a silastic radial head still a reasonable option? *Clinical Orthopaedics Related Research.* 2011;469:1061-70.
3. Petscavage JM, Ha AS, Chew FS. Radiologic review of total elbow, radial head, and capitellar resurfacing arthroplasty. *Radiographics.* 2012;32:129-49.
4. Trepman E, Ewald FC. Early failure of silicone radial head implants in the rheumatoid elbow: a complication of silicone radial head implant arthroplasty. *J Arthroplasty.* 1991;6:59-65.
5. Vanderwilde RS, Morrey BF, Melberg MW, Vinh TN. Inflammatory arthritis after failure of silicone rubber replacement of the radial head. *J Bone Joint Surg Br.* 1994;76:78-81.