

ARP Case Report n° 18: What is your diagnosis?

Caso Clínico ARP n° 18: Qual o seu diagnóstico?

David Campos Correia, Miguel Franco Gago, Tiago Saldanha, Carla Saraiva

Radiology Department, Centro Hospitalar de Lisboa Ocidental, Lisbon, Portugal

Case Presentation

72-year-old male, referred to our hospital due to 5-month history of dry cough, increasing abdominal discomfort and

feeling of abdominal fullness. Laboratory results revealed anaemia, mild leucocytosis and elevated C-reactive protein levels. Ultrasound was initially performed, followed by Computed Tomography.

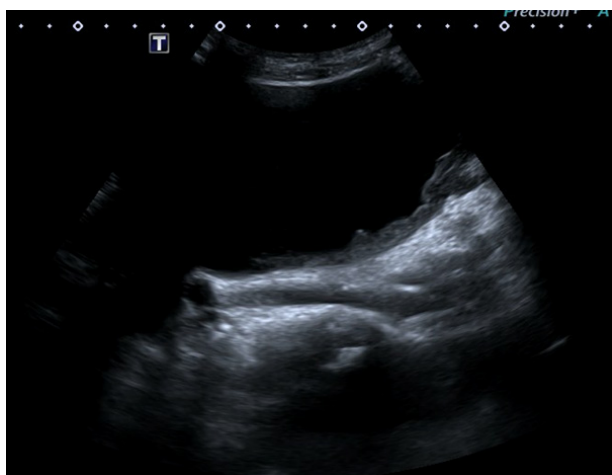

Figure 1

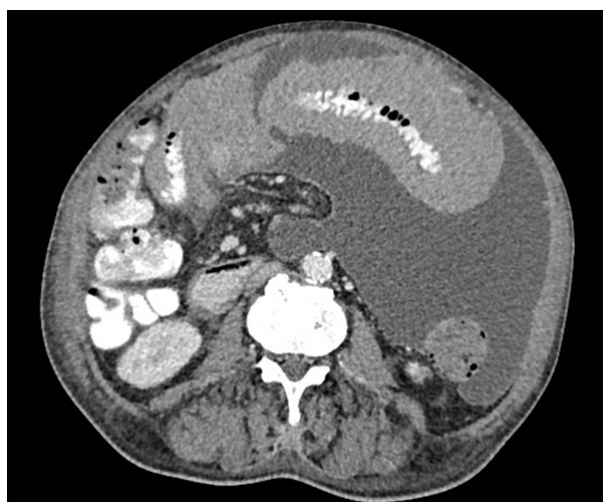


Figure 3

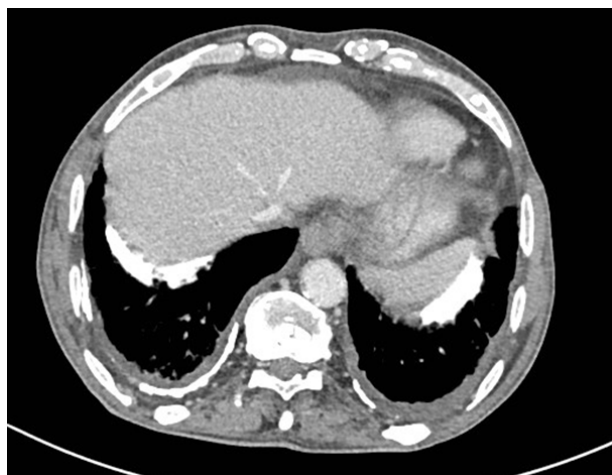

Figure 2

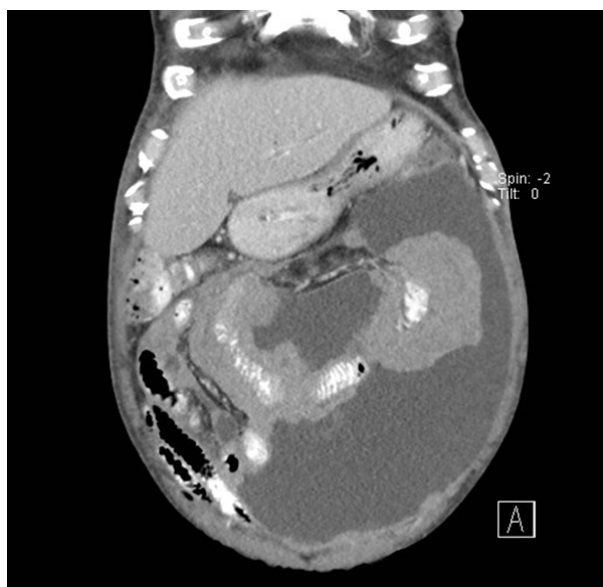

Figure 4

Send your answer containing the diagnosis (s) to the email address actarp.on@gmail.com.
The names of the authors of the correct answers will be published in the next issue of the ARP in the case solution.

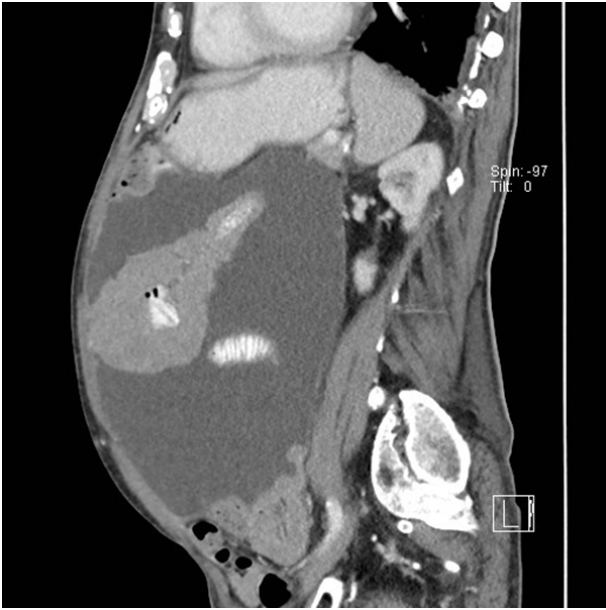

Figure 5