

Radiological Case Report / Caso Clínico

Disseminated Peritoneal Leiomyomatosis: A Rare Case Report in a Woman without a Prior History of Uterine Leiomyomas*Leiomiomatose Peritoneal Disseminada: Relato de um Caso Raro numa Mulher sem História Prévia de Leiomiomas Uterinos*Marta Daniela Lameiras Costa¹, Teresa Margarida Cunha²

¹Interna de Formação Específica em Radiologia (4º ano) - Serviço de Radiologia, Centro Hospitalar Universitário de Lisboa Central, Lisboa, Portugal

²Assistente Hospitalar Graduada de Radiologia - Serviço de Radiologia, Instituto Português de Oncologia de Lisboa Francisco Gentil, Lisboa, Portugal

Address

Marta Daniela Lameiras Costa
Centro Hospitalar Universitário de Lisboa Central
Hospital Curry Cabral, Serviço de Radiologia R. Beneficência 8, 1050-099 Lisboa, Portugal
e-mail: martacosta.med@gmail.com

Abstract

Disseminated peritoneal leiomyomatosis (DPL) is a rare disease characterized by multiple leiomyomas disseminated throughout the peritoneal cavity, occurring most commonly in women of childbearing age. Although typically benign, DPL may degenerate into malignancy. As the majority are asymptomatic, these tumors are usually incidentally found incidentally. Differential diagnosis includes peritoneal carcinomatosis peritoneal or abdominal disseminated malignancy; the clinical and radiological context can help differentiate these entities, but only histopathological examination achieves the final diagnosis.

The authors present a case of a woman with DPL found during infertility workup. She had undergone laparoscopic broad ligament myomectomy 5 years previously, but there was no prior history of uterine leiomyomas. A revision of the clinical, pathological and imaging features of this entity was also performed.

Keywords

Disseminated peritoneal leiomyomatosis; Leiomyoma; Case report.

Resumo

A Leiomiomatose Peritoneal Disseminada (LPD) é uma doença rara que se caracteriza pela ocorrência de múltiplos leiomiomas disseminados pela cavidade peritoneal, ocorrendo mais comumente em mulheres em idade fértil. Apesar de ser tipicamente benigna, a LPD pode sofrer transformação maligna. Dado que a maioria dos casos são assintomáticos, estes tumores são geralmente diagnosticados de forma incidental.

O diagnóstico diferencial inclui a carcinomatose peritoneal ou a neoplasia maligna intra-abdominal disseminada; embora o contexto clínico e radiológico possa apontar para uma das referidas entidades, o diagnóstico definitivo só pode ser obtido com exame anátomo-patológico.

Os autores apresentam o caso de uma mulher com LPD incidentalmente descoberta no contexto de investigação de infertilidade. A paciente tinha sido submetida a miomectomia laparoscópica do ligamento largo há cinco anos, mas não havia história prévia de leiomiomas uterinos.

Foi também realizada uma revisão das características clínicas, patológicas e radiológicas desta entidade.

Palavras-chave

Leiomiomatose peritoneal disseminada; Leiomioma; Caso clínico.

Introduction

Disseminated peritoneal leiomyomatosis (DPL), also known as leiomyomatosis peritonealis disseminata, is a rare disease characterized by multiple tumors derived from smooth muscles disseminated throughout the peritoneal cavity. It was first described in 1952 by Wilson and Peale¹ and until recently only around 200 cases have been reported in the English literature. However, as the majority are asymptomatic, this condition may be underdiagnosed, and it is usually found incidentally. Although typically benign, DPL may degenerate into malignancy.²

Differential diagnosis mainly includes peritoneal carcinomatosis or metastatic disease; the clinical and radiological features can help differentiate these entities, but only histopathological examination achieves the final diagnosis.^{3,4}

Case Presentation

A 30-year-old woman proceeded to our institution due to a tumor with left para-uterine location found during a transvaginal ultrasound scan, during infertility workup. She had undergone laparoscopic broad ligament myomectomy 5 years previously. A broad ligament leiomyoma was suspected. However, there was an elevated level of CA 125 (50 U/ml), which required the exclusion of an adnexal tumor by ultrasound.

A Computed Tomography (CT) was requested and revealed three intraperitoneal soft tissue density masses in the pelvic cavity: one near the left para-uterine margin, and the other two located superiorly, one on the right and the other more central (Fig. 1).

Magnetic Resonance Imaging (MRI) was performed for better characterization and showed tree well-defined masses with heterogeneous and intermediate signal intensity on T2 weighted images (T2WI) (Figs. 2a-e) and low signal

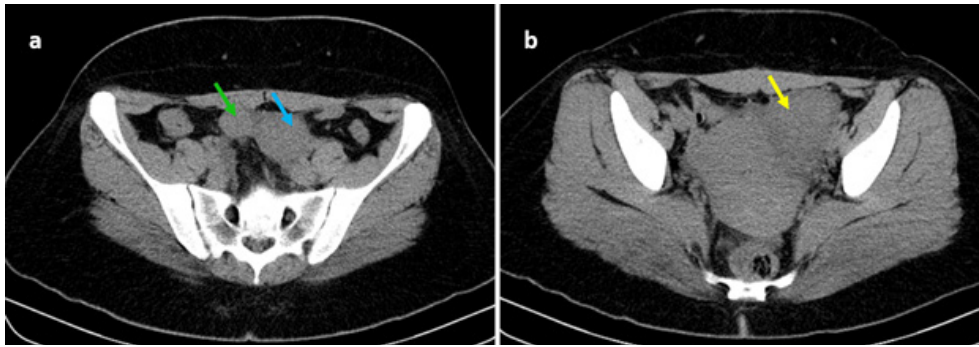


Fig. 1 – Axial computed tomography without intravenous contrast administration shows three peritoneal soft-tissue density tumors in the pelvic cavity: one near the left para-uterine margin (yellow arrow), and the other two located superiorly, one on the right (green arrow) and the other more central (blue arrow).

intensity on T1 weighted images (T1WI) (Figs. 2c-g). On T1W post-contrast image tumors presented strong and heterogeneous enhancement (Figs. 2h-j), particularly the one in the left para-uterine region, which was the biggest. They also showed restricted diffusion with high signal on DW images and low signal on ADC map (Fig. 3).

Three months later she underwent surgical resection. The histological diagnosis revealed three fasciculate and elastic tumors, well delimited, with no malignant features, compatible with DPL.

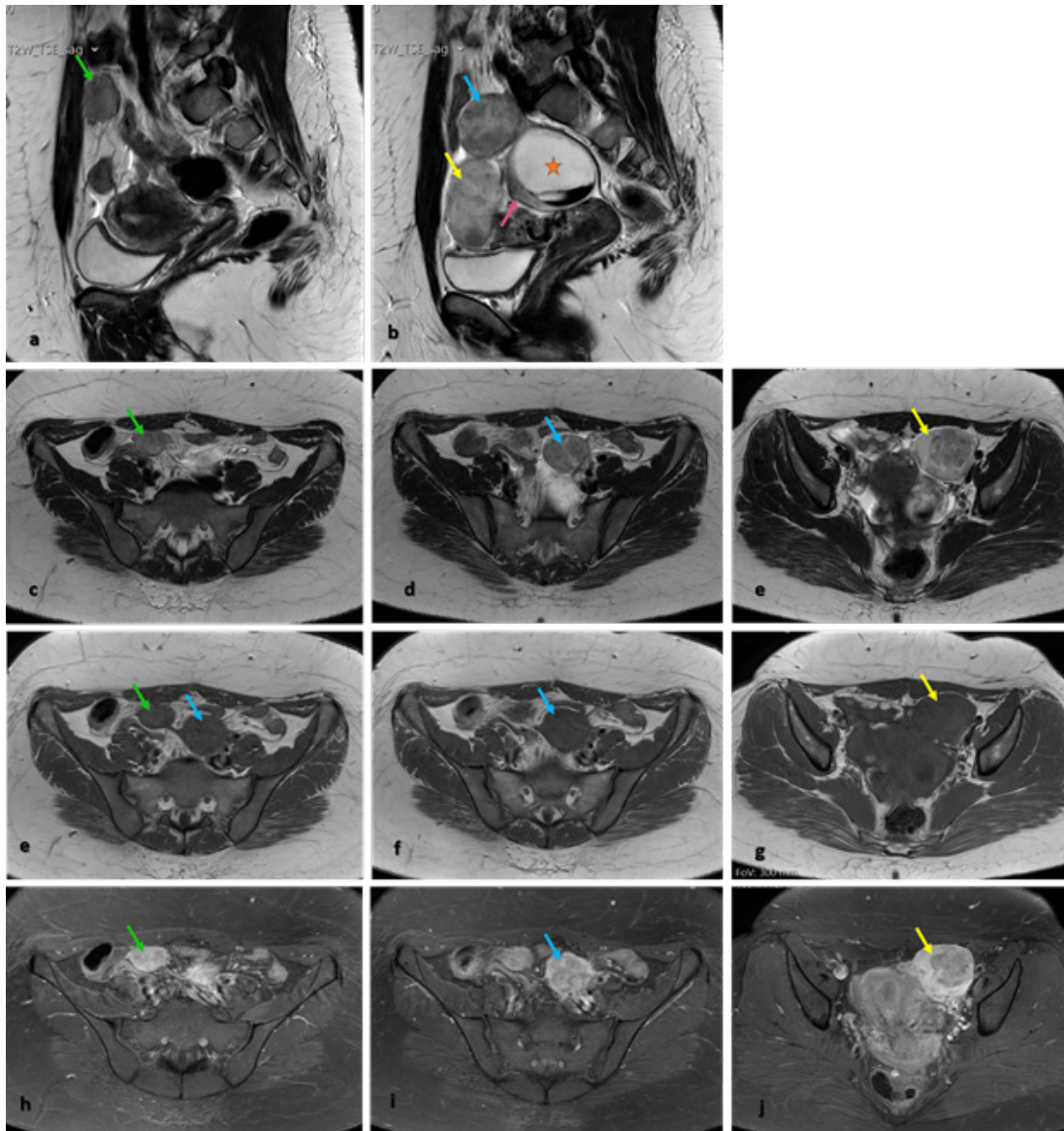


Fig. 2 – MRI shows three well-defined and heterogeneous tumors, with intermediate signal intensity on sagittal (1a, 1b) and axial (1c-1e) T2WI, and with low signal intensity on T1WI (e-g): one near the left para-uterine margin (yellow arrow), and the other two located superiorly, one on the right (green arrow) and the other more central (blue arrow). Tumors present strong but heterogeneous enhancement on T1W post-contrast image (h-j), particularly the one who was in the left para-uterine region (yellow arrow). There is still a large high signal intensity cystic mass (orange star) with a level formed by a hypointense blood clot in the lower portion; cyst arises from the right ovary (pink arrow) – “positive beak sign” – well seen on sagittal T2WI (1b).

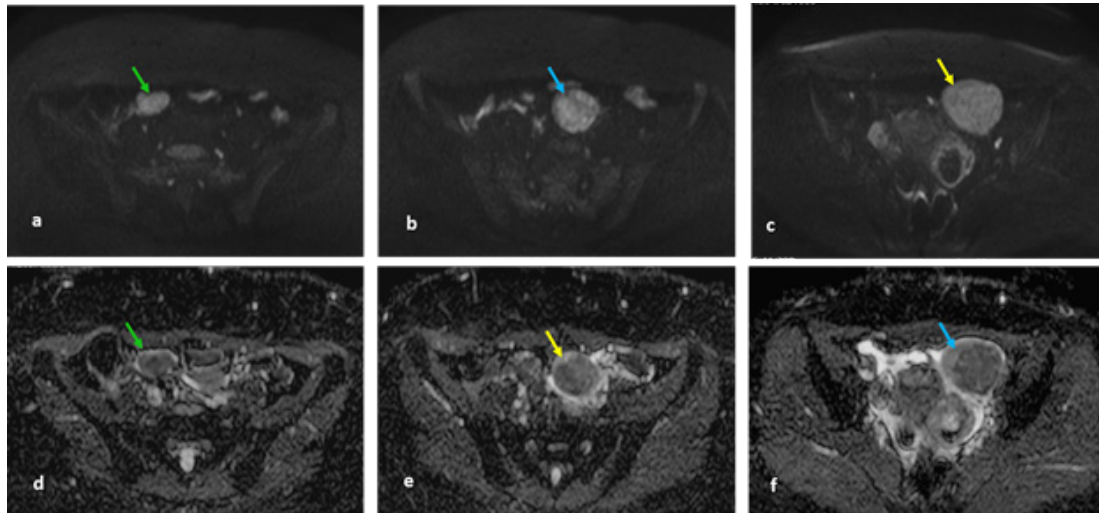


Fig. 3 – MRI shows three tumors with high signal intensity on axial diffusion-weighted imaging (b1000) (a-c) and low signal intensity on axial ADC map (d-f), corroborating the presence of restricted diffusion.

Discussion Conclusion

Disseminated peritoneal leiomyomatosis (DPL) is a rare disease characterized by multiple tumors derived from smooth muscles spread throughout the peritoneum.

There are several hypotheses about the etiology and pathophysiology of DPL. The two most consensual are hormonal and iatrogenic theories.

The hormonal theory suggests that DPL results from the metaplastic change of mesenchymal stem cells with exposure to high levels of endogenous or exogenous estrogens. This is convincing because, this entity occurs most commonly in women of childbearing age, during pregnancy, and after prolonged administration of oral contraceptive pills or hormone replacement therapy;⁵ however, there are also a few cases reported in postmenopausal women and in male patients.^{4,6,7}

As occurred in this case, DPL may present even years after laparoscopic myomectomy or hysterectomy with tumor morcellation.⁸ According to the iatrogenic theory, these surgical techniques increase the risk of intra-abdominal dispersion of residual tumor debris, leading to peritoneal dissemination.^{9,10}

There are reports of DPL without a history of uterine leiomyoma, suggesting that these tumors could originate from extrauterine spindle cell tumors.¹¹ Our patient also had a previous history of one broad ligament leiomyoma. As many cases are asymptomatic, these tumors are usually found incidentally. Some patients may present with pelvic pain or pelvic and abdominal compression symptoms. Tumors can involve the bladder or an intestinal segment and lead to intestinal obstruction.¹⁰

At CT, DPL presents itself as multiple solid subcentimeter nodules or as large soft tissue density masses in the peritoneal cavity, homogeneous or heterogeneous, with variable enhancement pattern like uterine leiomyomas.

Pelvic MRI is the most accurate modality for detection, location and characterization of DPL due to its excellent soft-tissue contrast resolution and multiplanar imaging capability; it allows evaluation of disease extension and its relationship with surrounding structures. On T1 and T2 weighted images, these tumors usually present low to intermediate signal intensity compared with the normal myometrium; however, they may undergo degeneration showing variable appearances. Following intravenous administration of gadolinium, on T1 weighted images, variable enhancement may be seen but usually DPL shows homogeneous and strong enhancement.

Differential diagnosis mainly includes peritoneal carcinosarcoma or metastatic disease; the clinical and radiological features can help to differentiate these entities, but only histological analysis can reveal the final diagnosis.^{3,4} The histopathological examination usually shows smooth-muscle cell proliferation with no atypia or necrosis. Malignant changes can be seen very rarely.^{2,12,13}

Concerning the treatment of DPL there are no clear guidelines.¹ It has been proposed that therapy should be individualized according to the patient's condition, considering age, comorbidities and severity of symptoms.¹⁴ A conservative approach including hormonal treatment with gonadotrophin releasing hormone agonists or stopping the contraceptive pills seem good alternatives for women with reproductive desire.¹⁵ For postmenopausal women or without reproductive desire, or even in cases of a high risk of malignant degeneration, surgical approach (usually with total abdominal hysterectomy, salpingo-oophorectomy, omentectomy and debulking) is probably the best option.⁵

Although typically benign in nature, DPL may degenerate into malignancy.² Therefore, regular follow-up is strongly recommended, especially for high-risk patients.¹¹

Received / Recebido 23/03/2020
Acceptance / Aceite 26/06/2020

Ethical disclosures / Divulgações Éticas

Conflicts of interest: The authors have no conflicts of interest to declare.

Conflitos de interesse: Os autores declaram não possuir conflitos de interesse.

Financing Support: This work has not received any contribution, grant or scholarship.

Suporte financeiro: O presente trabalho não foi suportado por nenhum subsídio ou bolsa.

Confidentiality of data: The authors declare that they have followed the protocols of their work center on the publication of data from patients.

Confidencialidade dos dados: Os autores declaram ter seguido os protocolos do seu centro de trabalho acerca da publicação dos dados de doentes.

Protection of human and animal subjects: The authors declare that the procedures followed were in accordance with the regulations of the

relevant clinical research ethics committee and with those of the Code of Ethics of the World Medical Association (Declaration of Helsinki).

Proteção de pessoas e animais: Os autores declaram que os procedimentos seguidos estavam de acordo com os regulamentos estabelecidos pelos responsáveis da Comissão de Investigação Clínica e Ética e de acordo com a Declaração de Helsínquia da Associação Médica Mundial.

References

1. Psathas G, Zarokosta M, Zoulamoglou M, Chrysikos D, Thivaos I, Kaklamanos I, et al. Leiomyomatosis peritonealis disseminata: A case report and meticulous review of the literature. *Int J Surg Case Rep.* 2017;40:105-8.
2. Raspagliesi F, Quattrone P, Grosso G, Cobellis L, Di Re E. Malignant degeneration in leiomyomatosis peritonealis disseminate. *Gynecol Oncol.* 1996;61:272-4.
3. Al-Talib A, Al-Farsi AR, Stanimir G. Leiomyomatosis peritonealis disseminata with features of carcinomatosis on laparoscopy: A case report. *Sultan Qaboos Univ Med J.* 2009;9:315-8.
4. N Halama N, Grauling-Halama SA, Daboul I. Familial clustering of leiomyomatosis peritonealis disseminata: an unknown genetic syndrome? *BMC Gastroenterol.* 2005;5:33.
5. Bekkers RL, Willemsen WN, Schijf CP, Massuger LF, Bulten J, Merkus JM. Leiomyomatosis peritonealis disseminata: does malignant transformation occur? A literature review. *Gynecol Oncol.* 1999;75:158-63.
6. Kökçü A, Alvir Y, Barış YS, Kuşkonmaz I. Leiomyomatosis peritonealis disseminata. *Acta Obstet Gynecol Scand.* 1994;73:81-3.
7. Lausen I, Jensen OJ, Andersen E, Lindahl F. Disseminated peritoneal leiomyomatosis with malignant change, in a male. *Virchows Arch A Pathol Anat Histopathol.* 1990;417:173-5.
8. Nappi L, Sorrentino F, Angioni S, Pontis A, Barone I, Greco P. Leiomyomatosis peritonealis disseminata (LPD) ten years after laparoscopic myomectomy associated with ascites and lymph nodes enlargement: a case report. *Int J Surg Case Rep.* 2016;25:1-3.
9. Lu B, Xu J, Pan Z. Iatrogenic parasitic leiomyoma and leiomyomatosis peritonealis disseminata following uterine morcellation. *J Obstet Gynaecol Res.* 2016;42:990-9.
10. Xiao J, Zhang R, Teng Y, Liu B. Disseminated peritoneal leiomyomatosis following laparoscopic myomectomy: a case report. *J Int Med Res.* 2019;47:5301-6.
11. Li J, Dai S. Leiomyomatosis peritonealis disseminata: a clinical analysis of 13 cases and literature review. *Int J Surg Pathol.* 2020;28:163-8.
12. Xu S, Qian J. Leiomyomatosis peritonealis disseminata with sarcomatous transformation: a rare case report and literature review. *Case Rep Obstet Gynecol.* 2019;2019:3684282.
13. Syed M, Parida B, Mankeshwar T, Patil A. Imaging findings in a rare case of leiomyomatosis peritonealis disseminata with malignant transformation. *Pol J Radiol.* 2017;82:426-30.
14. Lee WY, Noh JH. Leiomyomatosis peritonealis disseminate associated with appendiceal endometriosis: a case report. *J Med Case Rep.* 2015;9:167.