

ARP Case Report n° 19: What is your diagnosis?

Caso Clínico ARP n° 19: Qual o seu diagnóstico?

Manuel Cruz, João Facas, Paulo Donato

Serviço de Imagem Médica, Centro Hospitalar e Universitário de Coimbra, Coimbra, Portugal

Case Presentation

A 4-year-old male child was referred to our department with an incidental finding reported on an abdominal ultrasound which was performed during the diagnostic workup of an interauricular communication. The patient was asymptomatic. For further characterization of the aforementioned finding, a contrast-enhanced computed tomography (CE-CT) with multiplanar and maximum

intensity projection reformation (MIP) was performed, followed by digital subtraction angiography (DSA).

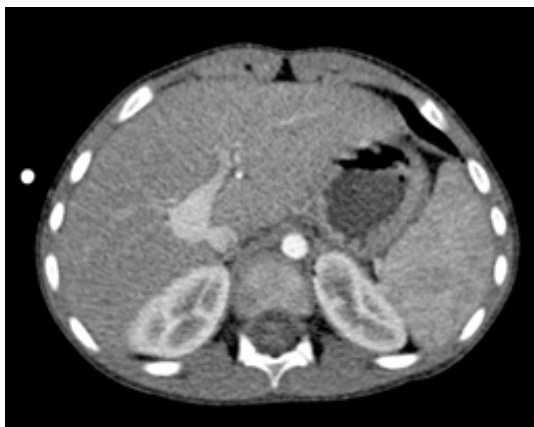

Figure 1

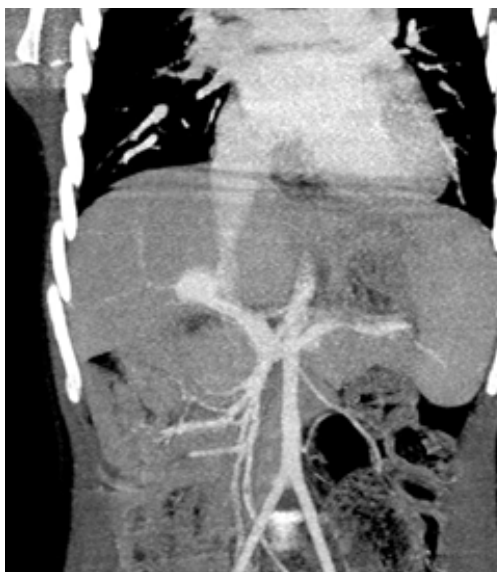

Figure 2

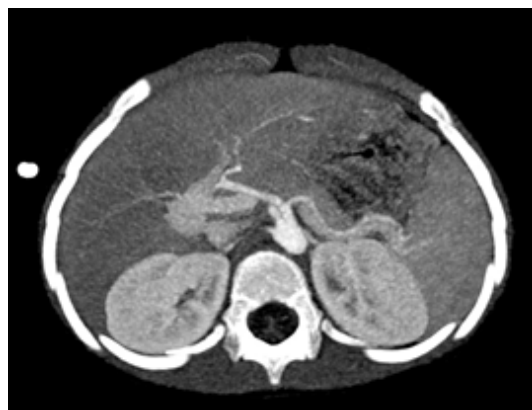

Figure 3

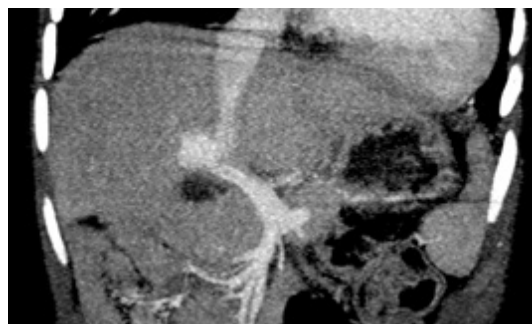


Figure 4

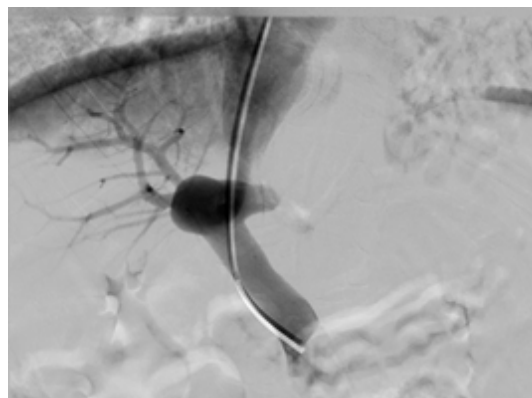


Figure 5

Send your answer containing the diagnosis (s) to the email address actarp.on@gmail.com.
The names of the authors of the correct answers will be published in the next issue of the ARP in the case solution.