

ARP Case Report n° 20: What is your diagnosis?

Caso Clínico ARP n° 20: Qual o seu diagnóstico?

Mónica Diniz¹, Miguel Oliveira Castro²

¹Serviço de Radiologia, Hospital Particular do Algarve, Faro, Portugal

²Serviço de Radiologia, Centro Hospitalar Universitário do Algarve (CHUA), Portimão, Portugal

Case Presentation

65-year-old female patient with a long history of rheumatoid arthritis, referred to the Radiology Department

to investigate an expansive shoulder lesion with peripheral nerve impairment and left upper limb paresis.

We present shoulder and elbow radiographies, as well as axial and sagittal shoulder CT reconstructions.

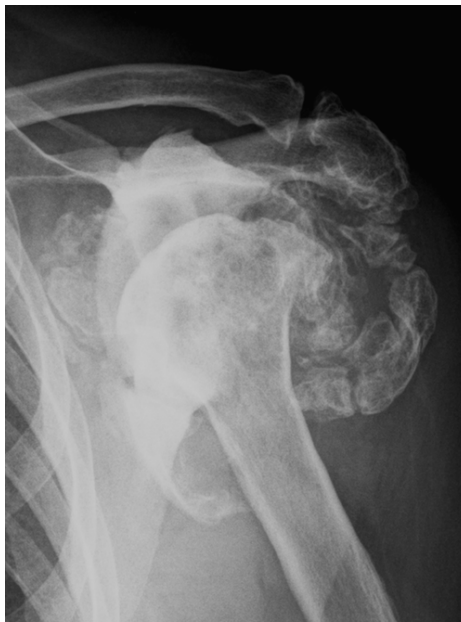

Figure 1

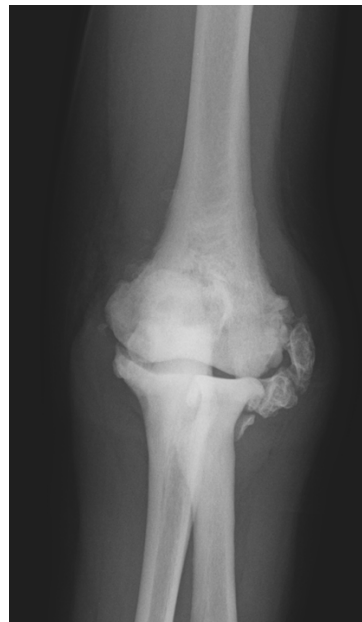

Figure 2

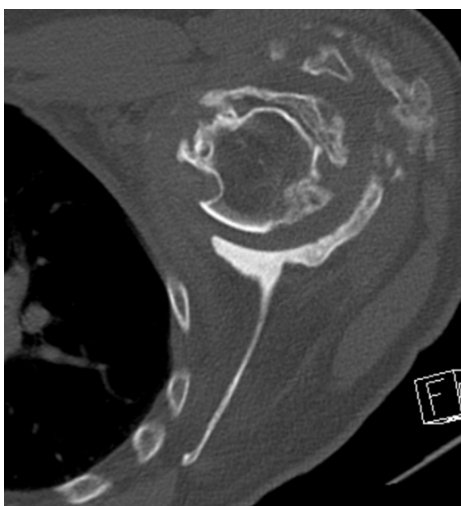


Figure 3

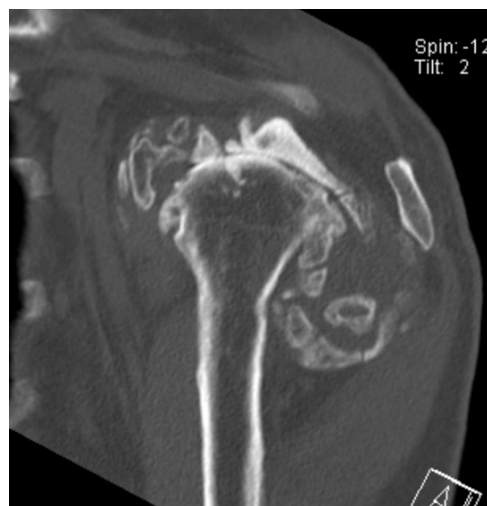

Figure 4

Send your answer containing the diagnosis (s) to the email address actarp.on@gmail.com.
The names of the authors of the correct answers will be published in the next issue of the ARP in the case solution.