

Images of Interest / Imagens de Interesse

Ovarian Fibromatosis – A Rare Bilateral Disorder*Fibromatose Ovariana Bilateral***Marco Antonio Alves Braun¹, Márcio Luís Duarte², Lucas Ribeiro dos Santos³, Marcelo de Queiroz Pereira da Silva⁴**¹Medical student, Faculty of Medical Sciences of Santos, Sao Paulo, Brasil²Radiologist, WEBIMAGEM, São Paulo, Brazil. Master in Evidence-Based Health - UNIFESP, São Paulo, Brasil³Professor of Endocrinology and Metabology at the Faculty of Medical Sciences of Santos, Sao Paulo, Brasil. Master in Evidence-Based Health - UNIFESP, Sao Paulo, Brasil⁴Chief physician, WEBIMAGEM, São Paulo, Brasil**Address**

Márcio Luís Duarte
WEBIMAGEM
Avenida Marquês de São Vicente 446
São Paulo, Brasil.
e-mail: marcioluisduarte@gmail.com

Received: 01/04/2021**Accepted:** 21/05/2021**Published:** 10/09/2021

© Author(s) (or their employer(s)) and ARP
2021. Re-use permitted under CC BY-NC. No
commercial re-use.

Abstract

Ovarian fibromatosis is a benign rare disorder that affects young women and is characterized microscopically by spindle cell proliferation and abundant collagen matrix. It may present similar clinical and radiological findings as other neoplasms. The clinical presentation may include abdominal pain, menstrual irregularity and possibly hirsutism and virilization. Magnetic resonance will show a hypointense signal on T1 and T2 weighted images and the black wreath sign. Once the diagnosis is established, conservative treatment with the objective of preserving fertility and ovarian function should be preferred.

Keywords

Ovary; Ovarian neoplasms; Magnetic resonance imaging.

Resumo

A fibromatose ovariana é uma entidade benigna rara que afeta mulheres jovens, sendo caracterizada microscopicamente pela proliferação de células fusiformes e abundante matriz de colágeno. Por apresentar um quadro clínico e radiológico semelhante à de outras neoplasias mais comuns, a fibromatose ovariana deve ser diferenciada destas. No quadro clínico, a mulher apresenta dor abdominal, irregularidade menstrual e, por vezes, hirsutismo e virilização. No estudo de ressonância magnética, as lesões de fibromatose ovárica demonstram sinal hipointenso nas sequências ponderadas de T1 e T2 e o “sinal da coroa negra”. Uma vez feito o diagnóstico, deve realizar-se preferencialmente um tratamento conservador, a fim de preservar a fertilidade e função ovárica.

Palavras-chave

Ovário; Neoplasias ovarianas; Imagem por ressonância magnética.

The ovarian fibromatosis (OF) is a rare, benign, cause of ovarian enlargement, which affects young women,^{1,2} and is usually unilateral, but there are bilateral reports.^{1,2} Ovarian enlargement is characterized by diffuse fibrosis,² which determines menstrual irregularity, abdominal pain, and less commonly, hirsutism and virilization.^{1,2}

Magnetic resonance imaging (MRI) assists in the diagnosis, showing adnexal lesions with hypointense signal on T1 and T2 sequences, and an appearance of solid mass (resembling other pathologies, such as fibroma, tercoma, desmoid tumors and massive ovarian edema);¹ it may present an image similar to a black wreath on the T2 weighted sequence, attributed to fibrous tissue's low signal intensity,^{2,3} that helps distinguish it from other pathologies.

In ultrasonography, its echogenicity is variable, with preserved ovarian follicles in the periphery.³ In computed tomography, the image is relatively hyperdense, homogeneous and solid, and may present calcifications.³

The pathogenesis of ovarian fibromatosis is not fully understood due to its rarity.¹ According to Lalwani et al,³ it is believed that this may be a consequence of a long-standing ovarian edema. Microscopically, there's proliferation of spindle cells^{1,2} and an abundant collagen matrix between normal structures are seen,^{1,2,3} with no infiltrative pattern.^{1,2}

This fibrous tissue is also found in other neoplastic diseases such as fibroma, tercoma, Brenner, Krukenberg and desmoid tumors, which are differential diagnosis of ovarian fibromatosis.^{1,3} Due to ovarian enlargement and similar clinical picture, another differential diagnosis is the massive ovarian edema, but microscopically we are able to differentiate it: its histopathology shows stromal cells separated by edema fluid, along with dilation of lymphatic and vascular vessels.¹

There have been described associations of ovarian fibromatosis with omentum fibrosis, idiopathic sclerotizing peritonitis and intraperitoneal fibromatosis,¹ the latter more related to androgenic manifestations.¹

The therapeutic approach will depend on patient's age and MRI findings. However, a more conservative one, in order to preserve fertility and ovarian function, should be prioritized. Oophorectomy or salpingo-oophorectomy should be reserved to extreme cases.¹

We report the case of a 46-year-old woman, in a routine consultation, who underwent transvaginal ultrasonography, which demonstrated bilateral adnexal, lobulated and heterogeneous mass (Figure 1). Informed consent was obtained from the patient. She was asymptomatic, and had no medical conditions background. She reported menarche

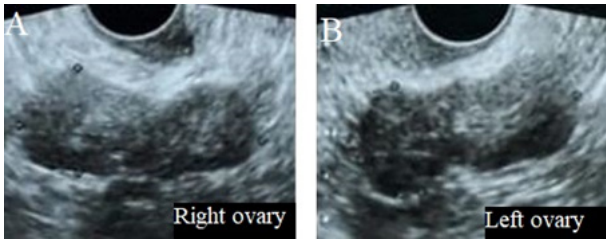


Figure 1 – Ultrasonography demonstrating a lobulated and heterogeneous mass in the right ovary (A) and in the left ovary (B).

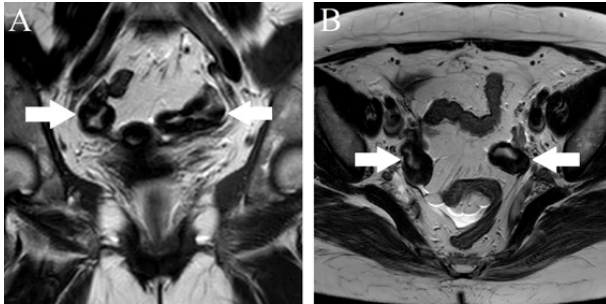


Figure 2 – MRI in T2 weighted sequence (A, coronal image; B, axial image) demonstrate increased ovarian size, fibrous thickening with its trapping follicles (white arrows).

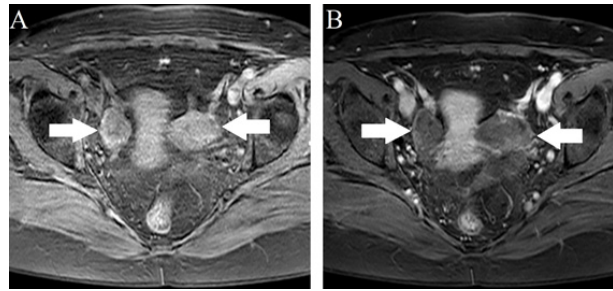


Figure 3: MRI in axial section, T1 FAT SAT sequence, non-enhanced (A) and enhanced (B) images, showing enlarged ovaries with fibrous thickening of their margins, trapping follicles, with heterogeneous contrast enhancement (white arrows), compatible with bilateral ovarian fibromatosis.

at 11 years old, and premature menopause at 37 years old. Physical examination was unremarkable. She performed an MRI, which demonstrated both ovaries of increased dimensions, with its fibrous edges thickening that traps follicles, along with heterogeneous contrast enhancement (Figures 2 and 3). Such findings were consistent with bilateral ovarian fibromatosis, and the patient has been followed up on an outpatient basis ever since, with no further clinical or surgical interventions.

Ethical disclosures / Divulgações Éticas

Conflicts of interest: The authors have no conflicts of interest to declare.

Conflitos de interesse: Os autores declaram não possuir conflitos de interesse.

Financing Support: This work has not received any contribution, grant or scholarship.

Suporte financeiro: O presente trabalho não foi suportado por nenhum subsídio ou bolsa.

Confidentiality of data: The authors declare that they have followed the protocols of their work center on the publication of data from patients.

Confidencialidade dos dados: Os autores declaram ter seguido os protocolos do seu centro de trabalho acerca da publicação dos dados de doentes.

Protection of human and animal subjects: The authors declare that the procedures followed were in accordance with the regulations of the relevant clinical research ethics committee and with those of the Code of Ethics of the World Medical Association (Declaration of Helsinki).

Proteção de pessoas e animais: Os autores declaram que os procedimentos seguidos estavam de acordo com os regulamentos estabelecidos pelos responsáveis da Comissão de Investigação Clínica e Ética e de acordo com a Declaração de Helsínquia da Associação Médica Mundial.

References

- Onderoglu LS, Gultekin M, Dursun P, Karcaaltincaba M, Upsubutum A, Akata D, Ayhan A. Bilateral ovarian fibromatosis presenting with ascites and hirsutism. *Gynecologic Oncology*. 2004;94:223-5.
- Takeuchi M, Matsuzaki K, Sano N, Furumoto H, Nishitani H. Ovarian fibromatosis: magnetic resonance imaging findings with pathologic correlation. *J Comput Assist Tomogr*. 2008;32:776-7.
- Lalwani N, Patel S, Ha KY, Shanbhogue AK, Nagar M, Chintapalli KN, Prasad SR. Miscellaneous tumour-like lesions of the ovary: cross-sectional imaging review. *Br J Radiol*. 2012;85:477-86.