

ARP Case Report n° 23: What is your diagnosis?

Caso Clínico ARP n° 23: Qual o seu diagnóstico?

Tiago Oliveira, João Macedo, Carlos Oliveira, Luís Curvo Semedo, Paulo Donato

Serviço de Radiologia, Centro Hospitalar e Universitário de Coimbra, Coimbra, Portugal

Case Presentation

A 46-year-old female patient presented with a neck swelling with a progressive growth over the last 20 years. On physical examination, a pulsating firm painless mass was found on the right side of her neck, near the angle of the

mandible. There were no pressure symptoms, and it was more mobile horizontally than vertically (Fontaine sign). Pulsations were felt on deep palpation and a faint bruit was heard on auscultation. Cervical computed tomography (CT) and digital subtraction angiography were performed for further investigation.

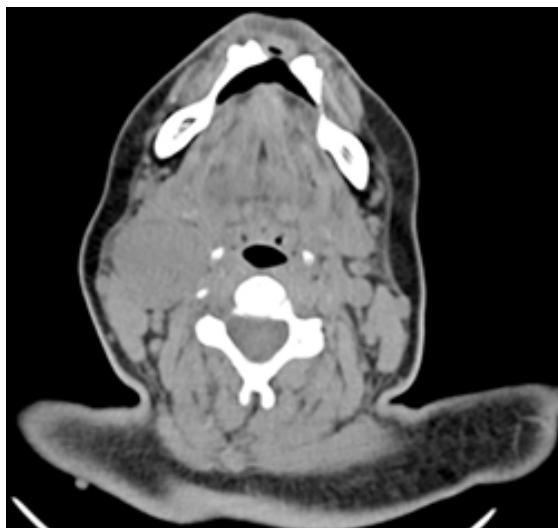


Figure 1 – Axial soft tissue window, 2 mm slice thickness, non-enhanced CT.

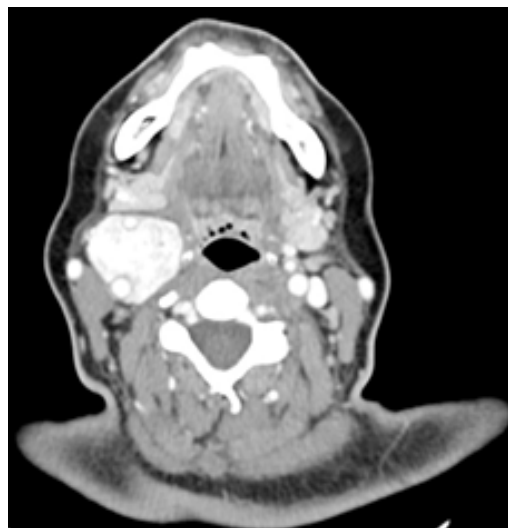


Figure 2 – Axial soft tissue window, 2 mm slice thickness, contrast-enhanced CT.

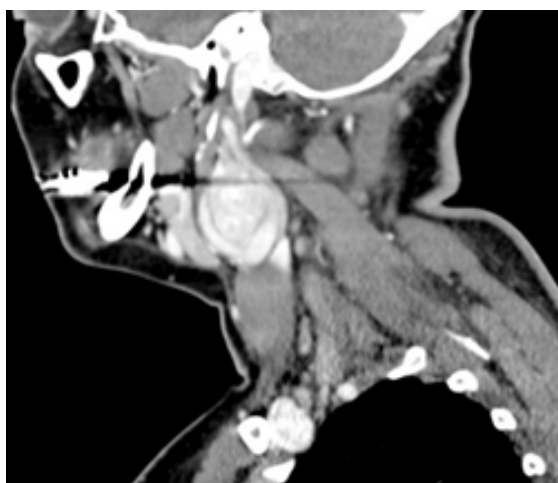


Figure 3 – Sagittal soft tissue window, 2 mm slice thickness, contrast-enhanced CT.

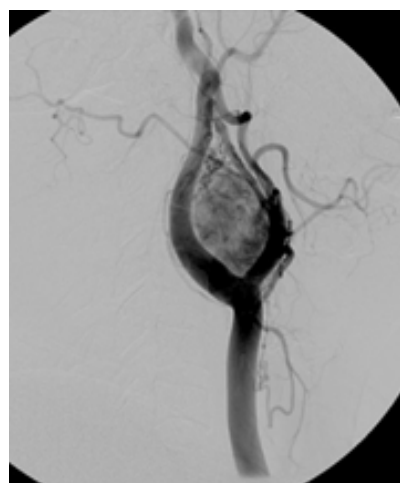


Figure 4 – Right carotid angiogram.

Send your answer containing the diagnosis (s) to the email address actarp.on@gmail.com. The names of the authors of the correct answers will be published in the next issue of the ARP in the case solution.