

Images of Interest / Imagens de Interesse

Bipartite Ulnar Nerve - A Rare Anatomical Variation*Nervo Cubital Bipartido - Uma Variação Anatômica Rara*Marta Henriques Oliveira¹, Jorge Garcia², João Madruga Dias^{2,3}

¹ Interna de Medicina Geral e Familiar, USF Cardilium, ACES Médio Tejo, Torres Novas, Portugal

² Especialista em Reumatologia, Serviço de Reumatologia, Centro Hospitalar Médio Tejo, Torres Novas, Portugal

³ Epidoc Unit, Centro de Estudos de Doenças Crónicas, Nova Medical School, Lisboa, Portugal

Address

João Madruga Dias
Serviço de Reumatologia
Centro Hospitalar Médio Tejo
Rua Xanana Gusmão N° 45
2350-754 Torres Novas, Portugal
e-mail: joao_alexandre@hotmail.com

Received: 29/09/2021

Accepted: 31/10/2021

Published: 13/01/2022

© Author(s) (or their employer(s)) and ARP
2021. Re-use permitted under CC BY-NC. No commercial re-use.

Abstract

The diagnosis of peripheral neuropathies and motor deficits may be difficult and requires a deep knowledge of the peripheral nerves anatomy.

We present an image of an elbow ultrasonography that revealed a rare anatomical variation of the ulnar nerve in a patient with symptoms compatible to an ulnar entrapment syndrome.

Keywords

Ulnar nerve; Anatomy; Ultrasonography.

Resumo

O diagnóstico etiológico de neuropatias periféricas e défices motores pode ser difícil e requer um conhecimento anatómico aprofundado dos nervos periféricos.

Neste artigo apresentamos imagens de uma ultrassonografia do cotovelo de uma doente com sintomas compatíveis com síndrome de compressão cubital, que revelou uma variação anatómica rara do nervo cubital.

Palavras-chave

Nervo cubital; Anatomia; Ultrassonografia.

Case

A 45-year-old woman, housekeeper, was sent to the Rheumatology appointment for pain and functional limitation in extension and flexion movements of the fingers, accompanied numbness in the 4th and 5th finger of the right hand. This clinical depiction had 2,5 years of evolution, with progressive worsening. The physical exam showed pain at palpation of ulnar nerve in the ulnar fossa of the right elbow. Blood tests and electromyography studies did not show any significant changes. Ultrasonography of the elbow revealed no changes of the median and radial nerves. The Ulnar Nerve (UN) presented without any anomalies in its entire course, except being bipartite in a small portion immediately proximal to the ulnar fossa, returning then to its unique configuration. (Fig. 1). This anatomic variation was then confirmed by Magnetic Resonance Imaging (MRI) as illustrated in Figure 2. The patient was referred to Plastic Surgery and submitted to an ulnar nerve surgical decompression at proximal level. Two weeks after surgery a sustained marked improvement of the numbness was confirmed.

Discussion

Anatomical variations of the UN can occur in all its course however, the ones occurring along UN proximal course are rarely described in the literature.¹

Although there are descriptions of peripheral neuropathies associated with bipartite median nerve,² our research did not find a similar description of bipartite UN at a proximal level. Olave et al have previously described a variation at a more distal level in which the UN divides in two branches proximal to the distal wrist crease, reuniting again distal to the distal wrist crease and forming the common palmar digital nerve of the 4th interosseous space.³

This case demonstrates the importance of deep anatomy knowledge in the evaluation of peripheral neuropathies and motor deficits, that overlooked can result in delays of diagnosis.

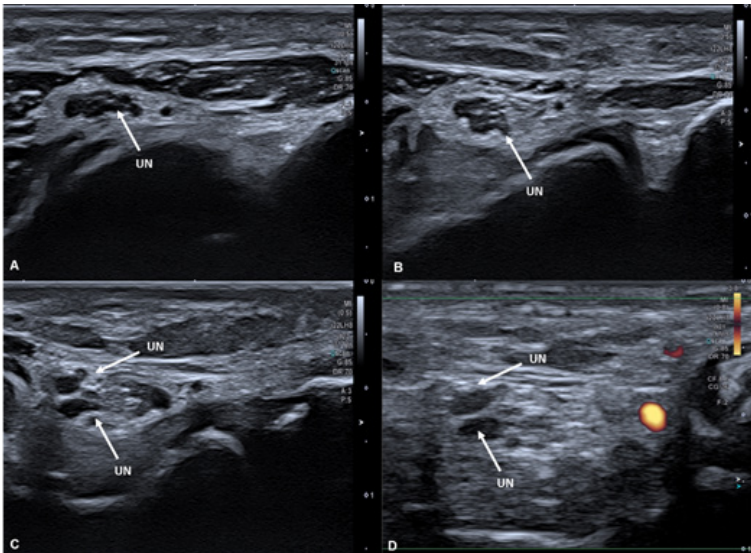


Figure 1 – Right Elbow Ultrasonography Transverse Cut: Ulnar nerve at different levels of its course going distal to proximal (1A to 1D). It starts with its usual unique configuration (1A and 1B) and then starts to split (1C). Through Fig. 1D it is possible to distinguish the ulnar nerve (without Power Doppler signal) from blood vessels (with Power Doppler signal).

Abbreviations: UN - Ulnar Nerve.

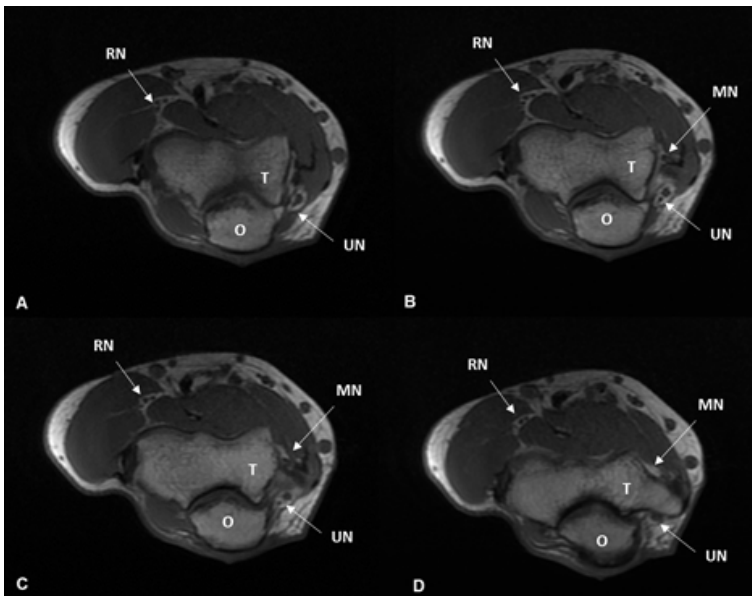


Figure 2 – Right Elbow MRI T1 Weighted Axial Cut: ulnar nerve at different levels, going from distal to proximal (2A to 2D). It is possible to observe the bipartite ulnar nerve in a small portion of its path (2B and 2C) and then it returns to its unique configuration (2D)

Abbreviations: MN - Median Nerve, O - Olecranon process, RN - Radial Nerve, T - Trochlea, UN - Ulnar Nerve.

Ethical disclosures / Divulgações Éticas

Conflicts of interest: The authors have no conflicts of interest to declare.

Conflitos de interesse: Os autores declaram não possuir conflitos de interesse.

Financing Support: This work has not received any contribution, grant or scholarship.

Suporte financeiro: O presente trabalho não foi suportado por nenhum subsídio ou bolsa.

Confidentiality of data: The authors declare that they have followed the protocols of their work center on the publication of data from patients.

Confidencialidade dos dados: Os autores declaram ter seguido os protocolos do seu centro de trabalho acerca da publicação dos dados de doentes.

Protection of human and animal subjects: The authors declare that the procedures followed were in accordance with the regulations of the relevant clinical research ethics committee and with those of the Code of Ethics of the World Medical Association (Declaration of Helsinki).

Proteção de pessoas e animais: Os autores declaram que os procedimentos seguidos estavam de acordo com os regulamentos estabelecidos pelos responsáveis da Comissão de Investigação Clínica e Ética e de acordo com a Declaração de Helsínquia da Associação Médica Mundial.

References

1. Guru A, Kumar N, Swamy RS, Jyothsna P, Badagabettu SN, Ashwini AP, Venumadhav N. Anatomical study of the ulnar nerve variations at high humeral level and their possible clinical and diagnostic implications. *Anatomy Research International*. 2015;2015:378063.
2. Takami H, Takahashi S, Ando M. Bipartite median nerve with a double compartment within the transverse carpal canal. *Arch Orthop Trauma Surg*. 2001;121:230-1.
3. Olave E, Del Sol M, Gabrielli C, Prates JC, Rodrigues CF. The ulnar tunnel: a rare disposition of its contents. *J Anat*. 1997;191:615-6.