

Images of Interest / Imagens de Interesse

Radiation Recall Myositis

Miosite Induzida pela Radioterapia

Mayara Oliveira da Silva¹, Márcio Luís Duarte²

¹Universidade Federal de São Paulo - Campus Baixada Santista, Santos-SP, Brasil.

²Universidade de Ribeirão Preto (UNAERP) - Campus Guarujá, Guarujá-SP, Brasil

Address

Márcio Luís Duarte
Universidade de Ribeirão Preto (UNAERP) -
Campus Guarujá
Av. D. Pedro I, 3.300, Enseada
Guarujá-SP, 11440-003, Brasil
e-mail: marcioluisduarte@gmail.com

Received: 09/05/2022

Accepted: 18/07/2022

Published: 29/12/2023

© Author(s) (or their employer(s)) and ARP
2023. Re-use permitted under CC BY-NC. No
commercial re-use.

Abstract

We report a 55-year-old man who underwent treatment for resection of myxoid liposarcoma with radiotherapy and chemotherapy sequences. The patient had what we call radiation recall - it is a localized inflammatory reaction triggered by the use of cytotoxic agents. While usually limited to the superficial tissues and manifesting as a cutaneous reaction, cases of deeper inflammation involving the muscles have been reported with gemcitabine.

Keywords

Radiotherapy; Radiation; Radiation effects;
Radiation injuries; Magnetic resonance imaging.

Resumo

Relatamos um homem de 55 anos de idade que foi submetido a tratamento para ressecção de lipossarcoma mixóide seguido de radioterapia e quimioterapia. O paciente apresentou miosite induzida pela radioterapia - trata-se de uma reação inflamatória localizada desencadeada pelo uso de agentes citotóxicos. Embora geralmente limitado aos tecidos superficiais e manifestando-se como reação cutânea, foram relatados casos de inflamação profunda envolvendo os músculos geralmente associada ao uso de gencitabina.

Palavras-chave

Radioterapia; Radiação; Efeitos da radiação;
Lesões por radiação; Imagem por ressonância
magnética.

A 55-year-old man refers to edema in his right thigh for one year. He underwent resection of myxoid liposarcoma in his right thigh 13 months ago. Subsequently, he performed 33 sessions of radiotherapy and twelve sessions of chemotherapy with doxorubicin and ifosfamide. He treats diabetes mellitus with a diet. He states that the thigh edema worsens during the day, improving when sleeping, presenting together with intermittent pain of mild intensity since the eighth session of chemotherapy – after finishing radiotherapy and less than four months after initiation of the chemotherapy. Physical examination shows the darkening and thickening of the skin in the medial region of the thigh without pain on palpation. He has difficulty flexing the hip and knee, having difficulty in crouching, and performing movements with pain.

In the first test after radiotherapy and chemotherapy, magnetic resonance imaging (MRI) demonstrates an extensive collection between the semimembranosus and adductor Magnus muscles. It also demonstrated a slight high signal of the vastus medialis, adductor longus, adductor Magnus, sartorius, gracilis, semimembranosus, and semitendinosus muscles, being compatible with radiation-induced myositis (Figure 1). He started treatment with corticoids, and sixteen months later, he had no symptoms and the MRI was normal (Figure 2).

The detail of radiation recall pathophysiology remains to be elucidated. Peritumoral normal tissue is, surely, irradiated during radiotherapy. It also depends on the area and dimensions of the target volume as well as the accumulative dosage.¹ Relying on the temporal period after irradiation,

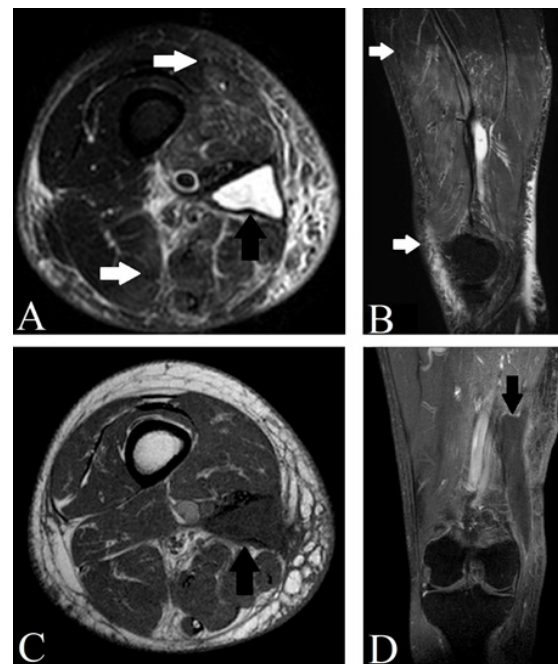


Figure 1 – T2 STIR sequence MRI in axial (A), and sagittal (B) sections demonstrating a radiation-induced myositis (white arrows) and collection (black arrow). T1 sequence MRI in axial section (C), and T1 SPIR with contrast coronal section (D) demonstrating the collection (black arrow).

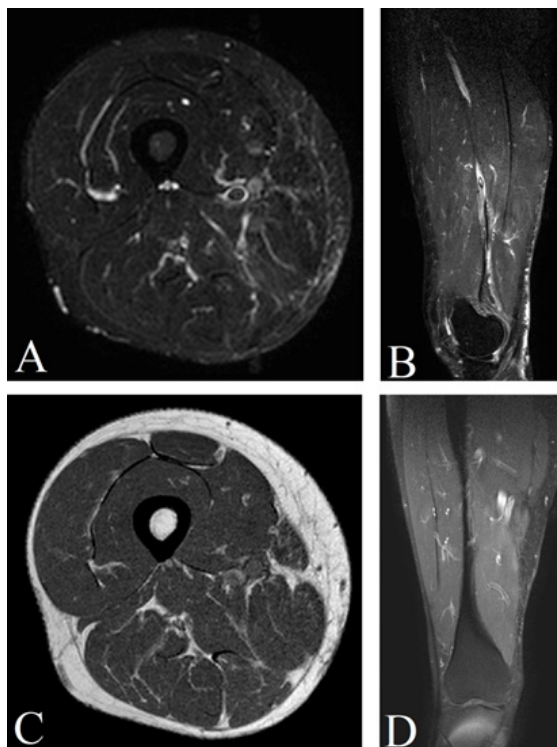


Figure 2 – T2 STIR MRI in axial (A), and sagittal (B) sections, T1 axial section (C), and T1 SPIR with contrast coronal section demonstrating a normal thigh after appropriate treatment.

acute, subacute, and chronic changes are reported in co-irradiated normal tissue that can be identified by imaging.¹ Radiation injury can be temporary or constant.¹

Radiation-induced muscle injury is rarely reported in the literature.² A possible determinant of radiation-related muscle injury is a 'high' dose per fraction, but lesions usually (but very occasionally) occur at a total dosage of over 50 Gy.¹ Radiation recall is a rare phenomenon, defined as an acute inflammation triggered by subsequent chemotherapy that develops in a previously irradiated field.² A several range of drugs utilized in the treatment of cancer is correlated with radiation recall.⁴ It is not possible to determine the true incidence.³ On the other hand, the antineoplastic drugs with which radiation recall reactions have been most commonly reported include the:³

- Anthracycline doxorubicin
- Taxanes docetaxel and paclitaxel
- Antimetabolites gemcitabine and capecitabine.

The critical differential diagnosis is post-therapeutic tumor recurrence.¹ Typical latency periods, location and matching with the radiation field are essential differentiation criteria as well, depending on the tumor biology and the radiation technique.¹

The treatment involves rapidly stopping the use of a chemotherapeutic agent and treating with corticosteroids, analgesia, topical creams, or no therapy until symptoms improve.² It remains a poorly understood phenomenon, but increased awareness may aid in early diagnosis and appropriate management.³ There are no identifiable features of drugs that cause radiation recall.³ Therefore, there is a chance that any drug is used after radiotherapy, including those from new drug classes.³

The radiologist must be aware of the characteristic imaging morphology of radiogenic tissue modifications to detour erroneous interpretations during follow-up studies.¹

Ethical Disclosures / Divulgações Éticas

Conflicts of interest: The authors have no conflicts of interest to declare.

Conflitos de interesse: Os autores declaram não possuir conflitos de interesse.

Financing Support: This work has not received any contribution, grant or scholarship.

Suporte financeiro: O presente trabalho não foi suportado por nenhum subsídio ou bolsa.

Confidentiality of data: The authors declare that they have followed the protocols of their work center on the publication of data from patients.

Confidencialidade dos dados: Os autores declaram ter seguido os protocolos do seu centro de trabalho acerca da publicação dos dados de doentes.

Protection of human and animal subjects: The authors declare that the procedures followed were in accordance with the regulations of the relevant clinical research ethics committee and with those of the Code of Ethics of the World Medical Association (Declaration of Helsinki).

Proteção de pessoas e animais: Os autores declaram que os procedimentos seguidos estavam de acordo com os regulamentos estabelecidos pelos responsáveis da Comissão de Investigação Clínica e Ética e de acordo com a Declaração de Helsínquia da Associação Médica Mundial.

References

1. Welzel T, Tanner JM. Imaging of side effects after radiation therapy. *Radiologe*. 2018;58:754-61.
2. Eckardt MA, Bean A, Selch MT, Federman N. A child with gemcitabine-induced severe radiation recall myositis resulting in a compartment syndrome. *J Pediatr Hematol Oncol*. 2013;35:156-61.
3. Aubrey J, Esfandiari N, Baracos VE, Buteau FA, Frenette J, Putman CT, Mazurak VC. Measurement of skeletal muscle radiation attenuation and basis of its biological variation. *Acta Physiol*. 2014;210:489-97.