

ARP Case Report n° 28: What is your diagnosis?

Caso Clínico ARP n° 28: Qual o seu diagnóstico?

Tiago Oliveira; Filipa Bento, Luís Amaral Ferreira; Carlos Oliveira; Paulo Donato

Serviço de Radiologia, Centro Hospitalar e Universitário de Coimbra, Coimbra, Portugal

Case Presentation

A 78-year-old female patient was admitted to the emergency department of our institution with a history of psychomotor retardation, myoclonus and dysarthria, over the last 2 months. Her past medical history only included atrial fibrillation with a rapid ventricular response. The neurological examination confirmed the findings mentioned above and an electroencephalography was performed which showed the presence of encephalopathy. The patient was admitted with a presumptive diagnosis of transmissible spongiform

encephalopathy (Creutzfeldt-Jakob disease). A cerebral MRI (not shown) was conducted, which not only excluded this diagnosis but also revealed the presence of areas of hyperintense signal on T1-weighted images with ill-defined margins, symmetrically affecting the globus pallidus and the medial region of the cerebral peduncles' feet. These findings were compatible with liver encephalopathy. Computed Tomography (CT) of the abdomen and Digital Subtraction Venography (DSV) were performed for further investigation. What is your diagnosis?

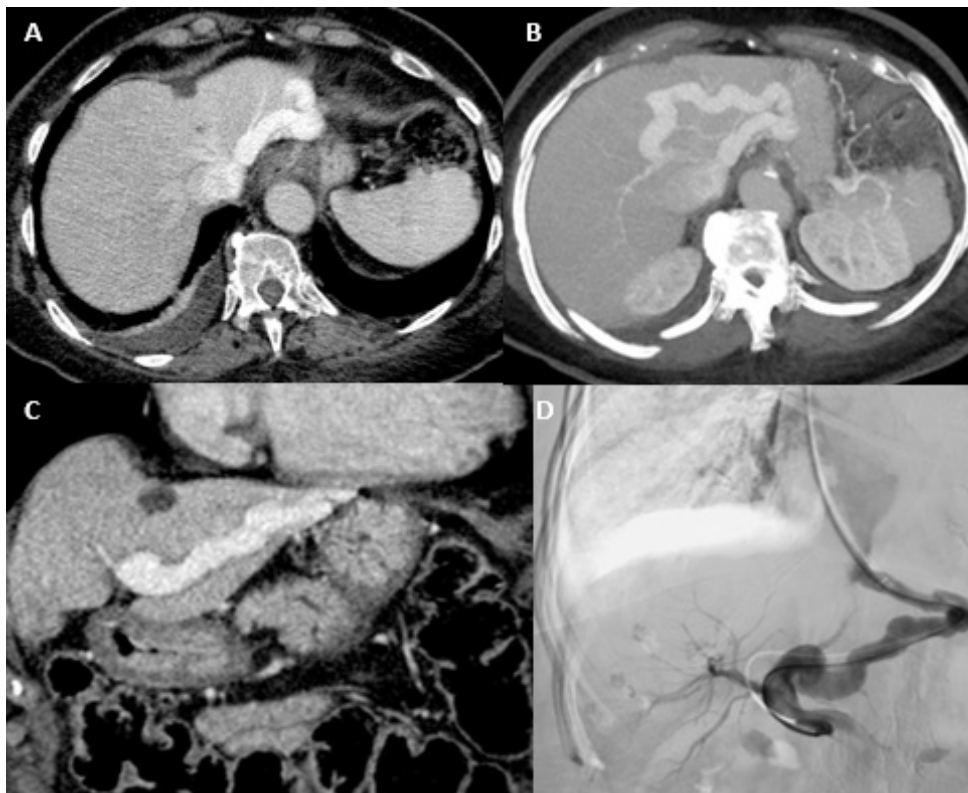


Figure 1 – A - Axial soft tissue window, 3 mm slice thickness, contrast-enhanced CT; B - Axial soft tissue window, MIP reformation = 15 mm slice thickness, contrast-enhanced CT; C - Coronal soft tissue window, 3 mm slice thickness, contrast-enhanced CT; D - Abdominal venography.

Send your answer containing the diagnosis (s) to the email address actarp.on@gmail.com.
The names of the authors of the correct answers will be published in the next issue of the ARP in the case solution.