

## ARP Case Report n° 29: What is your diagnosis?

*Caso Clínico ARP n° 29: Qual o seu diagnóstico?*

Lúis Maduro<sup>1</sup>, Rita Cartucho<sup>2</sup>, Francisco Grilo<sup>3</sup>, Carlos Bilreiro<sup>4</sup>

<sup>1</sup>Serviço de Radiologia, Centro Hospitalar de Lisboa Ocidental, Lisboa, Portugal

<sup>2</sup>Serviço de Radiologia, Hospital Prof. Doutor Fernando Fonseca, Amadora, Portugal

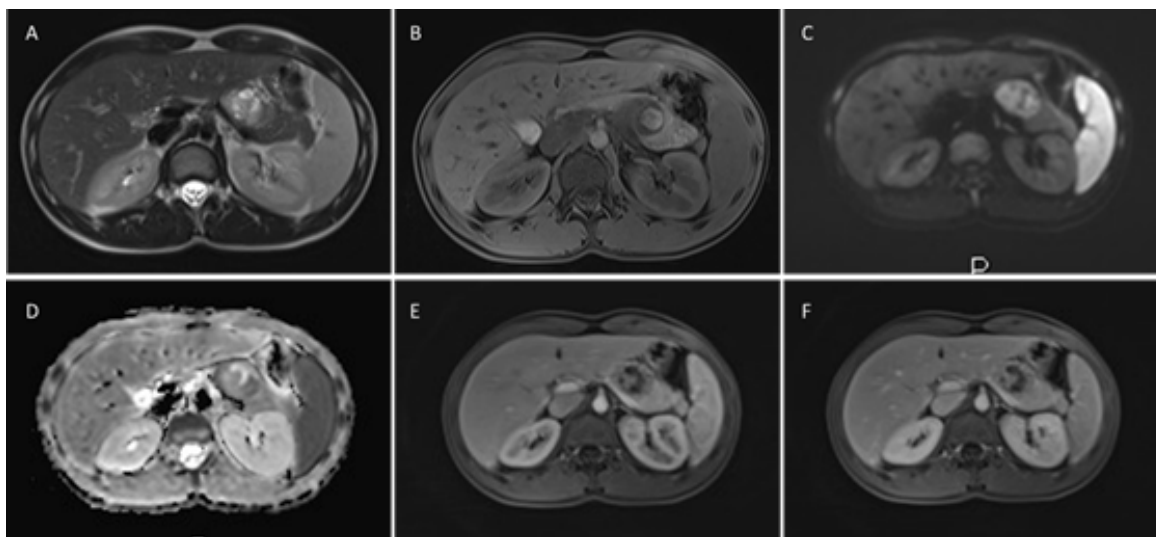
<sup>3</sup>Serviço de Radiologia, Hospital de Braga, Braga, Portugal

<sup>4</sup>Serviço de Radiologia, Fundação Champalimaud, Lisboa, Portugal

### Case Presentation

A 19-year-old female was referred to our institution for an incidental finding during a check-up ultrasound for nonspecific abdominal discomfort. The ultrasound showed a mixed lesion at the pancreas tail, with cystic and solid areas.

The patient was asymptomatic, with no relevant laboratory anomalies and her past medical history was unremarkable. A Magnetic Resonance (MR) was performed for further evaluation. What is your diagnosis?



**Figure 1** – Axial T2-weighted MR image (A), unenhanced fat-suppressed T1-weighted MR image (B), diffusion-weighted imaging b800 (C) and ADC map (D) MR images, contrast-enhanced fat-suppressed T1-weighted MR images in the arterial-phase (E) and delayed-phase (F).

Send your answer containing the diagnosis (s) to the email address [actarp.on@gmail.com](mailto:actarp.on@gmail.com).  
The names of the authors of the correct answers will be published in the next issue of the ARP in the case solution.