

ARP Case Report nº 31: What is your diagnosis?

Caso Clínico ARP nº 31: Qual o seu diagnóstico?

Matilde Gonçalves¹, Vitor Rego¹, Rodrigo Sequeira², Francisco Raposo¹, Inês Gil¹

¹Serviço de Radiologia, Unidade Local de Saúde do Algarve - Hospital de Faro, Faro, Portugal

²Serviço de Reumatologia, Unidade Local de Saúde do Algarve - Hospital de Faro, Faro, Portugal

A 58-year-old male individual, with a personal history of obesity and chronic alcohol abuse, was admitted to the emergency department with a recent worsening of chronic low back pain. On objective examination, there was intense pain (8/10) upon palpation of the spinous processes and paraspinous soft tissues, as well as peripheral joint deformities. Simple lumbosacral radiography (Figure 1), computerized tomography (Figure 2) and magnetic resonance

imaging (Figure 3) of the lumbosacral spinal column were performed. Fractures of the L3 and L4 vertebral bodies were diagnosed, the latter having already undergone percutaneous cementoplasty.

Additionally, an increase in the dimensions of the right posterior joint mass was identified at L3-L4 – how to name this pathological finding?

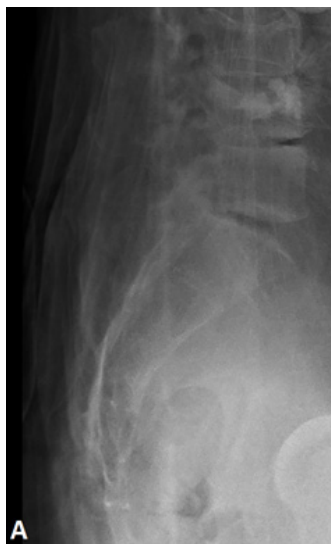

Figure 1.

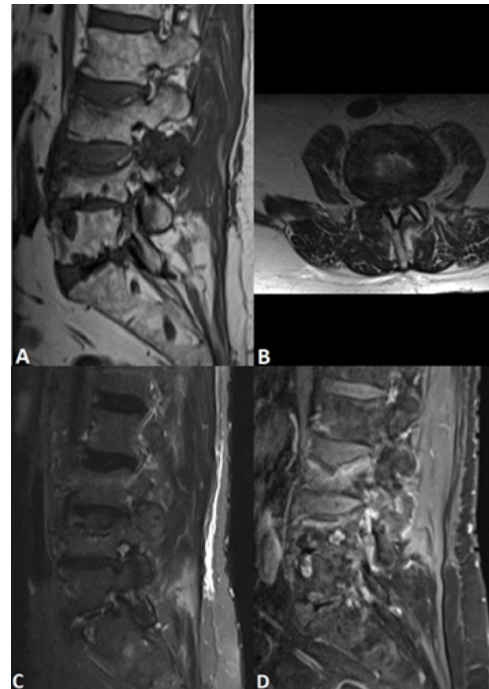


Figure 2.

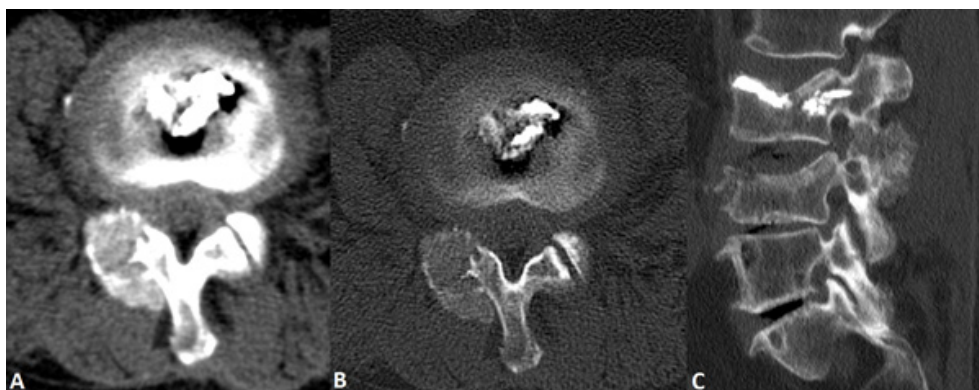


Figure 3.

Send your answer containing the diagnosis (s) to the email address actarp.on@gmail.com.

The names of the authors of the correct answers will be published in the next issue of the ARP in the case solution.