

## Images of Interest / Imagens de Interesse

**Acute Idiopathic Scrotal Edema: An Important Diagnosis to Consider***Edema Escrotal Agudo Idiopático: Um Diagnóstico Importante a Considerar*João Dourado<sup>1</sup>, Filipe Barros Alves<sup>1</sup>, Maria Inês Rodrigues<sup>1</sup>, Sílvia Costa Dias<sup>1,2</sup>, Daniela Pinto<sup>1,2</sup><sup>1</sup>Serviço de Radiologia, Unidade Local de Saúde de São João, Porto, Portugal<sup>2</sup>Faculdade de Medicina, Universidade do Porto, Porto, Portugal**Address**João Dourado  
Serviço de Radiologia  
Unidade Local de Saúde de São João  
Alameda Prof. Hernâni Monteiro  
4200-319, Porto, Portugal  
e-mail: jdourado.md@gmail.com

Received: 21/09/2024

Accepted: 10/12/2024

Published: 31/12/2025

**Abstract**

Acute idiopathic scrotal edema is a self-limiting condition characterized by significant skin and dartos fascia swelling, sparing the deeper tissues, testes, and epididymis. Its recognition is essential to avoid unnecessary surgical intervention.

We report the case of a 7-year-old boy who presented with complicated acute appendicitis and subsequently developed painless, pronounced scrotal edema and erythema two days after surgery. Ultrasound and Doppler imaging revealed marked scrotal hypervascularity, including the “fountain sign” and hypoechoic thickening of the scrotal wall, while the testes and epididymis appeared normal. Acute idiopathic scrotal edema was diagnosed, and it resolved after four days of conservative treatment, confirming the diagnosis.

**Keywords**

Scrotum; Pediatric emergency medicine; Ultrasonography.

**Resumo**

O edema escrotal agudo idiopático é uma condição autolimitada caracterizada por edema exuberante da pele e da túnica de dartos, poupando os tecidos mais profundos, os testículos e os epidídimos. O seu reconhecimento é essencial para evitar intervenções cirúrgicas desnecessárias.

Descrevemos o caso de um menino de 7 anos internado por apendicite aguda complicada e que, dois dias após a cirurgia, desenvolveu marcado edema e eritema escrotal indolor. A ecografia e o estudo Doppler revelaram hipervascularização escrotal exuberante, incluindo o “sinal da fonte”, bem como espessamento hipocógeno dos planos escrotais, sem alterações dos testículos ou dos epidídimos. Assim, foi feito o diagnóstico de edema escrotal agudo idiopático, tendo-se observado resolução completa do quadro após quatro dias de tratamento conservador.

**Palavras-chave**

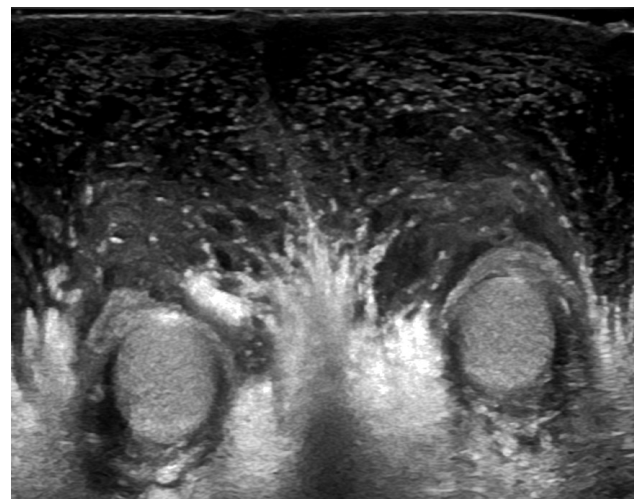
Escroto; Medicina de emergência pediátrica; Ecografia.

**Case Report**

A 7-year-old boy, with no significant medical history, was admitted with complicated acute appendicitis and underwent an appendectomy. Two days after surgery, he developed painless, marked scrotal swelling. Physical examination revealed significant scrotal edema and erythema without tenderness. Ultrasound (US) showed diffuse hypoechoic thickening of the scrotal wall and pronounced subcutaneous edema, while the testes and epididymis appeared normal (Figure 1). Doppler imaging demonstrated marked bilateral hypervascularity in the scrotal wall, including the “fountain sign” (Figure 2), with normal intratesticular blood flow (Figure 3). These findings were consistent with acute idiopathic scrotal edema (AISE). The patient was managed conservatively with anti-inflammatory and antihistamine medication. The edema entirely resolved after four days, and a follow-up US confirmed the resolution of hypervascularity and edema.

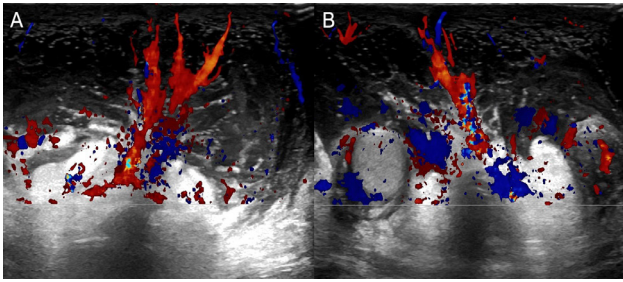
**Discussion**

AISE is a self-limiting condition primarily affecting boys under the age of 10 years old, accounting for about 10% of acute scrotum cases in children and adolescents.<sup>1</sup> Although its etiology remains unclear, AISE is generally thought to involve an exaggerated inflammatory response, related to a

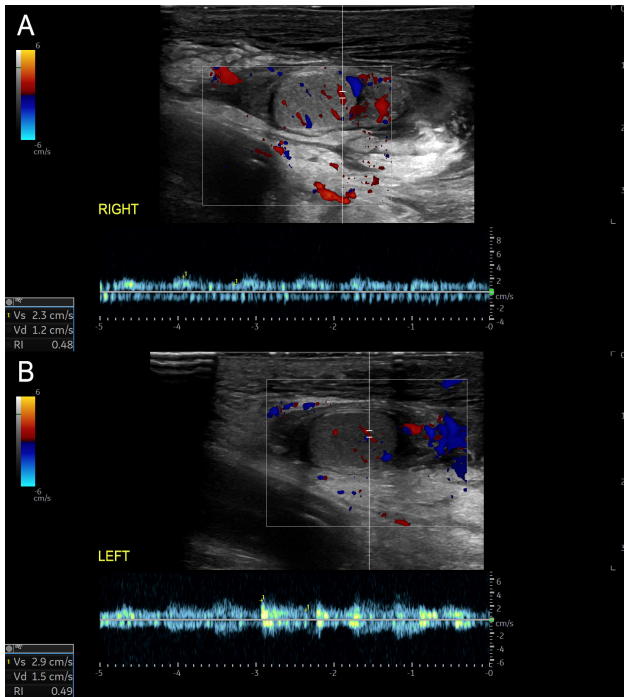


**Figure 1** – Transverse US scan showing diffuse thickening of the scrotal wall and pronounced subcutaneous edema, with unremarkable testes and epididymis.

variant of angioneurotic edema, leading to significant edema of the scrotal skin and dartos fascia.<sup>1,2</sup> The condition is usually painless and is characterized by sudden-onset scrotal swelling and redness without involvement of the deeper layers, testes, or epididymis.<sup>1,2,3</sup> Bilateral involvement is the usual presentation but unilateral AISE is described with variable occurrence rates in the literature.<sup>1,3</sup>



**Figure 2** – Transverse Color Doppler scans (A and B) showing the “fountain sign” (increased scrotal wall blood flow, resembling a colored fountain).



**Figure 3** – Longitudinal Color and Spectral Doppler scans showing normal right (A) and left (B) intratesticular blood flow, with preserved low-resistance waveforms.

#### Ethical Disclosures / Divulgações Éticas

*Conflicts of interest.* The authors have no conflicts of interest to declare.

*Conflitos de interesse.* Os autores declaram não possuir conflitos de interesse.

*Financing Support.* This work has not received any contribution, grant or scholarship.

*Suporte financeiro.* O presente trabalho não foi suportado por nenhum subsídio ou bolsa.

*Confidentiality of data.* The authors declare that they have followed the protocols of their work center on the publication of data from patients.

*Confidencialidade dos dados.* Os autores declaram ter seguido os protocolos do seu centro de trabalho acerca da publicação dos dados de doentes.

*Protection of human and animal subjects.* The authors declare that the procedures followed were in accordance with the regulations of the relevant clinical research ethics committee and with those of the Code of Ethics of the World Medical Association (Declaration of Helsinki).

From a radiological perspective, the diagnosis of AISE is often established using US, which is the modality of choice due to its non-invasive nature and high sensitivity for scrotal pathology.<sup>2</sup> US findings typically include diffuse thickening of the scrotal wall and marked subcutaneous edema, with unremarkable testes and epididymis.<sup>1,2</sup> Doppler imaging can further confirm the absence of testicular torsion by demonstrating normal intratesticular blood flow.<sup>3</sup> A distinctive feature observed on Doppler imaging in AISE is the “fountain sign”, characterized by hypervascularity in the scrotal skin and dartos fascia, due to increased flow in the anterior and posterior scrotal arteries.<sup>3</sup> This sign is considered a hallmark of AISE. It helps to differentiate it from other causes of acute scrotal swelling, such as epididymitis, orchitis, torsion of the appendix testis or testicular torsion, which usually present with more severe clinical symptoms and abnormal testicular findings on imaging.<sup>3</sup>

The management of AISE is conservative, primarily focusing on observation and symptomatic relief, such as anti-inflammatory medication and scrotal elevation.<sup>2</sup> The condition typically resolves spontaneously within a few days to a week, as shown by the complete resolution of symptoms and imaging findings returning to normal, as demonstrated in our case report. Early and accurate diagnosis of AISE is crucial to avoid unnecessary surgical exploration, which may be considered in cases of acute scrotal swelling due to the potential for more serious underlying conditions, and this case underscores the key role of imaging in diagnosis and management.<sup>2</sup>

#### Conclusion

AISE should be considered in the differential diagnosis of acute scrotal swelling, particularly in young pediatric patients, when imaging reveals normal testes and epididymis and the characteristic “fountain sign” on Doppler imaging. Radiologists play a key role in diagnosing and managing this condition, ensuring appropriate treatment and avoiding unnecessary surgical interventions.

*Proteção de pessoas e animais.* Os autores declaram que os procedimentos seguidos estavam de acordo com os regulamentos estabelecidos pelos responsáveis da Comissão de Investigação Clínica e Ética e de acordo com a Declaração de Helsínquia da Associação Médica Mundial.

#### References

1. Santi M, Lava S, Simonetti G, Bianchetti M, Milani G. Acute idiopathic scrotal edema: systematic literature review. *Eur J Pediatr Surg.* 2018;28:222-6.
2. Mesquita RD, Rosas JL. Adult acute scrotal edema - when radiologists can help to avoid unnecessary surgical treatment. *J Radiol Case Rep.* 2017;11:24-30.
3. Geiger J, Epelman M, Darge K. The fountain sign. *J Ultrasound Med.* 2010;29:1233-7.