ACTA RADIOLÓGICA PORTUGUESA
January-April 2028 | Vol 40 nº 1 | e45631 https://doi.org/10.25748/arp.45631

Images of Interest / Imagens de Interesse

Primary Pulmonary MALT Lymphoma: An Atypical Presentation

Linfoma MALT Pulmonar Primário: Uma Apresentação Atípica

João R. Monteiro[1], Helena Martins Gomes[1], Marta Vaz Dias[1], Catarina Gonçalves[1], Chantal Albuquerque[1], António Almeida[1]

[1]Serviço de Imagiologia, ULS de Viseu Dão-Lafões, Viseu, Portugal

Address

João R. Monteiro
Serviço de Imagiologia
ULS de Viseu Dão-Lafões
Av. Rei Dom Duarte
3504-509 Viseu, Portugal
e-mail: joaoprmonteiro@hotmail.com

Received: 22/02/2026
Accepted: 11/05/2026
Published: 03/07/2026

Abstract

Primary pulmonary lymphomas are rare neoplastic diseases consisting of abnormal proliferation of lymphoid cells affecting the lungs without detectable extrapulmonary involvement. Patients can be asymptomatic or have nonspecific symptoms such as fever, cough, dyspnea or chest pain.
The imaging features of primary pulmonary lymphomas are also nonspecific and variable. Common findings include multiple airspace opacities with or without air bronchograms. Due to the low specificity and incidence of this disease, a multidisciplinary approach is often necessary for the diagnosis, integrating clinical, radiological, histological and immunohistochemical findings.
We report a case of an asymptomatic patient with an incidentally detected pulmonary mucosa-associated lymphoid tissue (MALT) lymphoma, a subtype of primary pulmonary lymphoma, whose imaging findings consisted of airspace opacities and several pulmonary cysts, an atypical presentation of a rare disease.

Keywords

Lymphoma; B-Cell; Marginal zone; Cysts; Lung diseases; Case reports.

Resumo

Os linfomas pulmonares primários são doenças neoplásicas raras que consistem na proliferação anormal de células linfoides que afeta os pulmões sem envolvimento extrapulmonar detetável. Os doentes podem estar assintomáticos ou apresentar sintomas inespecíficos tais como febre, tosse, dispneia ou dor torácica.
As características imagiológicas dos linfomas pulmonares primários são também inespecíficas e variáveis. Os achados mais comuns incluem múltiplas opacidades pulmonares com ou sem broncograma aéreo. Devido à reduzida especificidade e incidência desta doença, uma abordagem multidisciplinar é frequentemente necessária para o diagnóstico, integrando os achados clínicos, radiológicos, histológicos e imunohistoquímicos.
Relatamos um caso de um doente assintomático com um linfoma do tecido linfoide associado à mucosa (MALT) pulmonar, um subtipo de linfoma pulmonar primário, detetado incidentalmente, cujos achados imagiológicos consistiam em opacidades alveolares e vários quistos pulmonares, uma apresentação atípica de uma doença rara.

Palavras-chave

Linfoma; Célula B; Zona marginal; Quistos; Doenças pulmonares; Relatos de caso.

Case Presentation

An asymptomatic 81-year-old male with a history of hypertension and chronic liver disease was referred for pulmonology consultation after a left lower lobe consolidation was incidentally detected on abdominal computed tomography (CT). After a course of antibiotics, a follow-up thoracic CT revealed a large left lower lobe consolidation, a smaller consolidation in the middle lobe and several scattered pulmonary cysts in both lungs (Figure 1).
CT-guided transthoracic biopsy was performed. Histology demonstrated lung tissue extensively infiltrated by small lymphoid cells with irregular nuclei, dense chromatin and pale cytoplasm, with a low mitotic index. Immunohistochemistry showed a CD20 and BCL-2 positive B-cell population negative for CD5, CD10, CD23 and cyclin D1, with a low proliferative index (Ki-67 <5%). Cytokeratin staining highlighted lymphoepithelial lesions. The findings supported a diagnosis of mucosa-associated lymphoid tissue (MALT) lymphoma.
The patient was subsequently referred to hematology-oncology. A CT of the neck, thorax, abdomen and pelvis obtained three months after the initial thoracic CT demonstrated similar pulmonary findings and revealed no lymphadenopathy in any region (Figure 2).
A confident diagnosis of primary pulmonary MALT lymphoma was established. Patient management was discussed at a multidisciplinary team meeting and monotherapy with rituximab was initiated.

Discussion

Pulmonary lymphoproliferative disorders are rare diseases characterized by abnormal proliferation of lymphoid cells.[1] Primary pulmonary lymphomas, a malignant form of these disorders, account for only 0.5% of all primary pulmonary malignancies and less than 1% of all non-Hodgkin lymphomas.[2] They are defined by monoclonal B-cell proliferation without detectable extrathoracic involvement for at least three months after diagnosis.[1,2] The most common

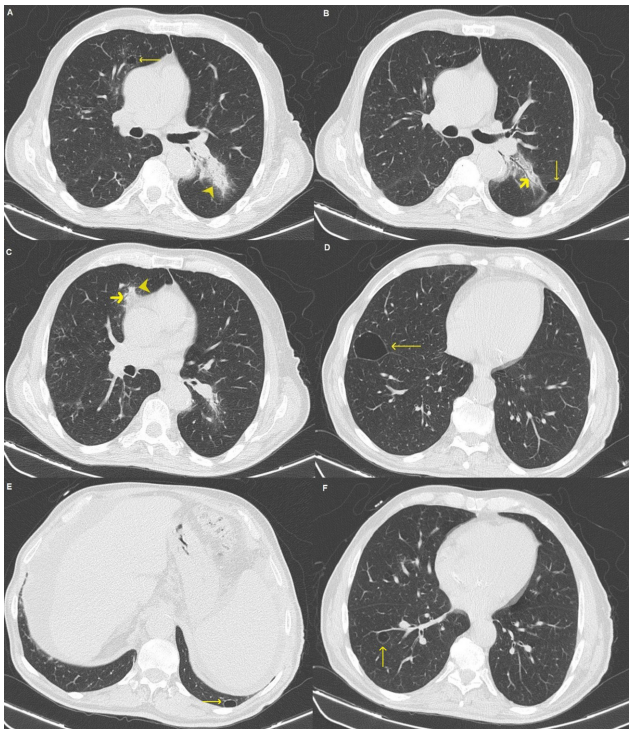

Figure 1 – Axial chest CT images demonstrate bilateral parenchymal consolidations and several pulmonary cysts. (A, B) Dominant consolidation in the left lower lobe (arrowhead) with an associated air bronchogram (short arrow). (C) Smaller consolidation in the right middle lobe (arrowhead) with an air bronchogram (short arrow). (A–F) Several pulmonary cysts of variable size are present throughout both lungs (long arrows).

subtype is pulmonary MALT lymphoma, a marginal-zone lymphoma comprising approximately 80% of cases.[2]

Pulmonary MALT lymphomas are usually asymptomatic and detected incidentally. Most cases are indolent and have a favorable prognosis.[1] When present, symptoms may include cough, dyspnea, fever, hemoptysis and chest pain.

The imaging findings of pulmonary MALT lymphomas are nonspecific. CT reveals, more frequently, consolidations, nodules or masses, often containing air bronchograms due to preservation of bronchial lumina within the lesions.[3,4] Lesions are commonly bilateral and multiple, without clear lobar predominance. Additional findings such as ground-glass opacities, micronodules or septal thickening may also be present.[3] Pulmonary cysts have been reported in a minority of cases (approximately 6%) and may be associated with light-chain deposition or amyloid involvement.[3,4] Cavitary lesions are even less frequent and may raise suspicion for a higher-grade lymphoma.[4] Hilar or mediastinal lymphadenopathy is identified in a small proportion of patients and is typically of limited size, while pleural effusion is uncommon.[4]

The differential diagnosis of pulmonary MALT lymphoma is broad, particularly given its nonspecific imaging features. Chronic alveolar opacities may mimic infectious processes (including indolent bacterial pneumonia or tuberculosis),

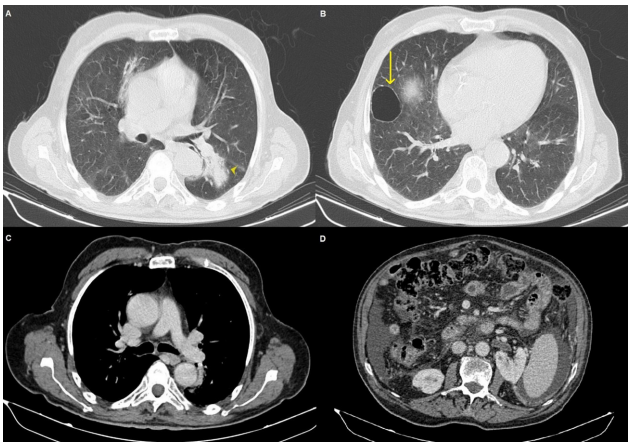

Figure 2 – Axial CT images obtained three months later demonstrate persistent pulmonary abnormalities without significant interval change. (A, B) Areas of consolidation (arrowhead) associated with pulmonary cysts (long arrow). (C) No mediastinal lymphadenopathy is identified. (D) No abdominal lymphadenopathy is seen; a small volume of ascites is present. The absence of nodal or other extrapulmonary lymphomatous involvement supports the diagnosis of primary pulmonary lymphoma.

organizing pneumonia or pulmonary infarction.[4] Neoplastic entities such as lung adenocarcinoma should also be considered.[4] In cases with cystic changes, the main differential diagnosis includes lymphocytic interstitial pneumonia (LIP), which is characteristically cyst-predominant and often associated with ground-glass opacities, whereas pulmonary lymphoma more commonly presents with consolidations and nodules.[1] Distinction from these entities relies on clinical and radiological correlation and, ultimately, histopathological and immunohistochemical analysis.

Treatment of pulmonary MALT lymphomas may involve chemotherapy, immunotherapy with an anti-CD20 agent such as rituximab or a combination of both. Due to the low incidence of the disease, prospective studies are limited and treatment protocols are largely based on retrospective analyses and expert opinion.

In retrospect, the patient exhibited some characteristic features of pulmonary MALT lymphomas, including an asymptomatic course and, incidentally, peribronchovascular pulmonary opacities were detected. However, these findings are nonspecific and may be seen in a variety of other conditions. The presence of several pulmonary cysts represents an atypical radiological pattern and contributed to the diagnostic challenge.

In conclusion, pulmonary MALT lymphomas are rare lymphoproliferative disorders that often present with nonspecific or atypical imaging features. When cystic changes coexist with consolidations, the diagnosis may be particularly challenging. Definitive diagnosis requires histopathological and immunohistochemical analysis of tissue samples. A multidisciplinary approach is recommended for management and patients generally have a favorable prognosis.

Ethical Disclosures / Divulgações Éticas

Conflicts of interest: The authors have no conflicts of interest to declare.

Conflitos de interesse: Os autores declaram não possuir conflitos de interesse.

Financing Support: This work has not received any contribution, grant or scholarship.

Suporte financeiro: O presente trabalho não foi suportado por nenhum subsídio ou bolsa.

Confidentiality of data: The authors declare that they have followed the protocols of their work center on the publication of data from patients.

Confidencialidade dos dados: Os autores declaram ter seguido os protocolos do seu centro de trabalho acerca da publicação dos dados de doentes.

Protection of human and animal subjects: The authors declare that the procedures followed were in accordance with the regulations of the relevant clinical research ethics committee and with those of the Code of Ethics of the World Medical Association (Declaration of Helsinki).

Protecção de pessoas e animais: Os autores declaram que os procedimentos seguidos estavam de acordo com os regulamentos estabelecidos pelos responsáveis da Comissão de Investigação Clínica e Ética e de acordo com a Declaração de Helsínquia da Associação Médica Mundial.

References

1. Hare SS, Souza CA, Bain G, Seely JM, Frcpc, Gomes MM, et al. The radiological spectrum of pulmonary lymphoproliferative disease. Br J Radiol. 2012;85:848-64.
2. Cadranel J, Wislez M, Antoine M. Primary pulmonary lymphoma. Eur Respir J. 2002;20:750-62.
3. Deng W, Wan Y, Yu JQ. Pulmonary MALT lymphoma has variable features on CT. Sci Rep. 2019;9:8657.
4. Borie R, Wislez M, Antoine M, Copie-Bergman C, Thieblemont C, Cadranel J. Pulmonary mucosa-associated lymphoid tissue lymphoma revisited. Eur Respir J. 2016;47:1244-60.