

ARTIGO ORIGINAL

Epidural Analgesia in the Surgical Correction of Pediatric Scoliosis

Analgésia Epidural em Cirurgia de Escoliose em Idade Pediátrica

Sónia Nóbrega^{1*}, Ana Ferreira², Sara Ramos¹

Afilições

¹Centro Hospitalar Universitário de Lisboa Central, Lisboa, Portugal.

²Hospital de Vila Franca de Xira, Vila Franca de Xira, Portugal.

Keywords

Analgesia, Epidural; Child; Pain Management; Pain, Postoperative/therapy; Scoliosis/surgery

Palavras-chave

Analgesia Epidural; Criança; Dor Pós-Operatória/tratamento; Escoliose/cirurgia; Gestão da Dor

ABSTRACT

Introduction: Pediatric scoliosis surgery aims at stopping the progression of the disease and improving quality of life, however it is associated with a severely painful postoperative period.

In 2016, we implemented a clinical protocol with postoperative continuous epidural analgesia, by one or two epidural catheters placed by the surgeon at the end of surgery. The aim of our study was to evaluate the analgesic effectiveness of the epidural protocol up to 72 hours after surgery, the incidence of adverse events and the length of Intensive Care Unit (ICU) stay.

Methods: A retrospective analysis was performed by consulting the patients' clinical files, comparing two groups: Alfentanil group (AG) - 25 patients with systemic opioid analgesia through an alfentanil intravenous infusion - and Epidural group (EG) - 21 patients with epidural ropivacaine and morphine infusion. Data were analyzed using SPSS®, using Nonparametric Mann-Whitney test, Fisher's exact test and Spearman's correlation coefficient. A level of significance $\alpha=0.05$ was considered.

Results: The mean pain scores (0-10 numeric rating scale) of the EG were statistically lower at immediate postoperative (-3), 24 hours (-5) and 48 hours (-4) after surgery ($p<0.001$), as were the needs for rescue analgesia ($p<0.001$). There were fewer adverse events in the EG, not reaching statistical significance. ICU length of stay was statistically shorter with epidural analgesia ($p<0.001$).

Conclusion: Epidural analgesia is an effective alternative to systemic opioid analgesia for pediatric scoliosis surgery. Prospective randomized studies are needed to confirm these results.

RESUMO

Introdução: A cirurgia de escoliose pediátrica, que visa interromper a progressão da doença e melhorar a qualidade de vida, está associada a dor pós-operatória intensa. Em 2016, implementámos a analgesia epidural no período pós-operatório, através de um ou dois cateteres epidurais, colocados pelo cirurgião no final da cirurgia. Os objetivos deste estudo foram avaliar a eficácia analgésica até 72 horas após a cirurgia, a incidência de eventos adversos e o tempo de permanência na Unidade de Cuidados Intensivos (UCI).

Material e Métodos: Foi realizada uma análise retrospectiva comparando dois grupos: Grupo Alfentanil (AG) - 25 doentes com analgesia sistémica por perfusão endovenosa de alfentanil - e Grupo Epidural (EG) - 21 doentes com perfusão de ropivacaína e morfina via epidural. Os dados foram analisados através do SPSS®, utilizando o teste não paramétrico de Mann-Whitney, o teste exato de Fisher e o coeficiente de correlação de Spearman (nível de significância considerado $\alpha = 0,05$).

Resultados: Os *scores* de dor (escala numérica 0-10) foram inferiores no EG, no pós-operatório imediato (-3), 24 horas (-5) e 48 horas (-4) após a cirurgia ($p<0,001$). As necessidades de analgesia de resgate foram inferiores no EG ($p<0,001$). Houve menor incidência de eventos adversos no EG, não atingindo significância estatística. O tempo de internamento na UCI foi inferior no EG ($p<0,001$).

Resultados: A analgesia epidural é uma alternativa eficaz na cirurgia de escoliose pediátrica. São necessários estudos prospectivos randomizados para confirmar estes resultados.

Autor Correspondente/Corresponding Author*:

Sónia Dória Nóbrega

Morada: Rua Jacinta Marto 8A, 1169-045, Lisboa, Portugal.

E-mail: soniadorianobrega@gmail.com

INTRODUCTION

Scoliosis is a disease characterized by a change in the normal curvature of the spine, causing a deformity. The most common etiology of scoliosis in pediatric age is idiopathic, accounting for 70% - 80% of all cases. In a smaller number of patients, scoliosis may have other causes, namely congenital, neurological or musculoskeletal diseases.^{1,2}

Pediatric scoliosis surgery aims at stopping the progression of the disease, preventing cardiorespiratory complications and improving quality of life and physical appearance.³⁻⁵ Scoliosis correction surgery assumes posterior spinal instrumentation through a large midline incision, and in some cases thoracotomies to correct rib deformities. This highly invasive orthopedic surgery is associated with a severely painful postoperative period, with high pain scores up to 72 hours after surgery.⁶

Postoperative epidural analgesia by the placement of two epidural catheters at the end of surgery by the surgeon demonstrated good pain control with fewer side effects and greater patient satisfaction when compared with an intravenous opioid.^{7,29}

Up to 2015 the patients who underwent scoliosis surgery at our hospital had postoperative analgesia by a multimodal intravenous analgesic regimen based on systemic opioid infusion with alfentanil, associated with adjuvant drugs, as per the ICU protocol: alfentanil infusion (2-4 mcg/kg/h), acetaminophen 15 mg/kg (max. 1 g) every 6h, dipyrrone 40 mg/kg (max. 2 g) every 8 hours and ketorolac 1 mg/kg (max. 30 mg) PRN every 8 hours for 48 hours.

In January 2016, guided by a need to improve the subjectively insufficient postoperative analgesia for scoliosis surgery, we implemented a multidisciplinary protocol with postoperative epidural infusion of local anesthetic and opioid through one or two epidural catheters placed by the surgeon at the end of surgery. We describe our protocol below:

All patients (both before and after implementation of the scoliosis epidural protocol) were orally pre-medicated as per our institution's protocol: for children weighing 10 kg to 40 kg, 0.2-0.3 mL/kg (max. 6 mL) of a mixture of midazolam and droperidol syrup (at a concentration of midazolam 1.5 mg/mL and droperidol 0.125 mg/mL); for children over 40 kg, midazolam 0.25 mg/kg (7.5 mg/15 mg midazolam tablet), forty minutes before arriving at the operating room.

Scoliosis epidural protocol:

Standard ASA monitoring plus BIS® and peripheral venous access was obtained.

The anesthesia induction was performed with remifentanil and propofol plus a single intubation dose of rocuronium 0,6 mg/kg for endotracheal intubation.

Single, double or triple prophylaxis for post-operative nausea and vomiting was given, depending on child risk factors

(dexamethasone 0.15 mg/kg (max. 4 mg) at the induction, ondansetron 0.1 mg/kg (max. 4 mg) and droperidol 0.015 mg/kg (max. 1.25 mg) 30 minutes before the end of surgery.

Prophylactic antibiotic was administered with cefazolin 40 mg/kg (max. 2 g).

After induction, an arterial line, a central line and a urinary catheter were placed. Anesthesia was maintained with remifentanil and propofol infusions, neuromuscular block was monitored and reversed as needed, to allow for intraoperative somatosensory and motor evoked potentials to be monitored with minimal interference. The surgical team was the same and no major changes in surgical strategy were introduced during the study period. Surgery was performed with a posterior only approach, involving bilateral pedicle screw insertion on each vertebral level of the fusion area.

At the end of the scoliosis correction, before wound closure, two epidural catheters were inserted by the surgeon, under direct vision, at the middle level of the surgical wound (usually T9-T11): one cephalad and one caudal, advancing 5 cm into the epidural space. If the instrumented area was less than 6 dermatomes, only one cephalad catheter was inserted, at the middle level of the incision. The scrub nurse aspirated both catheters, confirming that neither blood nor cerebrospinal fluid was present in either of them. An initial epidural bolus of ropivacaine 0.2% (0.1% for patients weighing less than 10 kg) plus morphine was administered (half of the total volume in each catheter, if two catheters were inserted), immediately after their placement, to make time for the blockade to settle before the child is awakened and extubated.

The initial bolus was calculated based on the following formulas:

- ropivacaine 0.2% (0.1% if < 10 kg), in milliliters:
 - < 15 years: $(\text{age (in years)} + 2) / 10$, multiplied by the number of instrumented dermatomes;
 - > 15 years (and > 50 kg): 1 mL per thoracic dermatome plus 2 mL per lumbar dermatome;
- morphine 40 mcg/kg of a 1 mg/mL preparation, added to the ropivacaine.

Intraoperative intravenous analgesia also included: acetaminophen 20 mg/kg during surgery (maximum 1 g); ketorolac 0.5 mg/kg (maximum 30 mg) and pethidine 1 mg/kg at wound closure.

At the end of the procedure the patient was extubated and taken into the Intensive Care Unit (ICU).

A postoperative multimodal analgesia regimen was prescribed with: acetaminophen 20 mg/kg (max. 1 g) every 8 hours, ketorolac 0.5 mg/kg (max. 30 mg) every 8 hours, dipyrrone 20 mg/kg (max. 1 g) every 8 hours PRN and a continuous infusion of ropivacaine 0.2% (0.1% if < 10 kg) with morphine 40 mcg/kg/day. For the infusion rate, the total volume (in milliliters) of hourly infusion was calculated with the formula: 0.2 – 0.4 mg/kg/h.

The volume of hourly infusion was equally divided in both catheters. The epidural analgesia was maintained for 72 hours.

PONV prophylaxis with ondansetron 0.1 mg/kg (max. 4 mg) every 8 hours and droperidol 0.015 mg/kg (max. 0.625 mg) PRN every 8 hours for PONV treatment were prescribed for the duration of the epidural analgesia.

The aims of our retrospective study were to evaluate the protocol's analgesic effectiveness in decreasing pain scores up to 72 hours after surgery, and to quantify the incidence of side effects (bradypnea, excessive sedation, postoperative nausea and vomiting (PONV), pruritus and the occurrence of paresthesia or motor weakness) and length of Intensive Care Unit (ICU) stay both before and after the implementation of the scoliosis epidural protocol.

METHODS

After approval by our Institution's Ethics Committee, a total of 79 clinical files of patients of pediatric age (under 18 years) undergoing elective scoliosis correction surgery with instrumentation of at least 4 levels were consulted: 37 patients who received epidural analgesia, as per the scoliosis epidural protocol, during the year 2016 ("epidural group" - EG); and 42 patients who received systemic opioid analgesia with alfentanil infusion, as per the ICU protocol, during the years 2012 to 2014 ("Alfentanil group" - AG).

In both groups, intraoperative Anesthesia charts and nurse records and ICU clinical diaries and nurse records were consulted.

The resting pain scores using the numerical rating scale (0 = no pain, 10 = worst pain) were evaluated and registered by the ICU nurses at immediate postoperative, 24 hours, 48 hours and 72 hours after surgery. Clinical files were also consulted regarding the need for rescue analgesia administration and the occurrence of side effects, such as: bradypnea, excessive sedation, postoperative nausea and vomiting (PONV), pruritus and the occurrence of paresthesia or motor weakness. These side effects were assumed to have occurred when registered as such by the ICU, Orthopedic or Anesthesia staff.

The ICU length of stay (in days) was also recorded.

Exclusion criteria from the study were: analgesia protocol other than the ICU alfentanil protocol or the implemented scoliosis epidural protocol; patients who remained ventilated in the postoperative period and were thus unable to set a pain score; reintervention procedures and charts with insufficient data. Excluded patients are shown in Fig. 1.

Statistical Analysis

IBM SPSS Statistics version 22.0.0.1 (IBM Corp., Armonk, NY) was used for statistical analysis and a significance value of 0.05 was considered in all statistic tests. Kolmogorow-

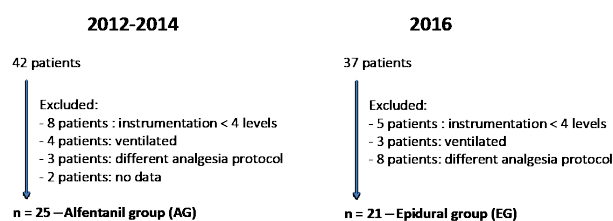


Figure 1. Flow diagram of excluded patients

Smirnow test was used to test normality of distribution. Continuous variables were reported using mean, minimal and maximal values and analyzed using Student's t-test, Mann Whitney U test and Spearman's correlation coefficient, as appropriate. Categorical variables were expressed in frequencies and tested for significance using the χ^2 test or the Fisher's exact test.

RESULTS

The cohort included 46 patients: 25 patients in the AG and 21 patients in the EG.

The patients were aged 5 to 17 years and weighted 14 to 89 kg. There was a predominance of the male gender in both groups. Four scoliosis etiologies were considered: idiopathic (n=17), neuromuscular (n=8), syndromic (n=6) and other etiologies (n=2, tumor and infectious). The etiology of scoliosis is presented in Table 1.

Table 1. Patients characteristics. AG- Alfentanil Group; EG- Epidural Group

	AG (n= 25)	EG (n= 21)	p-value
Age median - years (min.-max.)	15 (6-17)	14 (5-17)	0,367
Gender M/F	22/3	17/4	0,686
Etiology			
Idiopathic	13	17	0,211
Neuromuscular	6	2	
Syndromic	4	2	
Other (infection and tumor)	2	-	

No significant differences were found in age, weight and etiology of scoliosis between groups.

The EG included 17 patients in whom two epidural catheters were placed and 4 in whom only one epidural catheter was placed, as the number of instrumented levels was inferior to six.

The mean pain scores after the procedure were significantly lower in the EG comparing to the AG both in the immediate postoperative period (EG 0 vs AG 3, $p < 0.001$) as at 24 hours (EG 0 vs AG 5, $p < 0.001$) and 48 hours after surgery (EG 0 vs AG 4, $p < 0.001$). Fig. 2.

Unfortunately the data we could gather for 72 hours after surgery was inconsistent and for that reason we decided not to analyze the data.

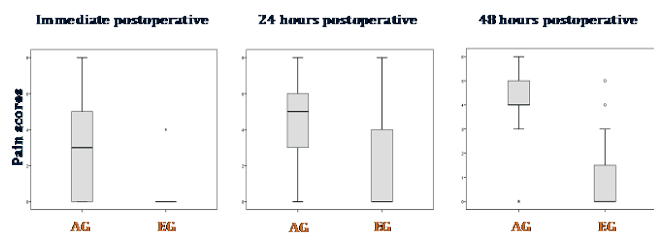


Figure 2. Mean resting pain scores in the immediate postoperative period, 24 hours and 48 hours after surgery. AG- Alfentanil Group; EG- Epidural Group.

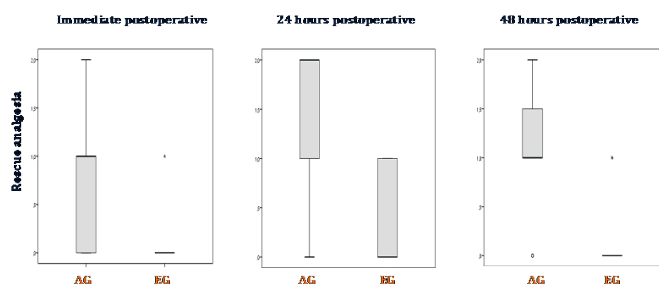


Figure 3. Rescue analgesia administered (number of administrations) was recorded at immediate postoperative, 24 hours and 48 hours after surgery. AG- Alfentanil Group, EG- Epidural Group.

Table 2. Number of administrations of rescue analgesia per group at each time period

		Number of rescue analgesia administrations		
		0	1	2
Immediate Postoperative Period	AG	12	10	3
	EG	20	1	0
24 hours after surgery	AG	5	5	15
	EG	14	7	0
48 hours after surgery	AG	4	15	6
	EG	19	2	0

The administration of rescue analgesia in the epidural group was also significantly less needed at immediate postoperative, 24 hours and 48 hours after surgery ($p < 0.05$). Fig. 3 and Table 2. The average time of epidural analgesia was approximately 4 days.

When it comes to the side effects, postoperative nausea and vomiting was more frequent in the alfentanil group (28% vs 9.5%), although it was not statistically significant. Pruritus was more frequent in the epidural group (14.3% vs 4.0%) but also with no statistical difference. There was one case of paraesthesia in the epidural group, which resolved with epidural infusion rate reduction. In the alfentanil group there were four cases of excessive sedation and two of bradypnea (versus 0 in the epidural group). Table 3 summarizes the postoperative side effects in both groups.

Table 3. Postoperative side effects

Side effects	AG		EG		p-value
	n	%	n	%	
Bradypnea	2	8%	0	0%	0,493
Excessive sedation	4	16%	0	0%	0,114
PONV	7	28%	2	9,5%	0,151
Pruritus	1	4%	3	14,3%	0,318
Paresthesia	0	0%	1	4,8%	0,457

AG- Alfentanil group; EG- Epidural Group;
 PONV- Postoperative nausea and vomiting;
 AG- Alfentanil Group; EG- Epidural Group.

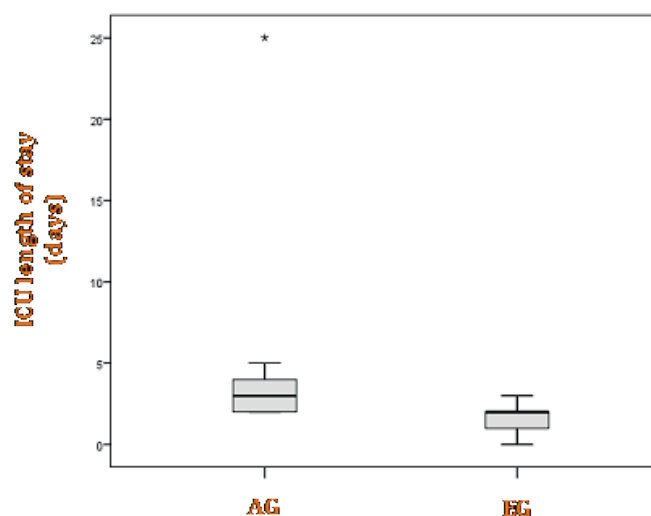


Figure 4. Intensive Care Unit (ICU) length of stay was significantly shorter in EG. AG- Alfentanil Group; EG- Epidural Group.

ICU length of stay in the AG was 3 days and it was significantly shorter in the epidural group with 2 days ($p < 0.001$) – Fig. 4. All patients having epidural analgesia were able to perform a basic neurologic assessment by the orthopedic team on awakening. There were no immediate or late complications of the epidural technique, up to 3 years follow up, namely inadvertent intravenous or intra-tecal administration of local anesthetic/morphine, surgical site infection, epidural abscess or epidural hematoma.

DISCUSSION

Spinal instrumentation surgery for scoliosis correction is associated with high levels of postoperative pain, being performed especially at pediatric age. Several analgesic techniques have been described over the last few years aiming to achieve an ideal method that provides effective pain control with minimal side effects. Classically, in the postoperative period of our Intensive Care Unit an intravenous alfentanil perfusion was given, as it is the most widely handled drug in the Unit and the one they are most comfortable with. The perception that patients had unsatisfactory analgesia made us review the literature for a more effective analgesic regimen. Klatt *et al*⁸ undertook a randomized prospective trial

comparing 3 techniques of postoperative pain management after posterior spinal instrumentation and fusion: intravenous patient controlled analgesia, single and dual continuous epidural analgesia. Sixty six patients were randomized into those 3 groups. Pain intensity was most effectively controlled with a double continuous epidural analgesia when compared with patient controlled analgesia ($p < 0.05$) and a single continuous epidural analgesia ($p < 0.05$). One of the disadvantages of analgesia with only one epidural catheter is the difficulty in covering the entire posterior surgical incision area, and higher levels of pain in the cephalic and caudal extremities have been documented.⁹ This would be overcome by placing two catheters, one cephalad and one caudal, allowing for a greater extent of analgesia with reduced doses and analgesic concentrations. This has supported the elaboration of our institutional protocol with epidural analgesia through two catheters, one cephalad and one caudal, both placed at the middle level of the surgical incision. The choice of using ropivacaine as a local anesthetic was based on the existing literature with excellent analgesic results and low incidence of side effects.^{7,9,10} The concentration of 2 mg/mL (0.2% ropivacaine) was intended to have less toxicity and less motor blockade, since the latter may be a surgical complication that should be investigated early on. Although some literature states fewer side effects with epidural analgesia with local anesthetic alone,¹¹⁻¹³ we decided to associate morphine to the epidural perfusion because it improves blockade quality and spread, as it is a hydrophilic drug.

As Borgeat *et al*⁹ documented, comparing to the group receiving continuous intravenous opioid, the epidural group had significantly lower pain scores at all evaluation times (immediate postoperative, 24 hours and 48 hours after surgery) and thus, required less rescue analgesia.

Although the alfentanil group had more side effects than the epidural group, we did not find statistical significance and this may be due to the small sample.

Regarding the length of stay in the Intensive Care Unit, this was significantly shorter in the epidural group. Despite the existence of other factors that can influence this and that we could not control, it can be likely related to better pain control, the possibility of earlier child / adolescent collaboration and, consequently, faster functional recovery.

In accordance with our results, a recent Cochrane systematic review comparing postoperative epidural analgesia versus systemic analgesia for thoracolumbar spine surgery in children concludes that there may be an additional reduction in pain up to 72 hours after surgery with epidural analgesia compared to systemic analgesia. Additionally, children were more satisfied with epidural analgesia than with systemic analgesia. Although our institution's results up to this day lead us to believe that the epidural analgesia in spinal surgery

in children is a safe alternative to systemic opioid analgesia, they conclude that due to the very low quality of evidence available it is still uncertain whether this technique is safe for children undergoing spine surgery.¹⁴

Since although very rare the neuraxial approach to analgesia may be associated with very serious complications,¹⁴ different analgesia protocols other than epidural analgesia, have been studied and pointed out in the literature for pediatric scoliosis surgery. We highlight the use of intrathecal morphine^{6,15,16} and the administration of adjuvants such as gabapentin,^{17,18} ketamine,¹⁹ dexmedetomidine and also the subcutaneous bupivacaine pump.²⁰ Although there is insufficient data to support the use of these alternatives/adjuvants in pediatric spine surgery, these are areas worth studying and could be promising for the future.

The retrospective nature of our study poses some limitations. First of all, data collection is limited to the records made on intraoperative anesthesia charts and in the ICU medical and nursing records, allowing us to compare fewer variables than those we would like, namely: pain in motion, early mobilization, bowel recovery and health professionals, children / adolescents and parents satisfaction.

We believe that another limitation may be the time difference between the alfentanil group and the epidural group. Despite being the same surgical team throughout the four years, the experience acquired in this period and the technical evolution is inevitable.

The fact that the patient sample is small makes it difficult to extrapolate the results for the general population.

Finally, another of the limitations we point out is that the assessment of pediatric pain is always difficult, although our sample mainly includes children of verbal age and adolescents, and therefore more collaborative.

CONCLUSION

In summary, the protocol implemented with dual epidural catheter analgesia was effective in reducing the pain scores in the first 48 hours of postoperative period, without increased adverse events or side effects, comparing to alfentanil analgesia. Moreover, the implementation of the protocol made it possible to reduce ICU length of stay significantly. The use of institutional protocols allows the standardization of approaches and improves care, minimizing errors. Further prospective studies with larger samples and longer follow up times are needed to confirm our results.

ACKNOWLEDGEMENTS

The authors acknowledge Daniel Virella and Marta Alves from the Investigation Centre of Centro Hospitalar Universitário de Lisboa Central for the assistance with study design and statistical analysis.

Ethical Disclosures

Conflicts of Interest: The authors have no conflicts of interest to declare.

Financing Support: This work has not received any contribution, grant or scholarship.

Confidentiality of Data: The authors declare that they have followed the protocols of their work center on the publication of data from patients.

Protection of Human and Animal Subjects: The authors declare that the procedures followed were in accordance with the regulations of the relevant clinical research ethics committee and with those of the Code of Ethics of the World Medical Association (Declaration of Helsinki).

Provenance and Peer Review: Not commissioned; externally peer reviewed.

Responsabilidades Éticas

Conflitos de Interesse: Os autores declaram a inexistência de conflitos de interesse na realização do presente trabalho.

Fontes de Financiamento: Não existiram fontes externas de financiamento para a realização deste artigo.


Confidencialidade dos Dados: Os autores declaram ter seguido os protocolos da sua instituição acerca da publicação dos dados de doentes.

Proteção de Pessoas e Animais: Os autores declaram que os procedimentos seguidos estavam de acordo com os regulamentos estabelecidos pelos responsáveis da Comissão de Investigação Clínica e Ética e de acordo com a Declaração de Helsínquia da Associação Médica Mundial.

Proveniência e Revisão por Pares: Não comissionado; revisão externa por pares.

ORCID

Sónia Nóbrega  <https://orcid.org/0000-0003-4028-0417>

Ana Ferreira  <https://orcid.org/0000-0003-1575-3470>

Sara Ramos  <https://orcid.org/0000-0001-5717-5467>

Received: 06th of December, 2019 | Submissão: 06 de dezembro, 2019

Accepted: 02nd of March, 2020 | Aceitação: 02 de março, 2020

Published: 31st of March, 2020 | Publicado: 31 de março, 2020

© Autor (es) (ou seu (s) empregador (es)) 2019. Reutilização permitida de acordo com CC BY-NC. Nenhuma reutilização comercial.

© Author(s) (or their employer(s)) 2019. Re-use permitted under CC BY-NC. No commercial re-use.

REFERENCES

- McNicol ED, Tzortzopoulou A, Schumann R, Carr DB, Kalra A. Antifibrinolytic agents for reducing blood loss in scoliosis surgery in children. *Cochrane Database Syst Rev.* 2016;9:CD006883. doi: 10.1002/14651858.CD006883.pub3.
- Negrini S, Minozzi S, Bettany-Saltikov J, Chockalingam N, Grivas TB, Kotwicki T, et al. Braces for idiopathic scoliosis in adolescents. *Cochrane Database Syst Rev.* 2015;6:CD006850. doi: 10.1002/14651858.CD006850.pub3.
- Mo F, Cunningham ME. Pediatric scoliosis. *Curr Rev Musculoskelet Med.* 2011;4:175–82.
- Cheng JC, Castelein RM, Chu WC, Danielsson AJ, Dobbs MB, Grivas TB, et al. Adolescent idiopathic scoliosis. *Nat Rev Dis Prim.* 2015;1:15030.
- Aillon T, Sure DR, Smith JS, Shaffrey CI. Surgical considerations for major deformity correction spine surgery. *Best Pract Res Clin Anaesthesiol.* 2016;30:3–11. doi: 10.1016/j.bpa.2015.11.005.
- Hong R, Gibbons K, Li G, Holman A, Voepel-Lewis T. A retrospective comparison of intrathecal morphine and epidural hydromorphone for analgesia following posterior spinal fusion in adolescents with idiopathic scoliosis. *Paediatr Anaesth.* 2017;27:91–7. doi: 10.1111/pan.13037.
- Blumenthal S, Min K, Nadig M, Borgeat A. Double epidural catheter with ropivacaine versus intravenous morphine: A comparison for postoperative analgesia after scoliosis correction surgery. *Anesthesiology.* 2005;102:175–80.
- Klatt J, Mickelson J, Hung M, Durcan S, Miller C, Smith J. A randomized prospective evaluation of 3 techniques of postoperative pain management after posterior spinal instrumentation and fusion. *Spine.* 2013;38:1626–31. doi: 10.1097/BRS.0b013e31829cab0b.
- Borgeat A, Blumenthal S. Postoperative pain management following scoliosis surgery. *Curr Opin in Anaesthesiol.* 2008;21:313–6.
- Tobias J, Gaines R, Lowry K, Kittle D, Bildner C. A dual epidural catheter technique to provide analgesia following posterior spinal fusion for scoliosis in children and adolescents. *Paediatr Anaesth.* 2001;11:199–203.
- Moriarty A. Postoperative extradural infusions in children: preliminary data from a comparison of bupivacaine/diamorphine with plain ropivacaine. *Paediatr Anaesth.* 1999;9:423–7.
- Jorgensen H, Fomsgaard J, Dirks J, Wetterslev J, Andreasson B, Dahl J. Effect of epidural bupivacaine vs. combined epidural bupivacaine and morphine on gastrointestinal function and pain after major gynaecological surgery. *Br J Anaesth.* 2001;87:727–32.
- Jorgensen H, Fomsgaard JS, Dirks J, Wetterslev J, Andreasson B, Dahl JB. Effect of peri and postoperative epidural anaesthesia on pain and gastrointestinal function after abdominal hysterectomy. *Br J Anaesth.* 2001;87:577–83.

- Guay J, Suresh S, Kopp S, Johnson RL. Postoperative epidural analgesia versus systemic analgesia for thoraco-lumbar spine surgery in children. *Cochrane Database Syst Rev.* 2019;1:CD012819. doi: 10.1002/14651858.CD012819.pub2
 - Li Y, Hong R, Robbins C, Gibbons K, Holman A, Caird M, et al. Intrathecal morphine and oral analgesics provide safe and effective pain control after posterior spinal fusion for adolescent idiopathic scoliosis. *Spine.* 2018;43:E98–104. doi: 10.1097/BRS.0000000000002245.
 - lbach B, Loeber C, Shukry M, Hagemann T, Harrison D, Johnson P. Duration of intrathecal morphine effect in children with idiopathic scoliosis undergoing posterior spinal fusion. *J Opioid Manag.* 2015;11:295–303. doi: 10.5055/jom.2015.0278.
 - Trzcinski S, Rosenberg R, Vasquez Montes D, Sure A, Zhou P, Tishelman J, et al. Use of gabapentin in posterior spinal fusion is associated with decreased postoperative pain and opioid use in children and adolescents. *Clin Spine Surg.* 2019;32:210–4. doi: 10.1097/BSD.0000000000000783.
 - Rusy L, Hainsworth K, Nelson T, Czamecki M, Tassone J, Thometz J, et al. Gabapentin use in pediatric spinal fusion patients: a randomized, double-blind, controlled trial. *Anesth Analg.* 2010;110:1393–8.
 - Pestieau S, Finkel J, Junqueira M, Cheng Y, Lovejoy J, Wang J, et al. Prolonged perioperative infusion of low-dose ketamine does not alter opioid use after pediatric scoliosis surgery. *Paediatr Anaesth.* 2014;24:582–90. doi: 10.1111/pan.12417.
 - Wade Shrader M, Nabar S, Jones J, Falk M, Cotugno R, White G, et al. Adjunctive pain control methods lower narcotic use and pain scores for patients with adolescent idiopathic scoliosis undergoing posterior spinal fusion. *Spine Deform.* 2015;3:82–7. doi: 10.1016/j.jspd.2014.06.002.
- Consulted references but not mentioned in the article:
- Ekatorodramis G, Min K, Cathrein P, Borgeat A. Use of a double epidural catheter provides effective postoperative analgesia after spine deformity surgery. *Can J Anaesth.* 2002;49:173–7.
 - Turner A, Lee J, Mitchell R, Berman J, Edge G, Fennelly M. The efficacy of surgically placed epidural catheters for analgesia after posterior spinal surgery. *Anaesthesia.* 2000;55:370–3.
 - Cassady J, Lederhaas G, Cancel DD, Cummings R, Loveless E. A randomized comparison of the effects of continuous thoracic epidural analgesia and intravenous patient controlled analgesia after posterior spinal fusion in adolescents. *Reg Anesth Pain Med.* 2000;25:246–53.
 - O'Hara J, Cywinski J, Tetzlaff J, Xu M, Gurd A, Andrich J. The effect of epidural vs. intravenous analgesia for posterior spinal fusion surgery. *Paediatr Anaesth.* 2004;14:1009–15.
 - Gauger V, Voepel-Lewis T, Burke C, Kostrzewa A, Caird M, Wagner D, et al. Epidural analgesia compared with intravenous analgesia after pediatric posterior spinal fusion. *Pediatr Orthop.* 2009;29:588–93. doi: 10.1097/BPO.0b013e3181b2ba08.
 - Tobias J. A review of intrathecal and epidural analgesia after spinal surgery in children. *Anesth Analg.* 2004;98:956–65.
 - Poe-Kochert C, Tripi PA, Potzman J, Son-Hing H, Thompson G. Continuous intravenous morphine infusion for postoperative analgesia following posterior spinal fusion for idiopathic scoliosis. *Spine.* 2010;35:754–7.
 - Saudan S, Habre W, Ceroni D, Meyer P, Greenberg R, Kaellin A, et al. Safety and efficacy of patient controlled epidural analgesia following pediatric spinal surgery. *Paediatr Anaesth.* 2008;18:132–9.
 - Taenzer A, Clark C. Efficacy of postoperative epidural analgesia in adolescent scoliosis surgery: a meta-analysis. *Paediatr Anaesth.* 2010;20:135–43