

ANESTESIA LOCO-REGIONAL PARA FRATURA DA CLAVÍCULA

//

REGIONAL ANESTHESIA FOR CLAVICLE FRACTURE

CATARINA COSTA RODRIGUES¹, VINCENT CHAN², ABHIJIT BISWAS³

Palavras-chave:

- Anestesia Loco-Regional;
- Bloqueio Nervoso;
- Clavícula;
- Fraturas Ósseas

Keywords:

- Anesthesia, Conduction;
- Clavicle;
- Fractures, Bone;
- Nerve Block

Data de submissão - 15 de junho, 2016

Data de aceitação - 7 de julho, 2016

¹ MD, Anesthesiology resident, Department of Anesthesia, Instituto Português de Oncologia de Lisboa Francisco Gentil, Lisbon, Portugal

² FRCPC, Professor, Department of Anesthesia, University of Toronto, Toronto, Canada

³ FCARCSI, Regional anesthesia fellow, Toronto Western Hospital, University of Toronto, Toronto, Canada

REGIONAL ANESTHESIA FOR CLAVICLE FRACTURE

In the setting of a clavicle fracture requiring surgical intervention, general anesthesia (GA) arises as the most common anesthetic technique. Due to various innervations over different parts of clavicle and overlying skin, operative regional anesthesia (RA) can be challenging.

The anatomy of the region is complex and its innervation includes nerves from both the cervical plexus and brachial plexus. The cervical plexus, emerging from C3 and C4, supplies the fascia and skin above the clavicle and shoulder as well as the first two intercostal spaces anteriorly through the superficial cervical plexus and supraclavicular nerves. Brachial plexus branches, such as the subclavian, suprascapular and axillary nerve, have an important role innervating various portions of the shoulder joint as well as the skin over the deltoid muscle.^{1,2}

We describe a case of 40 years-old man, with an ASA category 1, scheduled for open reduction and internal fixation of a displaced distal clavicle fracture. After obtaining an informed consent from patient, ultrasound guided superficial cervical plexus and interscalene block was performed. Six mL of 0.5% bupivacaine and 2% lidocaine (50-50 mixture) with epinephrine was administered in the fascial layer beneath the posterior border of sternocleidomastoid muscle at the level of C5 and C6 nerve root to achieve superficial cervical plexus block. In the same setting 14 mL of the same local anesthetic mixture was administered between C5 and C6 nerve root to achieve interscalene nerve block (Fig. 1). The patient achieved excellent sensory block (absence of pain on pin prick sensation over the area of clavicular fracture) within 10 minutes.

The surgery was successfully performed under sedation (propofol infusion at 35 mcg/kg/min). No opioid was used intraoperatively. The patient had an excellent recovery and was discharged home same day. As a routine hospital practice, he was contacted the following day. Sensory block had lasted for eight hours, was very satisfied, comfortable with minimum pain and did not report any complications.

When compared to GA, RA provides superior analgesia and quality recovery in the postoperative period, reducing post-operative nausea and vomiting and opioid consumption.³ This technique requires appropriate patient selection, profound anatomical knowledge, regional anesthesia skills and acceptance from the surgical colleague.

RA for distal clavicular surgery has been successfully performed as a day case procedure in Toronto Western Hospital. Along with patient's improved outcome, the efficiency of the institutional service is also enhanced. As anesthesiologists we should all acquire such skill sets incorporating them into our practice and improving efficiency and outcome.

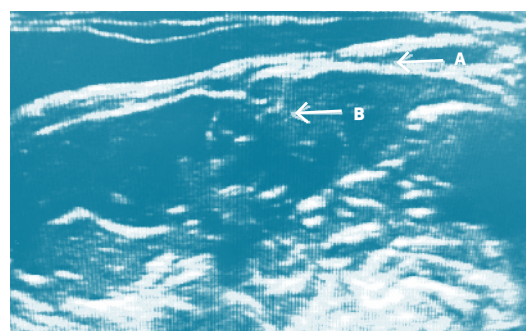


Figure 1. A. Superficial cervical plexus nerve block. B. Interscalene block.

REFERENCES

1. Tran DQ, Tiyaprasertkul W, González AP. Analgesia for clavicular fracture and surgery: a call for evidence. *Reg Anesth Pain Med.* 2013; 38:539-43.
2. Gray AT. Superficial cervical plexus block. In: Gray AT, editor. *Atlas of Ultrasound-Guided Regional Anesthesia.* 2nd ed. Philadelphia: Saunders; 2012. p. 207-300.
3. Choi DS, Atchabahian A, Brown AR. Cervical plexus block provides postoperative analgesia after clavicle surgery. *Anesth Analg.* 2005; 100:1542-3.