







## CLINICAL CASE REPORTS

# Rare Case of Paediatric Neuralgiform Headache with Autonomic Symptoms: Diagnosis and Management Challenges

Catarina Ferreira Nunes<sup>1</sup> , Luísa Castello-Branco Ribeiro<sup>1</sup> , Leonor Figueira<sup>1</sup> , Clara Abadesso<sup>1</sup> , Andreia Filipa Mota<sup>1</sup> ,  
Catarina Luís<sup>1</sup> 

### ABSTRACT

Neuralgiform headache, though rare, presents a diagnosis challenge in paediatric patients. This case study describes a 13-year-old female who experienced intense, electric shock-like headaches for two months. The headaches were unilateral, triggered by cold water, and associated with autonomic symptoms such as tearing, nasal congestion, and ptosis. Given the patient's clinical presentation, a diagnosis of short-lasting unilateral neuralgiform headache attacks with cranial autonomic symptoms was proposed. Imaging tests revealed sinusitis and a dental periapical lesion. Surgical intervention and treatment with gabapentin along with clinical hypnosis resulted in significant pain relief, although not complete. This case underscores the importance of thorough investigation and multidisciplinary management in paediatric patients with complex headache presentations. The long-term prognosis is variable, warranting ongoing follow-up.

**Keywords:** short-lasting unilateral neuralgiform headache attacks with cranial autonomic symptoms; neuralgiform headache; adolescent; paediatrics

1. Pediatrics Department, Hospital Professor Doutor Fernando Fonseca, ULS de Amadora/Sintra, Amadora, Portugal.  
catarinan46@gmail.com; luisa.ribeiro@ulsasi.min-saude.pt; leonor.figueira@ulsasi.min-saude.pt; clara.s.abadesso@ulsasi.min-saude.pt; andreia.mota@ulsasi.min-saude.pt; catarina.s.luis@ulsasi.min-saude.pt

## INTRODUCTION

Headache is one of the most frequent symptoms in the paediatric patient population and can occur in both acute and chronic contexts. It is one of the leading causes of disability in adolescents and young adults (ages 10 to 24 years).<sup>(1,7)</sup> About 60% of children and adolescents experience headaches deemed as significant at any point in their lives,<sup>(2,7)</sup> but the incidence is higher in female adolescents.<sup>(2)</sup>

According to the International Classification of Headache Disorders, headaches can be classified as primary or secondary.<sup>(3)</sup> Primary headaches can have a significant impact on the quality of life of the child/adolescent, the ability to participate in sports and social activities, on relationships with peers and family, and school performance.<sup>(4)</sup> Additionally, they have important financial implications, both at a personal and community level.<sup>(5,6)</sup> However, despite their high incidence and widely recognized implications, they remain underdiagnosed and undertreated worldwide, likely due to a low mortality rate.<sup>(6)</sup>

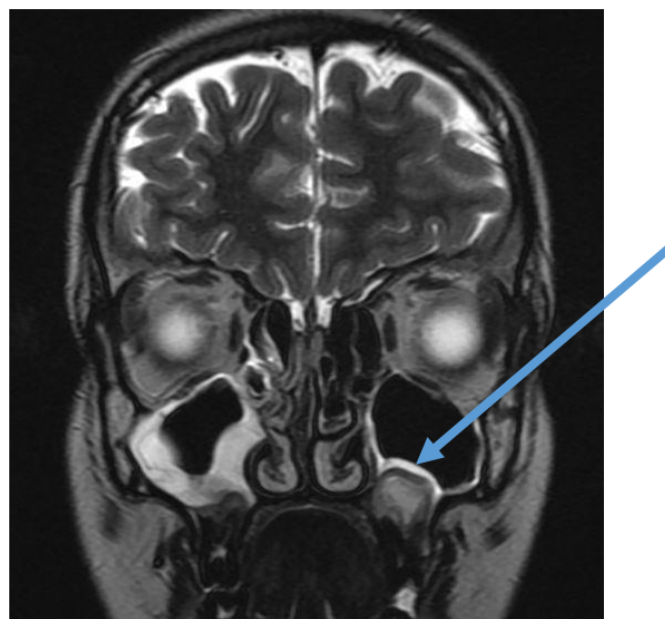
Trigeminal autonomic cephalalgias are primary headaches that can be subdivided into several subtypes: cluster headache, paroxysmal hemicrania, hemicrania continua, and short-lasting unilateral neuralgiform headache attacks.<sup>(3)</sup> The latter can be further subdivided into two groups: short-lasting unilateral neuralgiform headache attacks with cranial autonomic symptoms (SUNA) and short-lasting unilateral neuralgiform headache attacks with conjunctival injection and tearing (SUNCT).<sup>(3)</sup> The estimated prevalence of short-lasting unilateral neuralgiform headache attacks is thought to be 6.6/100,000 people with a typical age of onset of 35–65 years, although children and adolescents can also be affected.<sup>(8,9)</sup> SUNCT is more common in males, whereas SUNA is more frequently observed in females.<sup>(9)</sup>

## CASE REPORT

A 13-year-old female adolescent presented to the emergency department with intense electric shock-like headaches lasting for two months. She described the headaches as left-sided hemicranial, lasting for seconds, with several episodes a day, without prodromal symptoms, associated with ipsilateral eyelid paraesthesias, tearing, nasal congestion and ptosis. Triggers were not constant: water contact on the face during bathing or brushing teeth, or cold pool water. Some of the longer-lasting episodes were relieved with warm water. Associated symptoms included ipsilateral ptosis and hypoacusis, upper eyelid myoclonias, and occasional trismus. Coincidentally, in the previous two months she had had multiple visits to the emergency department and hospitalizations for acute suppurative otitis media, initially on the right and subsequently on the left, with associated otomastoiditis and external otitis. She was treated with several cycles of topical and oral antibiotics. Regarding

her medical history, she was an excellent student, practiced synchronized swimming, and played a musical instrument (the cello). Due to hypoacusis and worsening headaches with cold water contact, she stopped exercising and playing the cello, which also impacted her academic performance and caused significant psychological distress.

She was admitted to the hospital for further investigation. Physical examination during both the pain episodes and periods without complaints revealed no neurological findings other than profound allodynia in the peri-auricular area (in both the trigeminal and cervical plexus areas), which was intriguing. A computed tomography scan of the head showed left frontal and bilateral maxillary sinusitis, with no intracranial abnormalities. Subsequently, magnetic resonance angiography was performed given the main diagnosis hypothesis of neuralgiform headache with autonomic symptoms, to exclude secondary lesions or vascular anomalies. The imaging test revealed inflammatory polysinusitis with acute exacerbation in the right maxillary sinus and a dental periapical lesion protruding into the alveolar recess of the left maxillary sinus (**Figure 1**), while the angiography was normal.



**Figure 1** - Magnetic resonance revealing no structural encephalic lesions, and patent cisternal spaces with a well-defined appearance of the cranial nerves, particularly III and V. Inflammatory polysinusopathy, with acute exacerbation in the right maxillary sinus. Dental periapical lesion protruding into the alveolar recess of the left maxillary sinus, likely associated with tooth 2.6.

This lesion was considered an accidental finding, often found in many patients. However, because it was not possible to

exclude a secondary cause to the headache, the patient was referred to a stomatology specialist. During hospitalization, she was medicated with gabapentin 100 mg twice daily and experienced pain relief, leading to discharge for outpatient follow-up. The hypothesis of a diagnosis of neuralgiform headache with autonomic symptoms was considered.

For the following six months, gabapentin was increased weekly, until reaching a dose of 300 mg twice daily, resulting in progressive improvement of the pain episodes, although without complete resolution. The patient still reported having similar episodes, although less frequently. Tympanometry and audiometry revealed mild left-sided hypoacusis. She was evaluated by a stomatologist because of the findings in the magnetic resonance imaging, and an odontogenic origin was hypothesized. Exodontia of the lesion was performed, requiring extensive reconstruction of the left maxilla. Histopathological evaluation revealed later an inflammatory lesion with probable odontogenic origin, without other malignant findings. After surgery, she experienced substantial pain relief, although complete resolution was not achieved. She maintained treatment with gabapentin and initiated clinical hypnosis, with clinical improvement, but still reported sporadic episodes (at least one every three months), though less intense. The pain characteristics were the same as described initially. The patient continued to be monitored by the maxillofacial surgeon, otorhinolaryngologist and a pain specialist as an outpatient.

## DISCUSSION

The diagnosis of neuralgiform headache, although rare, should be considered in a patient with highly suggestive clinical features, namely episodes of intense headaches lasting for seconds, in the area of the trigeminal nerve, and with neuropathic pain characteristics, such as pain felt as an electric shock or stabbing and its triggers. Despite the fact that the pain associated with SUNA is usually orbital, the neuropathic and autonomic exuberant characteristics of the pain in this patient made the diagnosis very likely. The fact that these episodes occurred both with and without triggers also fits this diagnostic entity.

In the differential diagnosis, the intense pain associated with touch, both in the preauricular area and the retroauricular area, made the diagnosis of trigeminal neuralgia less likely, given that the retroauricular area is innervated by the cervical plexus. In a patient with several ear infections, Gradenigo's syndrome should also be ruled out. This syndrome manifests as a triad characterized by otorrhea, abducens nerve palsy, and pain in the trigeminal nerve distribution and can develop as a result of an ear infection complicated with contiguous spread of petrous apicitis to the nearby neurovascular structures. The triad is rarely present in all of the patients, but the pain is not usually associated with autonomic symptoms. Moreover, the neuroimaging exams performed did not reveal any finding

suggestive of this pathology.<sup>(10)</sup>

The presence of uncontrolled pain for a long period of time and recurrent episodes may have contributed to the onset of allodynia and a lowered pain threshold, suggesting dysregulation of the central nervous system. Usually, SUNCT and SUNA are primary headaches, although there are some described cases of neuralgiform headache with a secondary cause, namely structural or anatomical changes in the posterior fossa or pituitary gland. There are also some cases of SUNCT and SUNA secondary to viral meningitis, meningoencephalitis, traumatic brain injuries or periapical inflammation.<sup>(11-15)</sup> Neuralgiform headache can also be due to neurovascular loops, which may justify vascular intervention.<sup>(17)</sup> These cases suggest that peripheral pain mechanisms may play an important role in the pathophysiology of these entities.

In order to consider neuralgiform headache as a possible cause, the headache must meet the following criteria: a close temporal relationship between the symptoms and the appearance of the lesion (in this patient it was difficult to pinpoint the timeline), concordance between the location of the pain and the side of the lesion, and remission of complaints immediately after removal of the lesion.<sup>(16)</sup> In this particular case, the presence of a maxillary lesion raised the suspicion for secondary SUNA. However, after the surgery, the patient still complained of pain episodes, although less intense and less frequent.

One of the diagnostic criteria for neuralgiform headache is that there is no other diagnosis that better explains the symptoms.<sup>(3)</sup> The patient described in this report had a simultaneous history of ear infections, including complication with left-sided otomastoiditis, ipsilateral to the headache. Although the infection was initially accepted as a possible cause for the pain, it was later considered unlikely because clearance of the infection was not accompanied by resolution of the headaches. The episodes were less intense after gabapentin was initiated, but did not resolve completely, suggesting a neuropathic mechanism for the pain accompanied by central dysfunction of the pain regulation mechanisms. Due to the periapical lesion protruding into the alveolar recess of the left maxillary sinus, odontogenic headache was also considered, but removal of the lesion was associated with partial pain relief only, making this diagnosis challenging.

The preventive treatment for neuralgiform headache includes various therapeutic interventions, namely lamotrigine, topiramate, and gabapentin.<sup>(18)</sup> The reported effectiveness of gabapentin for pain relief in SUNA varies depending on the study: 39%<sup>(19)</sup> vs. 10%.<sup>(20)</sup>

There is not enough scientific evidence to provide an accurate estimate of the long-term prognosis of neuralgiform headache. Some patients may experience symptom relief over months to years, while others may have persistent or recurrent symptoms throughout their lives. In other types of trigeminal autonomic headaches, many patients experience a decrease in symptom frequency with age.<sup>(19)</sup> In this case, the

patient has shown a favourable evolution, with significant reduction in the frequency of the pain episodes, maintaining only sporadic episodes after a few months of treatment.

## CONCLUSION

Neuralgiform headache, despite its rarity, should be considered in paediatric patients presenting with intense, short-duration headaches in the trigeminal nerve area, particularly when accompanied by autonomic symptoms. This case highlights the complexity of the diagnosis and the need for comprehensive evaluation, including imaging and careful assessment of the medical history, to identify potential secondary causes such as an odontogenic origin. Early recognition and appropriate intervention can mitigate the substantial psychosocial impact of this condition, particularly in active adolescents. Continued research and clinical awareness are essential to better understand the long-term prognosis and optimise management strategies for neuralgiform headaches in the paediatric population.

## AUTHORSHIP

Catarina Ferreira Nunes - Conceptualization; Writing – original draft

Luísa Castello-Branco Ribeiro - Conceptualization; Writing – original draft

Leonor Figueira – Conceptualization; Writing – original draft

Clara Abadesso - Writing - review & editing

Andreia Mota – Writing - review & editing

Catarina Luís - Writing - review & editing

## REFERENCES

1. GBD 2019 Diseases and Injuries Collaborators. Global burden of 369 diseases and injuries in 204 countries and territories, 1990-2019: a systematic analysis for the Global Burden of Disease Study 2019. *Lancet*. 2020 Oct 17;396(10258):1204-1222. doi: [https://doi.org/10.1016/S0140-6736\(20\)30925-9](https://doi.org/10.1016/S0140-6736(20)30925-9). Erratum in: *Lancet*. 2020 Nov 14;396(10262):1562. doi: [https://doi.org/10.1016/S0140-6736\(20\)32226-1](https://doi.org/10.1016/S0140-6736(20)32226-1). PMID: 33069326; PMCID: PMC7567026.
2. Abu-Arafeh I, Razak S, Sivaraman B, Graham C. Prevalence of headache and migraine in children and adolescents: a systematic review of population-based studies. *Dev Med Child Neurol*. 2010 Dec;52(12):1088-97. doi: <https://doi.org/10.1111/j.1469-8749.2010.03793.x>. Epub 2010 Sep 28. PMID: 20875042.
3. Headache Classification Committee of the International Headache Society (IHS) The International Classification of Headache Disorders, 3rd edition. *Cephalalgia* 2018; 38:1.
4. Leonardi M, Grazi L, D'Amico D, Martelletti P, Guastafierro E, Toppo C, *et al*. Global Burden of Headache Disorders in Children and Adolescents 2007-2017. *Int J Environ Res Public Health*. 2020 Dec 31;18(1):250. doi: <https://doi.org/10.3390/ijerph18010250>. PMID: 33396281; PMCID: PMC7795582.
5. Nichols VP, Ellard DR, Griffiths FE, Kamal A, Underwood M, Taylor SJC; CHES team. The lived experience of chronic headache: a systematic review and synthesis of the qualitative literature. *BMJ Open*. 2017 Dec 15;7(12):e019929. doi: <https://doi.org/10.1136/bmjopen-2017-019929>. PMID: 29248887; PMCID: PMC5778309.
6. World Health Organisation. Neurological disorders: public health challenges. Switzerland: World Health Organisation, 2006.
7. Szperka C. Headache in Children and Adolescents. *Continuum (Minneapolis)*. 2021 Jun 1;27(3):703-731. doi: <https://doi.org/10.1212/CON.0000000000000993>. PMID: 34048400; PMCID: PMC9455826.
8. Qaiser S, Hershey AD, Kacperski J. SUNCT/SUNA in children and adolescents: Application of ICHD-3 criteria and treatment response: Case series of 13 SUNCT/SUNA pediatric cases. *Cephalalgia*. 2021 Jan;41(1):112-116. doi: <https://doi.org/10.1177/0333102420954525>. Epub 2020 Aug 31. PMID: 32867532.
9. Al Khalili Y, Veerapaneni KD. Short-Lasting Unilateral Neuralgiform Headache. [Updated 2023 May 29]. In: StatPearls [Internet]. Treasure Island (FL): StatPearls Publishing; 2024 Jan-. Available from: <https://www.ncbi.nlm.nih.gov/books/NBK559088/>.
10. Bano S, Nawaz A, Asmar A, Aemaz Ur Rehman M, Farooq H, Ali H. Gradenigo's syndrome presenting as IX and X cranial nerve palsy without clinically apparent ear infection: A case report and review of literature. *eNeurologicalSci*. 2022 Mar 17;27:100397. doi: <https://doi.org/10.1016/j.ensci.2022.100397>. PMID: 35330846; PMCID: PMC8938864.
11. Ito Y, Yamamoto T, Ninomiya M, Mizoi Y, Itokawa K, Tamura N, Araki N, Shimazu K. Secondary SUNCT syndrome caused by viral meningitis. *J Neurol*. 2009 Apr;256(4):667-8. doi: <https://doi.org/10.1007/s00415-009-0104-2>. Epub 2009 Apr 27. PMID: 19444540.
12. Eguia P, Garcia-Monco JC, Ruiz-Lavilla N, Diaz-Konrad V, Monton F. SUNCT and trigeminal neuralgia attributed to meningoencephalitis. *J Headache Pain*. 2008 Feb;9(1):51-3. doi: <https://doi.org/10.1007/s10194-008-0008-z>. Epub 2008 Jan 23. PMID: 18217200; PMCID: PMC3476171.
13. Jacob S, Saha A, Rajabally Y. Post-traumatic short-lasting unilateral headache with cranial autonomic symptoms (SUNA). *Cephalalgia*. 2008 Sep;28(9):991-3. <https://doi.org/10.1177/0333102408313261>. Epub 2008 May 30. PMID: 18513261.
14. Putzki N, Nirkko A, Diener HC. Trigeminal autonomic cephalalgias: a case of post-traumatic SUNCT syndrome?

- Cephalalgia. 2005 May;25(5):395-7. doi: <https://doi.org/10.1111/j.1468-2982.2004.00860.x>. PMID: 15839855.
15. Groenke, B. R., Daline, I. H., & Nixdorf, D. R. (2021). SUNCT/SUNA: Case series presenting in an orofacial pain clinic. *Cephalalgia: an international journal of headache*, 41(6), 665–676. <https://doi.org/10.1177/0333102420977292>.
  16. Trucco M, Mainardi F, Maggioni F, Badino R, Zanchin G. Chronic paroxysmal hemicrania, hemicrania continua and SUNCT syndrome in association with other pathologies: a review. *Cephalalgia*. 2004 Mar;24(3):173-84. <https://doi.org/PMID: 15009010>.
  17. Lambru G, Rantell K, O'Connor E, Levy A, Davagnanam I, Zrinzo L, *et al*. Trigeminal neurovascular contact in SUNCT and SUNA: a cross-sectional magnetic resonance study. *Brain*. 2020 Dec 1;143(12):3619-3628. doi: <https://doi.org/10.1093/brain/awaa331>. PMID: 33301567; PMCID: PMC7807031.
  18. Weng H-Y, Cohen AS, Schankin C, Goadsby PJ. Phenotypic and treatment outcome data on SUNCT and SUNA, including a randomised placebo-controlled trial. *Cephalalgia* 2018;38:1554–63. doi: <https://doi.org/10.1177/0333102417739304>.
  19. Matharu M. Cluster headache. *BMJ Clin Evid* 2010 Feb 9;2010:1212.

#### CORRESPONDENCE TO

Catarina Ferreira Nunes  
Department of Pediatrics  
Hospital Professor Doutor Fernando Fonseca  
ULS de Amadora/Sintra  
IC 19, 2720-276 Amadora  
Email: [catarinan46@gmail.com](mailto:catarinan46@gmail.com)

Received for publication: 19.08.2024  
Accepted in revised form: 12.05.2025