


CASE REPORTS

NASOLABIAL CYST IN PEDIATRIC AGE

CISTO NASOLABIAL EM IDADE PEDIÁTRICA

Marta Ribeiro Silva¹ , Ana Patrícia Rosa², Daniel Miranda³, Manuela Costa Alves¹

ABSTRACT

Herein is described the case of a 26-month-old male observed in the Emergency Department for edema of the upper lip and left malar region with less than 24 hours of evolution and progressive worsening. No other associated complaints, previous history of trauma, or insect sting were reported. Computed tomography revealed a “left premaxillary abscess associated with ipsilateral nasogenian phlegm”. Intravenous antibiotic therapy with clarithromycin and clindamycin and systemic corticosteroid therapy with dexamethasone were started, and the boy was admitted to the Pediatric Department. He presented favorable clinical evolution, with complete resolution of inflammatory signs. At discharge, the patient remained asymptomatic and was referred to Otorhinolaryngology consultation for follow-up.

Although nasolabial cysts are rare in pediatric age, this case intends to raise awareness of the condition, enabling its recognition by clinicians, and increase knowledge about its course and treatment.

Keywords: infection; nasolabial cyst; non-odontogenic cyst

RESUMO

É apresentado o caso de uma criança do sexo masculino com 26 meses de idade, que recorreu ao Serviço de Urgência por edema do lábio superior e região malar esquerda com menos de 24 horas de evolução e agravamento progressivo. Não foram reportadas outras queixas associadas, história prévia de traumatismo ou picada de inseto. Foi efetuada tomografia computadorizada maxilofacial com contraste, que revelou “abscesso pré-maxilar esquerdo associado a fleimão nasogeniano ipsilateral”. O doente iniciou antibioterapia endovenosa com claritromicina e clindamicina e corticoterapia sistémica com dexametasona e foi internado no Serviço de Pediatria, apresentando evolução clínica favorável, com resolução total dos sinais inflamatórios. À data da alta, mantinha-se assintomático e foi orientado para consulta de Otorrinolaringologia para seguimento.

Apesar de o cisto nasolabial ser uma entidade rara em idade pediátrica, este caso clínico pretende alertar para a sua existência e reforçar a importância do seu reconhecimento pelos clínicos, bem como aumentar o conhecimento da sua evolução e tratamento.

Palavras-chave: cisto nasolabial; cisto não-odontogénico; infeção

1. Department of Pediatrics, Hospital de Braga. 4710-243 Braga, Portugal. martaribeirosilva12@gmail.com, manuelacostaalves@gmail.com
2. Unidade de Saúde Familiar Alcaides de Faria. 4755-558 Barcelos, Portugal. anapatriciarosa@gmail.com
3. Department of Otorhinolaryngology, Hospital de Braga. 4710-243 Braga, Portugal. alvesmiranda@gmail.com

INTRODUCTION

Non-odontogenic cysts within the jaws are not a common finding, especially in pediatric age. It is well documented that cysts in the pediatric population tend to be developmental and odontogenic.¹ Nasolabial cyst is a rare development cyst, comprising only 0.7% of all jaw cysts. It occurs in the upper lip, laterally of the midline, or near the lateral and canine tooth junction.^{1,2} The pathogenesis of nasolabial cysts remains uncertain. Currently, the most widely accepted theory is that it originates from the inferior and anterior portion of the nasolacrimal duct. This theory is supported by the fact that the nasolacrimal duct is lined with pseudostratified columnar epithelium, also found in nasolabial cyst cavities.^{3,4} Clinically, nasolabial cysts are characterized by unilateral volume increase in the nasolabial region, causing an elevation of the nose wing, projection of the upper lip, and sometimes nasal obstruction. They present slow and asymptomatic growth.² Local pain and abrupt lesion enlargement may occur when associated with infection, which may be present in up to 50% of cases.^{3,4} The diagnosis is usually based on clinical course, with imaging tests valuable in assisting it. For being soft tissue lesions, nasolabial cysts are not visualized with traditional plain film radiographs. Traditional computed tomography (CT) or magnetic resonance imaging (MRI) show a soft tissue mass of varying size usually well demarcated.^{1,2}

Treatment of nasolabial cysts can be accomplished through fine-needle aspiration, incision and drainage, cystic enucleation by intraoral access, endoscopic dorsal marsupialization, and intralesional injection of sclerosing agents.^{1,2,4}

CASE REPORT

A 26-month-old male with a personal history of allergy to penicillin resorted to the Emergency Department for edema of the upper lip and left malar region with less than 24 hours of evolution and perception of progressive worsening, according to the mother. No other associated complaints or previous history of trauma or insect bite were reported. The patient had good general condition and no fever. Extraoral examination revealed facial asymmetry with rubor and edema of the upper lip, slight elevation of nasal ala, and deformity of the left nasolabial sulcus (**Figures 1 and 2**). A small and circumscribed fluctuant area in the maxillary region was detected on palpation. Observation by an otolaryngologist (ENT) revealed intraoral edema of the left oral vestibule and no intranasal alterations.

CT scan with intravenous contrast was performed, revealing a premaxillary left abscess with ipsilateral nasolabial phlegm (**Figure 3**). Based on clinical history and imagiological findings, diagnosis of infected nasolabial cyst was proposed.

Treatment with endovenous clarithromycin and clindamycin and systemic corticosteroid therapy with dexamethasone was initiated, and the patient was admitted to the Pediatric Department

with progressive improvement of inflammatory signs. During hospitalization, stomatological observation discarded associated dental pathologies.

At discharge, the patient was completely asymptomatic and was referred to ENT consultation for follow-up. He remained asymptomatic, with no additional infectious episodes.

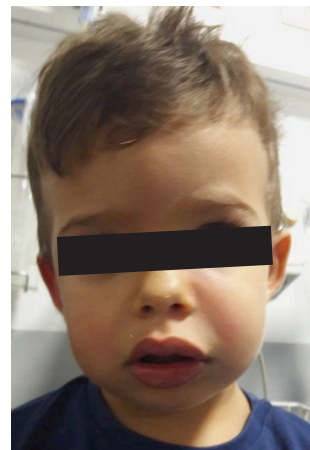

Figure 1 - Facial asymmetry with rubor and edema of the upper lip

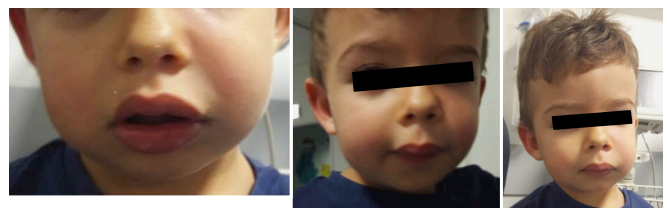

Figure 2 - Elevation of left ala nasi and deformity of the nasolabial sulcus

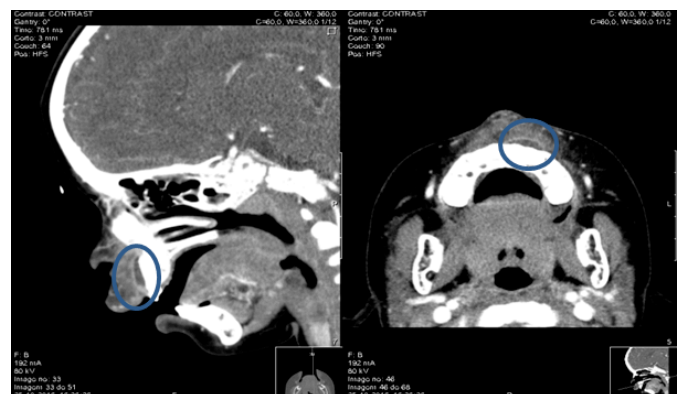

Figure 3 - CT images showing the lesion marked with a blue circle

DISCUSSION

Although nasolabial cyst is a rare diagnosis in children, this case illustrates the most common features in patients with this condition. Although the case refers to a male patient, nasolabial cysts are more frequent in females, according to the literature.¹⁻⁵ The differential diagnosis may include other lesions affecting the anterior maxillary region, such as odontogenic cysts and periapical abscesses and granulomas.³⁻⁵ Pulp vitality testing of adjacent teeth is essential to confirm the diagnosis since coincidental dental lesions are a frequent cause of abscesses and require exclusion as a possible etiological factor.³ In the present case, this differential diagnosis was excluded by stomatological observation. Other possible diagnoses, such as dermoid and epidermoid cysts, are usually associated with yellow discoloration of the overlying mucosa, whereas in nasolabial cysts, the mucosa preserves its normal pink hue or appears blue-tinged.⁴

The traditional approach to this lesion in the adult population is surgical excision via intraoral/sublabial approach.¹ However, data regarding the best approach in pediatric age is scarce. Additionally, as nasolabial cysts are usually located near the nasal cavity floor, complications as nasal mucosa perforation during surgical excision are not uncommon.³ In this case, given the patient's age and favorable clinical evolution after resolution of the acute infectious process, a wait-and-watch attitude with regular follow-up was chosen as the preferential approach. In the future, surgical removal may be considered if the patient presents complaints or new infectious events.

CONCLUSION

Data in the literature and from the present case report suggest that, although nasolabial cysts are a rare finding in pediatric age, pediatricians, ENT, and dental practitioners should be aware of its key features and be able to distinguish it from other odontogenic lesions. More studies are required to determine the best approach for treating this condition in pediatric populations.

REFERENCES

1. Jones RS, Dillon J. Nonodontogenic Cysts of the Jaws and Treatment in the Pediatric Population. *Oral Maxillofac Surg Clin North Am.* 2016 Feb; 28(1):31-44. doi: 10.1016/j.coms.2015.08.001.
2. Santos ASM, Bonardi JP, Pereira-Stabile CL, *et al.* Cisto nasolabial infetado: caso clínico. *Rev Port Estomatol Med Dent Cir Maxilofac.* 2014; 55(3):187-91. doi: 10.1016/j.rpemd.2014.06.003.
3. Bettoni CH, Jaeger F, López-Alvarenga R, *et al.* Cisto nasolabial: revisão da literatura e relato de caso clínico. *Rev Port Estomatol Med Dent Cir Maxilofac.* 2011;52(3): 157-60. doi:10.1016/j.

rpemd.2013.11.003.

4. Giongo CC, Antonello GM, Couto, RT, *et al.* Nasolabial cyst: a case report. *Rev Port Estomatol Med Dent Cir Maxilo Fac.* 2014;55(1):55-9.
5. Segundo AVL, Soares MSM, Nogueira EFC, *et al.* Cisto nasolabial: relato de 2 casos. *Rev. Cir. Traumatol. Buco-Maxilo-Fac.* 2013; 13(4):57-62.

CORRESPONDENCE TO

Marta Ribeiro Silva
Department of Pediatrics
Hospital de Braga
Rua das Comunidades Lusíadas 133
4710-243 Braga
Email: martaribeiroSilva12@gmail.com

Received for publication: 07.10.2019

Accepted in revised form: 13.10.2020