

# Case of Primary Mucosa Associated Lymphoid Tissue Lymphoma of the Lacrimal Sac

Mário Canastro<sup>1</sup>, Helena Fialho<sup>1</sup>, Paula Sens<sup>1</sup>, António Alves<sup>2</sup>, Cristina Ferreira<sup>2</sup>, Manuel Monteiro-Grillo<sup>1</sup>

<sup>1</sup>Ophthalmology Department, Hospital de Santa Maria, CHLN

<sup>2</sup>Histopathology Department, Hospital de Santa Maria, CHLN

## ABSTRACT

**Introduction:** Primary lacrimal sac lymphoid tumors are a rare entity, the most frequent being the diffuse large B cell lymphoma and the extranodal marginal zone B cell lymphoma of mucosa associated lymphoid tissue (MALT lymphoma). We report a case of primary lacrimal sac lymphoma treated primarily with conformal radiotherapy.

**Case Report:** An 86 years-old female presents with a symptomatic mass on the right lacrimal fossa area. Clinical investigation with orbital CT scan, Doppler ultra-sonography, incisional biopsy and systemic investigation lead to the diagnosis of a MALT lymphoma, Ann Harbour stage IE. Primary small dose three dimensional conformal radiotherapy was performed, with complete remission of the local lesion. No signs of recurrence were identified on follow-up.

**Discussion:** Primary MALT lymphoma of the lacrimal sac is a rare entity and its presentation may be misleading. Radiotherapy may be considered as primary treatment in local lesions.

**Keywords:** Ocular lymphoma, MALT lymphoma, lacrimal sac.

## INTRODUCTION

Primary lacrimal sac tumors, although rare, are of malignant origin in 95% of the cases, most of them corresponding to epithelial neoplasms.<sup>1,2</sup> Primary ocular adnexal (OA) lymphomas (which includes eyelids, conjunctiva, lacrimal gland, lacrimal sac, orbit tissues and extra-ocular muscles) are a rare entity, accounting for 1-2% of all non-Hodgkin lymphomas (NHL) and 5 to 15% of extranodal lymphomas.<sup>3</sup> In Europe, the most frequent lacrimal sac lymphoid neoplasms are diffuse large B cell

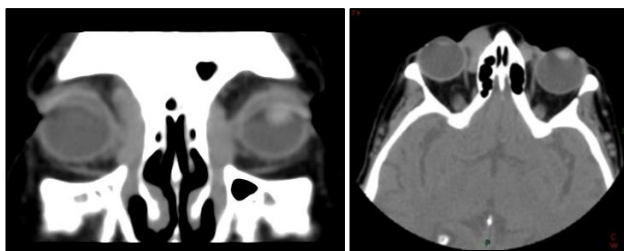
lymphoma (DLBCL) and extranodal marginal zone B cell lymphoma of mucosa associated lymphoid tissue (MALT lymphoma).<sup>4</sup> Clinical presentation may be misleading and delay the diagnosis.<sup>1,5,6</sup> To date, there is no clear consensus about optimal treatment.<sup>7</sup>

In this report, we describe the clinical features of a primary lacrimal sac MALT lymphoma treated successfully with conformal radiotherapy.

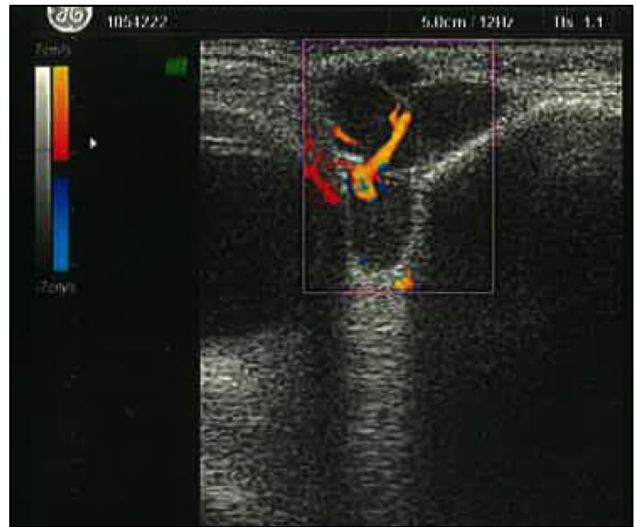
## CASE REPORT

An 86 years-old female was referred to our clinic with recurrent epiphora and conjunctival hyperemia on the right eye (OD), associated with a swelling on the right lacrimal fossa area. She had a past ophthalmologic history of a longstanding severe amblyopia of the left eye (OS), OD cataract surgery three years ago and previous episodes of acute dacryocystitis on OD, treated with antibiotics. On clinical examination, her visual acuities were 20/50 OD and hand movement OS. The intra-ocular pressures were within normal range. The right lacrimal duct was obstructed, with no significant secretion on lacrimal sac compression. The lacrimal sac area had a painless firm and non-mobile mass, 20mm in height and 15mm in width, with an associated tenderness of the surrounding tissues of the lower and upper lid. On slit-lamp examination she presented a monofocal in-the-bag intra-ocular lens implant with posterior capsule opacification and a mature corticonuclear cataract in OS. Fundus observation was normal in both eyes.

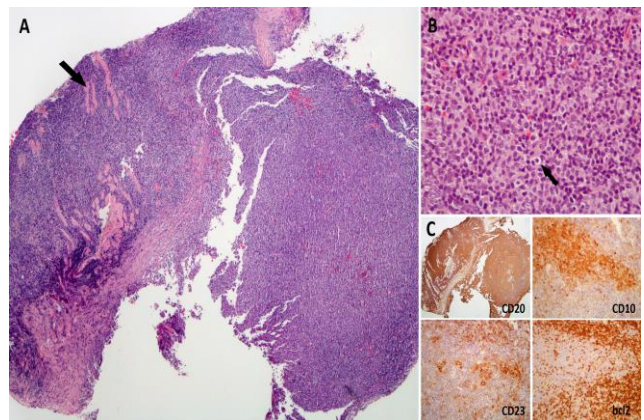
An orbital computerized tomography (CT) scan (Figure 1) revealed an enlarged right lacrimal sac with irregular contour and invasion of the extra-conic compartment of the orbit. A doppler ultra-sonography (US) (Figure 2) revealed a 21mm height nodular lesion with significant intrinsic vascularization. An incisional biopsy was performed and a pathological diagnosis of extranodal marginal-zone B-cell lymphoma, or MALT lymphoma, was made (Figure 3). Systemic investigation with cranial, chest, and abdomen CT scan and blood and bone marrow analysis excluded multi-organ involvement (Ann Harbour stage IE).



**Figure 1** - Orbital CT scan revealing swelling of the right lacrimal sac, with irregular borders and invasion of the extra-conic compartment of the orbit.



**Figure 2** - Doppler ultra-sonography of the lacrimal fossa: nodular lesion with 21mm in height, with extensive intrinsic vascularization



**Figure 3** - Histologic analysis of incisional biopsy. A (H&E, 40x): Dense and diffuse infiltrate of small lymphoid cells, with dissection of the striated muscle (arrow). B (H&E, 400x): Cells with centrocyte-like morphology, some abundant pale cytoplasm. C (40x): Cells show CD20 immunohistochemical expression (B phenotype). (200x) Non-neoplastic residual secondary lymphoid follicles, shown by CD23, CD10 e Bcl2 immunoreactivity. H&E: hematoxylin-eosin staining.

The patient was treated with radiotherapy with a dose of 8 Gy, divided in two weekly sessions by three dimensional conformal technique. No further treatment was proposed, considering patient's age and comorbidities. The patient had a complete remission of the lymphoid neoplasm and was kept under monthly surveillance. After twelve months follow-up, no evidence of systemic or local recurrence has been identified.

## DISCUSSION

Primary MALT lymphoma of the lacrimal sac is infrequent. Most of the cases reported in the literature are secondary manifestations of a systemic disease. Nevertheless, both in U.S.A. and Europe the estimated annual age-adjusted incidence of orbital and OA MALT lymphomas had a significant rise in the last 3 decades.<sup>7</sup>

Primary lacrimal sac lymphomas is a disease affecting mainly the elderly (mean age at presentation 70 years), even though some cases have been reported in pediatric age.<sup>4,7,8</sup> Incidence is similar in both genders. The most frequent clinical symptoms on presentation are epiphora and medial canthal swelling, similarly to other lacrimal drainage system neoplasms.<sup>9</sup> Due to unspecific clinical presentation and the high incidence of infectious processes due to lacrimal drainage obstruction, frequently these tumors are initially treated as dacryocystitis, both acute or chronic, delaying final diagnosis.<sup>5,6,9,10</sup> Differential diagnosis in this cases include non-granulomatous and granulomatous inflammation or infection, benign tumors (dermoid cyst, mucocele, lipoma, hemangioma, lymphangioma) and several types of malignant neoplasms (squamous cell carcinoma, adenocarcinoma, mucoepidermoid carcinoma, adenoid cystic carcinoma, different types of lymphoma, melanoma, sarcoma, schwannoma, solitary fibrous tumour).<sup>1,10</sup> Some imaging exams are used to clinical investigation. Dacryocystography is particularly useful in early cases with little or no swelling of the sac. CT scan evaluates mass location and bone destruction and Magnetic Resonance Imaging (MRI) is the best exam to evaluate extension of the tumor and relation with adjacent soft tissues. US is also useful in differentiating solid from cystic masses, evaluating vasculature and can be used to guide biopsy.<sup>3,11</sup>

Definitive diagnosis is obtained through histological analysis and should be performed routinely in all lacrimal sac surgical interventions.<sup>12</sup> Most of the lymphoid neoplasms are of B-cell origin and DLBCL and MALT lymphomas account for more than 50% of the lacrimal sac lymphomas.<sup>7</sup> Histologic classification and staging are the most relevant prognostic factors in these patients.<sup>3,13</sup>

The high incidence of MALT lymphomas has been associated with chronic inflammation of the lacrimal drainage system, as happens with chronic dacryocystitis and infection with *Chlamydomydia psittaci*. The persistent antigenic stimulation induces a clonal B-cell proliferation

of the mucosal lymphoid tissue. If sequential genetic abnormalities hit a clonal B-cell among the reactive B-cells, a malignant transformation may appear, giving rise to MALT lymphoma.<sup>14,15</sup>

There is no guideline concerning treatment of OA MALT lymphoma. When there are no signs of systemic disease, most cases have been managed with radiation therapy as primary treatment, with doses ranging 35 to 40 Gy. Several case reports and case series evidenced high rates of local control in patients with stage IE MALT lymphoma treated with radiotherapy.<sup>16-18</sup> Several side effects were associated with this treatment (cataracts, radiation retinopathy, dry eye syndrome, keratopathy) so close monitoring is necessary.<sup>17</sup> In our patient, local control was obtained with a low dose of radiation, suggesting that in selected cases lower doses can be used, avoiding most of the adverse effects of the treatment. Longer follow-up would be necessary to confirm complete remission. Prognosis in cases of OA MALT lymphoma is generally good, depending on the staging.<sup>3,7</sup> Ohga group obtained 81.5% 5-year survival rate in a series of seventy three patients treated only with radiotherapy<sup>18</sup> and other studies reported a total 75% 5-year survival rate even when relapse and widespread disease is observed.<sup>7</sup>

In summary, we report a rare case of primary lacrimal sac MALT lymphoma. Primary treatment with radiotherapy is a treatment option with potential curative effects. Malignant proliferation should always be considered in the differential diagnosis of chronic or recurrent dacryocystitis in the elderly.

## REFERENCES

1. Bi Y-W, Chen R-J, Li X-P. [Clinical and pathological analysis of primary lacrimal sac tumors]. *Zhonghua Yan Ke Za Zhi*. 2007;43(6):499-504.
2. Pe'er JJ, Stefanyszyn M, Hidayat AA. Nonepithelial tumors of the lacrimal sac. *Am J Ophthalmol*. 1994;118(5):650-658.
3. Ponzoni M, Govi S, Licata G, et al. A reappraisal of the diagnostic and therapeutic management of uncommon histologies of primary ocular adnexal lymphoma. *Oncologist*. 2013;18(7):876-884.
4. Sjö LD, Ralfkiaer E, Juhl BR, et al. Primary lymphoma of the lacrimal sac: an EORTC ophthalmic oncology

- task force study. *Br J Ophthalmol*. 2006;90(8):1004-1009.
5. de Palma P, Ravalli L, Modestino R, Grisanti F, Casillo F, Marzola A. Primary lacrimal sac B-cell immunoblastic lymphoma simulating an acute dacryocystitis. *Orbit*. 2003;22(3):171-175.
  6. Kajita F, Oshitari T, Yotsukura J, et al. Case of primary diffuse large B-cell lymphoma of lacrimal sac in a Japanese patient. *Clin Ophthalmol*. 2010;4:1351-1354.
  7. Sjö LD. Ophthalmic lymphoma: epidemiology and pathogenesis. *Acta Ophthalmol*. 2009;87 Thesis :1-20.
  8. Köksal Y, Kiratli H, Varan A, Akçören Z, Büyükpamukçu M. Primary lacrimal sac non-Hodgkin's lymphoma in a child. *Int J Pediatr Otorhinolaryngol*. 2005;69(11):1551-1553.
  9. Maharajah KR, Hussein A, Mohamad H, Khan SA, At L-S. Primary non-Hodgkins lymphoma of the lacrimal sac: mortality-related epiphora. *Orbit*. 2009;28(5):306-308.
  10. Venkitaraman R, George MK. Primary non Hodgkin's lymphoma of the lacrimal sac. *World J Surg Oncol*. 2007;5:127. doi:10.1186/1477-7819-5-127.
  11. Tan S, Ozcan AS, Akcay E, Sungu N. Sonographic Appearance of Primary Lacrimal Sac Lymphoma. *J Ultrasound Med*. 2011;30(4):574-575.
  12. Anderson NG, Wojno TH, Grossniklaus HE. Clinicopathologic findings from lacrimal sac biopsy specimens obtained during dacryocystorhinostomy. *Ophthalm Plast Reconstr Surg*. 2003;19(3):173-176.
  13. Nakata M, Matsuno Y, Katsumata N, et al. Histology according to the Revised European-American Lymphoma Classification significantly predicts the prognosis of ocular adnexal lymphoma. *Leuk Lymphoma*. 1999;32(5-6):533-543. doi:10.3109/10428199909058411.
  14. Vannata B, Stathis A, Zucca E. Management of the marginal zone lymphomas. *Cancer Treat Res*. 2015;165:227-249.
  15. Kiesewetter B, Raderer M. Antibiotic therapy in nongastrointestinal MALT lymphoma: a review of the literature. *Blood*. 2013;122(8):1350-1357.
  16. Cama GC, Vassallo P, Alberti D, et al. Primary non-Hodgkin's lymphoma of the lacrimal sac: a case report. *Tumori*. 88(6):530-531.
  17. Russell W, Herskovic A, Gessert D, Cohen JA, Rubenstein JB, Gregory SA. Ocular adnexal MALTomas: case series of patients treated with primary radiation. *Clin Adv Hematol Oncol*. 2013;11(4):209-214.
  18. Ohga S, Nakamura K, Shioyama Y, et al. Treatment Outcome of Radiotherapy for Localized Primary Ocular Adnexal MALT Lymphoma--Prognostic Effect of the AJCC Tumor-Node-Metastasis Clinical Staging System. *Anticancer Res*. 2015;35(6):3591-3597.
- 

## CONTACT

Mário Canastro

E-mail: mariocanastro@gmail.com