

# Delayed Resolution of Vitreomacular Traction Syndrome following Intravitreal Injection of Ocriplasmin

Jorge Moreira, Carla Teixeira, Rita Gonçalves, Pedro Coelho, Tiago Maio, Paula Tenedório  
Serviço de Oftalmologia do Hospital Pedro Hispano

## RESUMO

**Introdução:** A ocriplasmina é o primeiro tratamento farmacológico aprovado para o tratamento da tração vítreomacular (TVM), incluindo em casos de buracos maculares. A resolução da adesão vítreomacular é tipicamente observada nos 28 dias que se seguem à administração intravítrea da ocriplasmina, sendo que, na maioria dos doentes, a libertação da adesão vítreomacular ocorre nos primeiros 7 dias do tratamento.

**Métodos:** Descrevemos 2 casos clínicos de TVM sintomática, em que se observou libertação tardia da adesão vítreomacular após tratamento com ocriplasmina.

**Resultados:** Em ambos os casos, verificou-se libertação parcial da TVM ao final de 1 mês após administração da ocriplasmina. A resolução completa da TVM foi alcançada 4 e 2 meses, respetivamente, depois da injeção intravítrea de ocriplasmina.

**Conclusões:** Os casos descritos demonstram que o sucesso clínico da ocriplasmina na TVM pode ser observado para além dos 28 dias estabelecidos para alcançar o resultado final do tratamento com ocriplasmina. Apesar de tardia, a resolução completa da TVM pode ter sido facilitada pela libertação inicial da adesão vítreomacular pela ocriplasmina. A descrição destes casos sugere ser necessário maior seguimento após tratamento com ocriplasmina.

**Palavras-chave:** ocriplasmina; vitreólise; tração vítreomacular; interface vítreoretiniana; tomografia de coerência ótica.

## ABSTRACT

**Introduction:** Ocriplasmin is the first pharmacological treatment option approved for the treatment of vitreomacular traction (VMT), including when associated with macular holes. Resolution of vitreomacular adhesion is typically observed within 28 days of intravitreal ocriplasmin injection with the vast majority of patients experiencing vitreomacular release within the first 7 days of treatment.

**Methods:** We report two cases of symptomatic VMT, in which we observed delayed VMT release after intravitreal ocriplasmin.

**Results:** One month after treatment, there was only partial release of VMT in both cases. Complete VMT resolution was achieved in 4 and 2 months, respectively, following intravitreal ocriplasmin injection.

**Conclusion:** Our case reports showed that favorable results can be observed after the 28 days established to achieve the final outcome of ocriplasmin treatment and this may have been facilitated by the initial release of VMT by ocriplasmin. The description of the present case reports suggests that longer observation may be needed after intravitreal ocriplasmin.

**Key-words:** ocriplasmin; vitreolysis; vitreomacular traction; vitreoretinal interface; optical coherence tomography.

---

## INTRODUCTION

Vitreomacular traction (VMT) syndrome is a result of incomplete separation of the posterior vitreous with tractional distortion of the macula. Symptoms of VMT are associated with changes in macular structure, and include metamorphopsia, micropsia, photopsia, or diminished visual acuity.<sup>1</sup>

Until recently, the only treatment option available for VMT was vitrectomy. However, due to the well-known risks associated with surgery, vitrectomy is usually deferred until the disease has progressed to more advanced stages.

In recent years, there were significant advances in pharmacologic vitreolysis. Ocriplasmin is the first pharmacological treatment approved for VMT, including when associated with macular holes (MH  $\leq$  400  $\mu$ m diameter). Ocriplasmin is a recombinant, truncated form of human serine protease plasmin whose proteolytic activity works against fibronectin and laminin, components of the

vitreoretinal interface. In selected patients, ocriplasmin has demonstrated to be a safe and effective option to treat VMT and MH.<sup>2</sup> The resolution of vitreomacular adhesion has been typically observed within 28 days of intravitreal ocriplasmin injection.<sup>2</sup>

Herein, we report two cases of symptomatic VMT presenting a delayed vitreomacular release after treatment with ocriplasmin.

## CASE REPORTS

### CASE 1

A 76-year-old woman experienced decreased vision in her left eye (LE) over a period of two weeks. She had a history of previous vitrectomy of the right eye (RE) due to stage 3 MH.

Upon ophthalmological examination, her LE best corrected visual acuity (BCVA) was 6/10 (0.2 LogMAR).

Spectral-domain optical coherence tomography (SD-OCT) revealed VMT in the LE with a vitreous surface adhesion of 667 $\mu$ m (Figure 1a).

During an initial observation period of 6 months, visual acuity decreased to 5/10 (0.3 LogMAR). Because of this clinical worsening, a decision was made to perform an intravitreal ocriplasmin injection (0.125 mg/0.1 mL). At day 28, after ocriplasmin injection, SD-OCT showed incomplete VMT release (Figure 1b). A monthly follow-up was conducted. Complete VMT release occurred 4 months after ocriplasmin (Figure 1c) and vision improved to 10/10 (0.0 LogMAR).

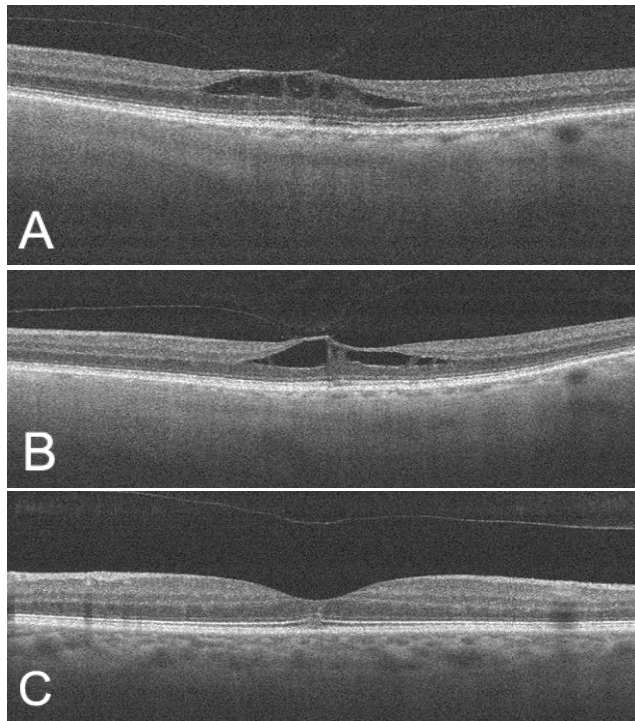


Figure 1 - Case 1

- (a) Initial Spectral Domain Optical Coherence Tomography (SD-OCT) showing focal vitreomacular traction (VMT) with intraretinal cysts.
- (b) 28 days after ocriplasmin injection, SD-OCT reveals partial VMT release.
- (c) Complete VMT release at the 4- month follow-up.

### CASE 2

A 60-year-old woman was referred due to decreased vision in her LE, with a BCVA of 4/10 (0.4 LogMAR). The patient's ocular history was unremarkable. SD-OCT demonstrated a focal VMT (Figure 2a). Following an initial observation period of 3 months, the patient was treated with an intravitreal ocriplasmin injection (0.125 mg/0.1 mL). One month after the ocriplasmin injection, the patient's

vision improved to 5/10 (0.3 LogMAR) and SD-OCT showed partial VMT release (Figure 2b). At the follow-up examination 2 weeks later, repeated SD-OCT showed similar findings. Complete VMT resolution was achieved 2 months following ocriplasmin (Figure 2c) and, at this time, her BVCA was 6/10 (0.2 LogMAR).

In both cases, there were no ocular adverse events following intravitreal injection of ocriplasmin.

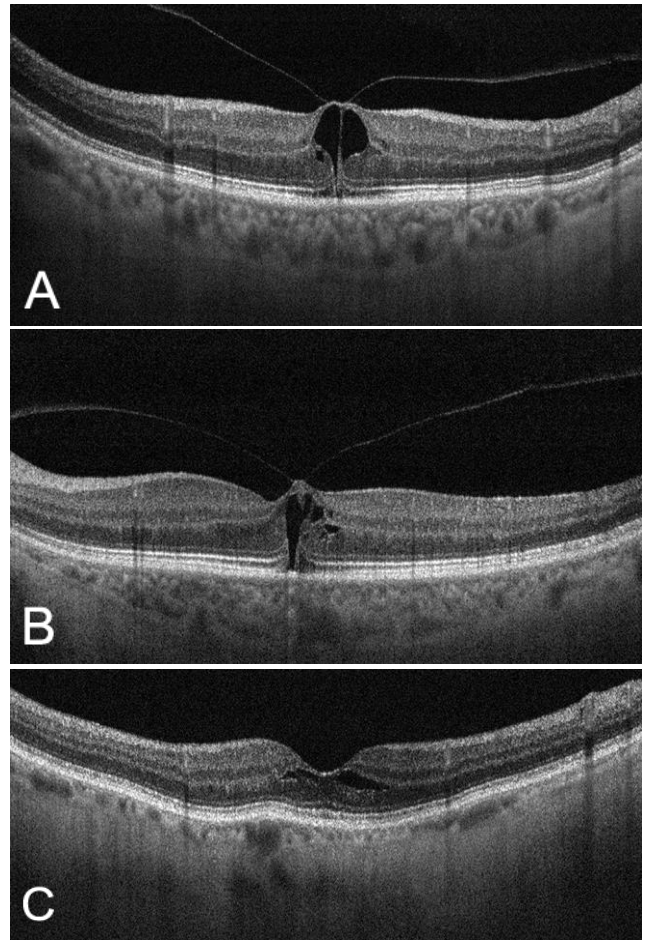


Figure 2 - Case 2

- (a) Initial SD-OCT revealing focal VMT (225  $\mu$ m diameter) with large intraretinal cysts, without a full-thickness macular hole.
- (b) SD-OCT one month after ocriplasmin shows partial VMT release.
- (c) Two months after ocriplasmin there was complete VMT resolution and retinal anatomy was re-established

## DISCUSSION

Our patients had VMT partial release on day 28, but complete resolution only occurred 4 and 2 months, respectively, after intravitreal ocriplasmin.

The Microplasmin for Intravitreal Injection Traction Release without Surgical Treatment (MIVI-TRUST) studies demonstrated the benefits of a single intravitreal ocriplasmin injection of 125 µg in patients with symptomatic vitreomacular adhesion. Overall, 26.5% of the patients achieved a resolution of vitreomacular adhesion by day 28 in comparison with 10.1% of placebo-injected eyes. The vast majority of patients experienced vitreomacular release within the first 7 days of treatment.<sup>2</sup> These findings are in agreement with the pharmacokinetics of ocriplasmin. Previous studies regarding pharmacokinetic properties of ocriplasmin showed that ocriplasmin concentrations in the vitreous decreased rapidly and the mean ocriplasmin concentrations in the vitreous at day 7 were below the lower limit of quantification (<0.27 µg/mL).<sup>3</sup>

Regarding these data, how is the delayed VMT resolution observed in our patients explained?

It is possible that in both cases, the partial release of VMT observed at day 28 might have provided relief of critical traction forces and promoted further improvements.

Recently, Jeng et al<sup>4</sup> reported three eyes with improvement in visual acuity and clinical symptoms despite only partial release of VMT over 28 days after ocriplasmin injection. All three patients experienced further improvement and one of them had complete vitreomacular release between the 3<sup>rd</sup> and 7<sup>th</sup> month after ocriplasmin and this may have been facilitated by the initial release of a critical portion of the VMT by ocriplasmin. Ocriplasmin resulted in an initial release of a decisive number of vitreous fibers and promoted a subsequent decrease in tensile forces at the fovea. The authors suggest that continued improvement may occur after ocriplasmin is eliminated from the eye.

Liang et al<sup>5</sup> described a patient with vitreomacular release that occurred within 28 days after ocriplasmin treatment but, with delayed macular hole closure. MH closure was achieved at 10 weeks post-treatment, demonstrating that vitreous degeneration and posterior vitreous detachment continue and extend wider once the process initiated.

Similar to previous reports, our experience shows that favorable results can be observed long after the 28 days

established to achieve the final outcome of ocriplasmin treatment, suggesting that one month might be too early for assessment of release of VMT, and longer follow-up may be needed after intravitreal ocriplasmin.<sup>6,7</sup>

## REFERENCES

1. Shao L, Wei W. Vitreomacular traction syndrome. *Chin Med J*. 2014; 127: 1566-1571.
2. Stalmans P, Benz MS, Gandorfer A, Kampik A, Girach A, Pakola S, et al. Enzymatic vitreolysis with ocriplasmin for vitreomacular traction and macular holes. *N Engl J Med*. 2012; 367: 606- 615.
3. Stalmans P, Girach A. Vitreous levels of active ocriplasmin following intravitreal injection: results of an ascending exposure trial. *Invest Ophthalmol Vis Sci*. 2013; 54: 6620- 6627.
4. Jeng KW, Bauml CR, Witkin AJ, Witkin SR, Wiegand TW, Waheed NK. Incomplete release of vitreomacular attachments after intravitreal ocriplasmin. *Ophthalmic Surg Lasers Imaging Retina*. 2015; 46: 271- 274.
5. Liang IC, Wang K, Chien HW, Lin SY. Early vitreomacular separation with delayed macular hole closure after ocriplasmin treatment. *Indian J Ophthalmol*. 2016; 64: 222- 224.
6. Abou Itaif S, Herbert L. Delayed full- thickness macular hole closure without vitreomacular traction release following ocriplasmin injection. 2015, doi: 10.1136/bcr-2015-212181.
7. Neves P, Matias I, Brito R, Santos M, Martins D. Ocriplasmina nas tracções vitreomaculares: a experiência do nosso serviço. *Oftalmologia*. 2016; 40 (1): 19-25.

---

## CONTACTO

Jorge Moreira  
Serviço de Oftalmologia - Hospital Pedro Hispano  
Rua Dr. Eduardo Torres  
4464-513, Senhora da Hora, Porto, Portugal  
E-mail: jorgemoreira.fm@gmail.com

Os autores não têm conflitos de interesse a declarar.

Os autores declaram que o trabalho não foi publicado, e cedem os direitos de autor à Sociedade Portuguesa de Oftalmologia