

Ankyloblepharon Filiforme Adnatum: Case Report and Literature Review

Anquilobléfaro Filifome Congénito: Relato de Caso e Revisão da Literatura

Maria João Vieira¹, Sónia Campos¹, Fausto Carvalheira¹, Henrique Arruda¹, Joana Martins¹, João Paulo Sousa^{1,2}

¹ Ophthalmology Department, Centro Hospitalar de Leiria, Leiria, Portugal

² Health Sciences Research Centre in Biomedicine, Faculty of Health Sciences, University of Beira Interior, Covilhã, Portugal

Received/Recebido: 31/3/2021

Accepted/Aceite: 13/3/2021

Published/Publicado: 11/3/2021

© Author(s) or their employer(s) and Oftalmologia 2021. Re-use permitted under CC BY-NC. No commercial re-use.

© Autor(es) ou seu(s) empregador(es) e Oftalmologia 2021. Reutilização permitida de acordo com CC BY-NC. Nenhuma reutilização comercial.

ABSTRACT

Ankyloblepharon filiforme adnatum (AFA) is a rare condition defined by a partial or complete fusion of eyelids, which can lead to privation amblyopia. A female newborn was referred for ophthalmological examination at her fourth day of life due to the presence of bilateral tissue adhesions between upper and lower eyelid. The obstetric history was unremarkable, except for an advanced maternal age. The baby underwent surgical excision of the bands at the level of each eyelid margin, without complications. Neonatal examination of the new born was normal, without systemic alterations or another eye abnormality.

Ankyloblepharon filiform adnatum can be associated with systemic syndromes and the treatment should be performed as soon as the diagnosis is done.

KEYWORDS: Eye Abnormalities/diagnosis; Eye Abnormalities/surgery; Eyelids/surgery; Infant, Newborn

RESUMO

O anquilobléfaro filiforme congénito (AFC) é uma condição rara caracterizada por uma fusão palpebral que pode ser parcial ou completa, com risco de ambliopia de privação. Um recém-nascido do sexo feminino com quatro dias de vida foi referenciado ao serviço de Oftalmologia por adesão palpebral bilateral. Para além da idade materna avançada, não existiam outros antecedentes obstétricos relevantes. Foi realizada uma excisão cirúrgica das adesões palpebrais ao nível da margem palpebral, sem intercorrências. O exame neonatal do recém-nascido era normal, sem alterações sistémicas ou outras anomalias oftalmológicas. O AFC pode estar associado a síndromes sistémicas e o tratamento deve ser realizado assim que o diagnóstico for estabelecido.

PALAVRAS-CHAVE: Anomalias Congénitas do Olho/diagnóstico; Anomalias Congénitas do Olho/cirurgia; Pálpebras/cirurgia; Recém-Nascido

INTRODUCTION

Ankyloblepharon filiforme adnatum (AFA) was first described by Josef von Hasner in 1881¹ as a congenital abnormality with partial or complete adhesion of the ciliary edges of the upper and lower eyelids. The incidence of AFA is 4.4 per 100 000 newborns.² Fusion of eyelids is a normal stage in fetal development, but it is abnormal at birth. The developing eyelids fuse during the ninth week of gestation and remain fused until the fifth month. Between the fifth and the seventh month of gestation, a spontaneous separation of upper and lower eyelid happens.³ A disruption of this process can occur, due to a temporary arrest of the epithelial growth,⁴ or an abnormally rapid proliferation of mesoderm,⁴ or a combination of the two which allows union of epithelialized mesenchyme at certain points,⁴ or even due to failure of apoptosis at a critical stage of eyelid development.⁵ Usually, AFA constitutes a solitary malformation of sporadic occurrence.⁶ However, AFA may be associated with multisystem developmental disorders or ophthalmological alterations.

CASE REPORT

A Caucasian female baby was born at 39 weeks' and 3 days' gestation by elective vaginal delivery after an uneventful pregnancy, weighing 2870 g, measuring 47.50 cm of height and 33.40 cm of cephalic perimeter, with an APGAR index of 10/10/10. The mother was a healthy 40-year-old female with one successful gestation 5 years before and out of non-consanguineous relation. There was no family history of congenital abnormalities, the sibling's new born was healthy. On detailed ocular examination of the new born at four days of age, there was a single band of extensile tissue between upper and lower eyelid arising from the grey line, with the limited interpalpebral aperture, in both eyes (Fig. 1). The detailed neonatal examination was normal and did not reveal any other congenital abnormality. Therefore, the adhesions were removed with a surgical blade near each eyelid margin, under local anesthesia. Pupillary light reflex, ocular motility, biomicroscopy and fundoscopy were normal. At the follow-up visit, two weeks postoperatively, no ophthalmological abnormality was noted (Fig. 2). The eyelid opening was normal, as well as the upper and lower eyelid anatomy. The new born was healthy, without detection of any systemic anomaly during the Neonatology appointments.

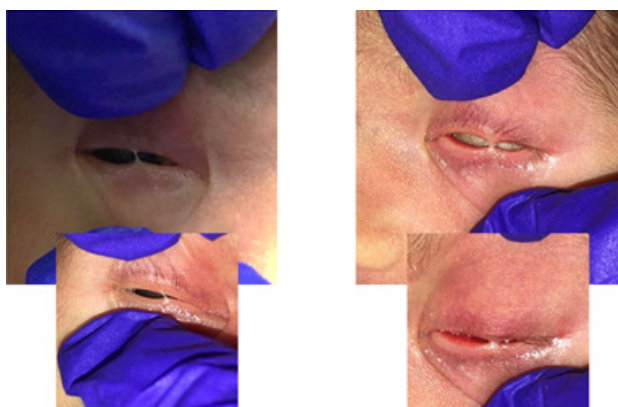


Figure 1: Photograph of the new born showing extensile bands of tissue connecting the eyelid margins of the right and left eye, with Bell's phenomenon in the right eye.

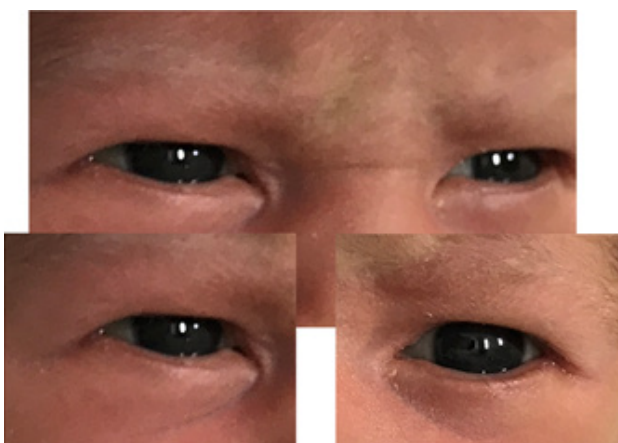


Figure 2: Photograph of new born after the treatment, showing a normal eyelid aperture and a normal external ocular aspect.

DISCUSSION

AFA can present as an isolated ocular anomaly or as a manifestation of a multisystem syndrome. Case reports of AFA, published from 1979 to 2021 in indexed journals, are summarized in Table 1.

Author	Year of publication	Journal	Number of AFA cases	Unilateral / Bilateral	Number of bands	Obstretic alterations	Ophthalmological alterations	Systemic alterations / Syndromes
Williams <i>et al</i> ⁹	2007	Arch Dis Child	2	Unilateral	Single	Maternal smoking, methadone use, Intrauterine growth retardation (IGR)	0	Edwards' Syndrome
				Bilateral	Single	AFA in familiar relatives	0	0

Akkermans <i>et al</i> ¹⁰	1979	Br J Ophthalmol	2	Bilateral	2	AFA, syndactyly in familiar relatives	0	Cleft lip and palate
				Bilateral	?	AFA, syndactyly in familiar relatives	0	Bilateral syndactyly
Chakraborti <i>et al</i> ¹¹	2014	Middle East Afr J Ophthalmol	2	Bilateral	Several	0	0	Abnormal tuft of hair in the back
				Bilateral	Several	0	0	0
Malek <i>et al</i> ¹²	2019	Tunis Med	2	Bilateral	Several	0	0	Cleft lip without cleft palate
				Bilateral	Single	Parent consanguinity	0	CHAND Syndrome
Alami <i>et al</i> ¹³	2013	Pan Afr Med J	1	Unilateral	Single	0	0	0
Clark <i>et al</i> ⁷	1985	Br J Ophthalmol	1	Bilateral	Single / 2	0	0	Edwards' Syndrome
Evans <i>et al</i> ⁴	1990	J Med Genet	3	Unilateral	Single	IGR		Edwards' Syndrome
				Unilateral	2	?	?	
				Bilateral	Single	0		
Kuruvilla <i>et al</i> ¹⁴	2016	Ind J Ophthalmol	1	Unilateral	Single	Parent consanguinity (Third degree)	0	AEC / Hay-Wells syndrome

AFA= ankyloblepharon filiforme adnatum, IGR = intrauterine growth retardation, CHAND = curly hair-ankyloblepharon-nail dysplasia, AEC = ankyloblepharon-ectodermal dysplasia-clefting

AFA was initially subdivided in group I (without associated abnormalities), group II (alterations in cardiac or central nervous system), group III (ectodermal syndrome) and group IV (clef lip and/or cleft palate).⁷ Other associations may include hydrocephalus, meningocele, imperforate anus, bilateral syndactyly, infantile glaucoma with iridodogoniodysgenesis,⁸ cardiac problems such as patent ductus arteriosus and ventricular septal defects.⁹

An early separation of the fibrous adhesions is the standard treatment for AFA, performed with or without local anesthesia and since it is a fibrovascular connective tissue⁸ there is no major bleeding.

This report demonstrates the simplicity in treating the condition and the importance of early intervention to avoid the development of amblyopia.

CONCLUSION

AFA is a very rare condition that requires screening of possible systemic associations, some of them potentially life-threatening. It is important to have a multidisciplinary team for the management of AFA, including pediatricians, ophthalmologists, oral and maxillofacial surgeons, dermatologists, geneticists and psychologists to provide an adequate treatment of patients and family support.

ETHICAL DISCLOSURES

Conflicts of Interest: The authors have no conflicts of interest to declare.

Financing Support: This work has not received any

contribution, grant or scholarship.

Confidentiality of Data: The authors declare that they have followed the protocols of their work center on the publication of data from patients.

Patient Consent: Consent for publication was obtained.

Provenance and Peer Review: Not commissioned; externally peer reviewed.

RESPONSABILIDADES ÉTICAS

Conflitos de Interesse: OOs autores declaram a inexistência de conflitos de interesse na realização do presente trabalho.

Fontes de Financiamento: Não existiram fontes externas de financiamento para a realização deste artigo.

Confidencialidade dos Dados: Os autores declaram ter seguido os protocolos da sua instituição acerca da publicação dos dados de doentes.

Consentimento: Consentimento do doente para publicação obtido.

Proveniência e Revisão por Pares: Não comissionado; revisão externa por pares.

REFERENCES

- Hasner V. Ankyloblepharon filiforme adnatum. Z Heilkol. 1888;2:429.
- Koubek M, Strakošová K, Timkovič J, Grečmalová D, Orlíková A, Burčková H, et al. A rare form of ankyloblepharon filiforme adnatum associated with the Hay-Wells syndrome and a c.1709T>C mutation on

- the TP63 gene. *Ophthalmic Genet.* 2018;39:251-4. doi: 10.1080/13816810.2017.1401091.
3. Sharkey D, Marlow N, Stokes J. Ankyloblepharon Filiforme Adnatum. *J Pediatr.* 2008;152:4:594. doi:10.1016/j.jpeds.2007.12.051
 4. Evans DG, Evans ID, Donnai D, Lindenbaum RH. Ankyloblepharon filiforme adnatum in trisomy 18 Edwards syndrome. *J Med Genet.* 1990;27:720-1. doi:10.1136/jmg.27.11.720
 5. Mohamed YH, Gong H, Amemiya T. Role of apoptosis in eyelid development. *Exp Eye Res.* 2003;76:115-23. doi:10.1016/S0014-4835(02)00269-5
 6. Gruener AM, Mehat MS. A newborn with ankyloblepharon filiforme adnatum: A case report. *Cases J.* 2009;2:1-2. doi:10.4076/1757-1626-2-8146
 7. D I CLARK AND A PATTERSON. Ankyloblepharon filiforme adnatum in trisomy 18 (Edwards's syndrome). *Br J Ophthalmol.* 1985;69:471-473.
 8. Scott M, Richard J FB. Ankyloblepharon filiforme adnatum associated with infantile glaucoma and iridodysgenesis. *J Pediatr Ophthalmol Strabismus.* 1994;31:93-5.
 9. Williams MA, White ST, McGinnity G. Ankyloblepharon filiforme adnatum. *Arch Dis Child.* 2007;92:73-4. doi:10.1136/adc.2006.103069
 10. Akkermans CH, Stern LM. Ankyloblepharon filiforme adnatum. *Br J Ophthalmol.* 1979;63:129-31. doi: 10.1136/bjo.63.2.129.
 11. Chandana Chakraborti, Kritika Pal Chaudhury, Jayanta Das and AB. Ankyloblepharon Filiforme Adnatum: Report of Two Cases. *Middle East Afr J Ophthalmol.* 2014;21:200-2.
 12. Malek I, Mekni M, Sayadi J, Bezzine A, Zghal I, Nacef L. Ankyloblepharon filiform adnatum: Beyond the eye. *Tunis Med.* 2019;97:822-5.
 13. Alami B, Maadane A, Sekhsoukh R. Ankyloblepharon filiforme adnatum: A case report. *Pan Afr Med J.* 2013;15:1-3. doi:10.11604/pamj.2013.15.15.2209
 14. Kuruvilla, Elizabeth. Simha A. A rare variant of ankyloblepharon filiforme adnatum associated with skin hypopigmentation: A case report from South India. *Indian J Ophthalmol.* 2016;64:241-243.



***Corresponding Author/
Autor Correspondente:**

Maria J Vieira

R. de Santo André

2410-197 Leiria

Portugal

vieiramjp@gmail.com



ORCID: 0000-0001-9554-3427