

# Subfoveal Deposits secondary to Idiopathic Epiretinal Membranes - same surgical technique but different clinical outcomes in the same patient

Maria Luísa Colaço<sup>1,5</sup>, Rita Pinto<sup>2,6</sup>, Sara da Silva Pereira<sup>3,6</sup>,  
Sandra Barrão Pinto<sup>1,7</sup>, João Nascimento<sup>4,7</sup>

<sup>1</sup>Instituto de Oftalmologia Dr. Gama Pinto - Lisboa

<sup>2</sup>Moorfields Eye Hospital NHS, Londres

<sup>3</sup>Centro Hospitalar Oeste; Hospital de Caldas da Rainha

<sup>4</sup>Centro Hospitalar Lisboa Norte - Hospital Beatriz Ângelo - Loures

<sup>5</sup>Internato Complementar de Oftalmologia

<sup>6</sup>Assistente Hospitalar

<sup>7</sup>Assistente Hospitalar Graduado

## RESUMO

**Objetivo:** Relatar um caso de depósitos subfoveais bilaterais associados a membrana epirretiniana com diferentes resultados morfológicos e funcionais, apesar do mesmo tratamento.

**Métodos:** Doente de 67 anos, sexo masculino, apresentou-se com perda visual bilateral progressiva e metamorfópsia associada a membrana epirretiniana bilateral. A acuidade visual era 20/25 no olho direito e 20/80 no olho esquerdo. O HD-OCT confirmou a presença de uma membrana epirretiniana bilateral associada a depósitos subfoveais amarelos localizados acima do epitélio pigmentado da retina (EPR) e desorganização da retina externa. Foi realizada uma injeção subtenoniana de triamcinolona seguida de vitrectomia e remoção da membrana epirretiniana no olho esquerdo, este último procedimento foi também realizado no olho direito, um ano depois.

**Resultados:** O olho esquerdo mostrou uma excelente resposta ao tratamento com uma acuidade visual quatro meses após a cirurgia de 20/20. No olho direito - inicialmente com a melhor visão - o depósito subfoveal teve resolução espontânea antes da cirurgia e a visão final foi 20/80.

**Conclusões:** A história natural dos depósitos subfoveais associados a membranas epirretinianas é ainda pouco compreendida. Consideramos este relatório como evidência de que depósitos subfoveais, às vezes vistos em associação a membranas epirretinianas, podem sinalizar importantes alterações no metabolismo do complexo fotorreceptores/EPR. Pode haver uma fase inflamatória inicial, em que a cirurgia precoce conduz a uma boa recuperação visual, seguida por uma fase posterior em que os fotorreceptores já não podem regenerar e recuperar, mesmo com a realização da cirurgia. Uma intervenção cirúrgica precoce parece assim ser apropriada nestes casos.

## Palavras-chave

Membrana epirretiniana, fóvea central, fotorreceptores, epitélio pigmentado da retina, vitrectomia.

## ABSTRACT

**Objectives:** To report a case of bilateral subfoveal deposits associated with bilateral epiretinal membrane with different morphologic and functional outcomes in spite of the same treatment.

**Methods:** A 67-year old man presented with progressive bilateral visual loss and metamorphopsiae associated with bilateral epiretinal membrane. Vision was 20/25 in the right eye and 20/80 in the left eye. The HD-OCT confirmed the presence of a membrane associated with yellow subfoveal deposits above the retinal pigment epithelium (RPE) and disorganization of the outer retina. A subtenon triamcinolone injection followed by pars plana vitrectomy and membrane peeling were performed in the left eye; and the latter procedure was also carried out in the right eye 1 year later.

**Results:** The left eye showed an excellent response to treatment with a visual acuity four months postoperatively of 20/20. In the right eye - initially with the better vision - the subfoveal deposits resolved spontaneously prior to surgery and the final visual outcome was 20/80.

**Conclusions:** The natural history of subfoveal deposits associated with epiretinal membranes is still poorly understood. We consider this report as evidence that subfoveal deposits sometimes seen with epiretinal membranes may signal important changes in photoreceptor and RPE metabolism. There may be an initial inflammatory stage where prompt surgery leads to good visual recovery followed by a later stage where photoreceptors can no longer regenerate and recover despite surgical repair. An early surgical intervention would thus seem appropriate in these cases.

## Keywords

Epiretinal membrane, fovea centralis, photoreceptor cells, retinal pigment epithelium, vitrectomy.

---

## INTRODUCTION

Idiopathic Epiretinal Membrane (ERM) emerges from proliferation of glial cells that gain access to the retinal surface through breaks in the internal limiting membrane<sup>1</sup>. They are not associated with retinal tears, vascular occlusions, trauma or any other underlying ocular pathology.

Concomitant posterior vitreous detachment (PVD) is very common to the point that it is considered crucial in ERM pathophysiology. They are bilateral in 10-20% of cases. The prevalence of this pathology has been estimated to be 2% in patients less than 60 years of age and 12% beyond 70 years old<sup>2</sup>. Clinical signs and symptoms include progressive visual loss and metamorphopsia. The standard treatment is pars plana vitrectomy and peeling of the membrane. Additional removal of the inner limiting membrane (ILM) is also advocated, in that it seems to bring the advantage of removing the scaffolding for ERM recurrence. Postoperative visual outcomes are generally good however a group of patients shows minimal or no improvement in visual acuity.

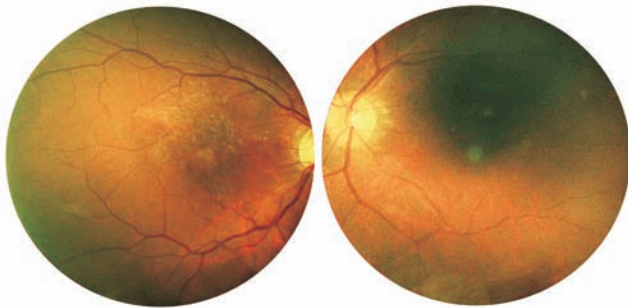
The association of subfoveal deposits with idiopathic ERMs has been described before<sup>1,2</sup>, but their meaning is as yet unclear. We present a case of bilateral yellow subfoveal

deposits associated with bilateral epiretinal membrane that showed different functional and morphologic outcomes in spite of the same surgical procedure.

## CASE REPORT

A 67 year-old caucasian male was referred to the department of Retina and Vitreous of the Dr. Gama Pinto Institute of Ophthalmology in Lisbon, Portugal, due to complaints of progressive bilateral visual loss, more severe in the left eye. He had a history of type 2 Diabetes mellitus diagnosed 2 years prior and treated with oral antidiabetics, with good metabolic control. No other relevant medical history was present, as well as no relevant ophthalmic history including retinal tears, vascular occlusions or laser treatment. Best corrected visual acuity was 20/25 in the right eye (RE) and 20/80 in the left eye (LE). Amsler grid revealed significant metamorphopsia in the LE.

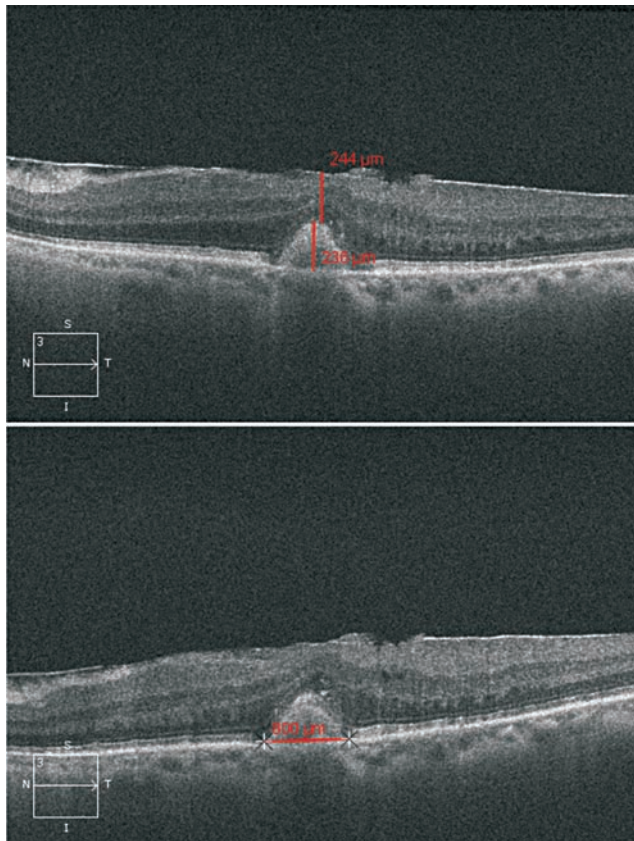
Fundoscopy showed a change of the foveal reflex in both eyes (OU) with bilateral yellow circular lesions in the fovea (Figure 1). These lesions were well circumscribed with approximately 230 microns in height (Figure 2). Optic disc and vessels had a normal appearance and no diabetic



**Fig. 1 |** Retinography of the right and left eyes showing central subfoveal yellow deposits.

retinopathy was present. The peripheral retina was normal and no laser scars were seen in both eyes.

HD-OCT (Cirrus HD-OCT by Carl Zeiss Meditec®) with horizontal and vertical cuts over the fovea showed a bilateral hyperreflective epiretinal membrane with perifoveal retinal thickening (Central Retinal Thickness was 464 microns in the RE and 379 microns in the LE), loss of the foveal depression and bilateral dome-shaped hyperreflective deposits located above the RPE, at the level of the outer retina.

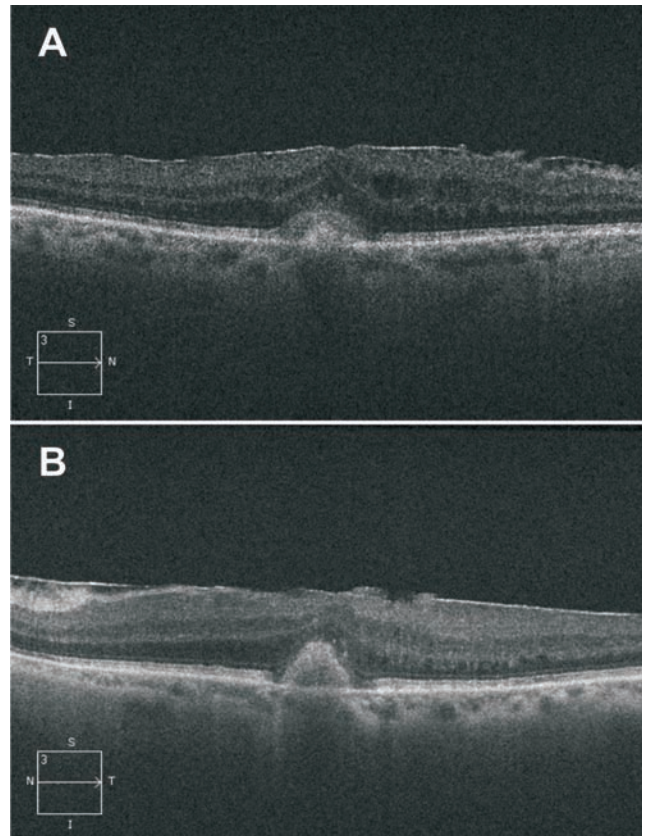


**Fig. 2 |** HD-OCT of LE at diagnosis with subfoveal deposit measuring 236 x 800 microns.

There seemed to be some disorganization of the plexiform and nuclear outer layers OU; and the IS/OS layer showed areas of irregularity in the right eye (RE).

In the LE the IS/OS junction (line representing the junction of the photoreceptors inner segment with the outer segment) formed a normal appearing continuous line.

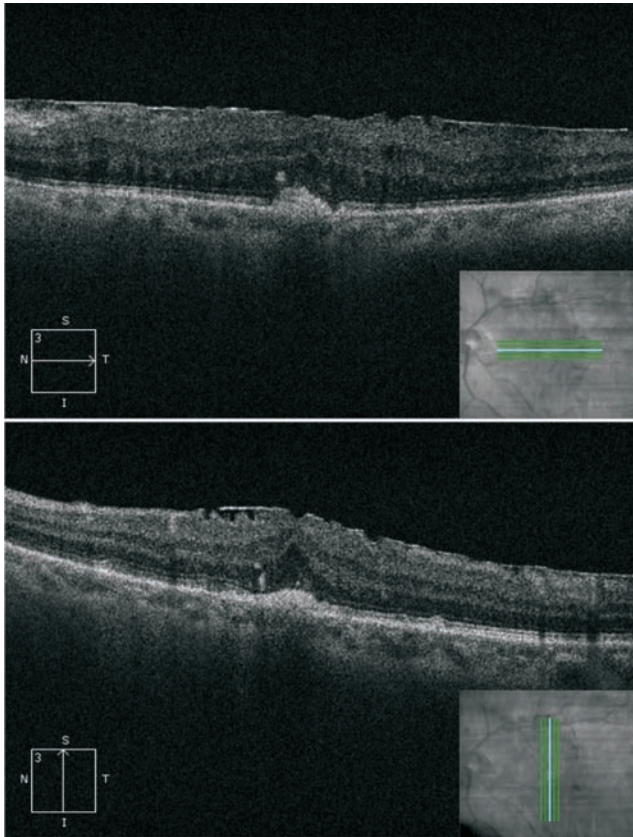
The retinal pigment epithelium (RPE) hyperreflective layer was normal and no hyporeflective spaces suggestive of subretinal fluid were present OU (Figure 3).



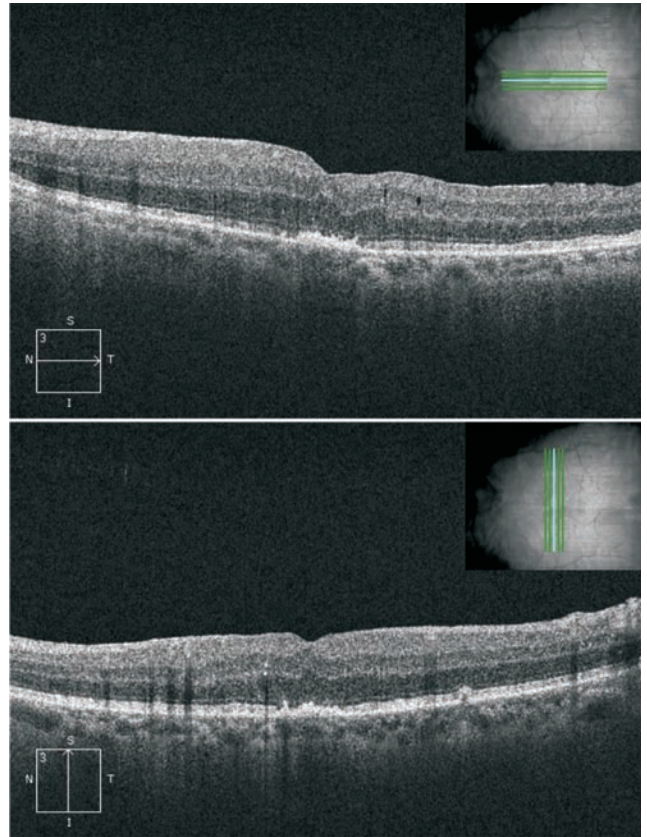
**Fig. 3 |** HD-OCT showing ERM OU with bilateral subfoveal deposits at diagnosis, horizontal scans. A – right eye; B – left eye.

Due to symptom worsening a subtenon triamcinolone injection was given in the LE. One month later a significant reduction in the subfoveal deposits was noted and visual acuity improved to 20/60 (Figure 4).

Subsequently, the same eye underwent surgery with phacoemulsification, posterior chamber intraocular lens (IOL) implantation, 25 Gauge pars plana vitrectomy and membrane peel with ILM peel. Four months post operatively visual acuity was 20/20, subjective metamorphopsia had significantly improved and HD-OCT showed some



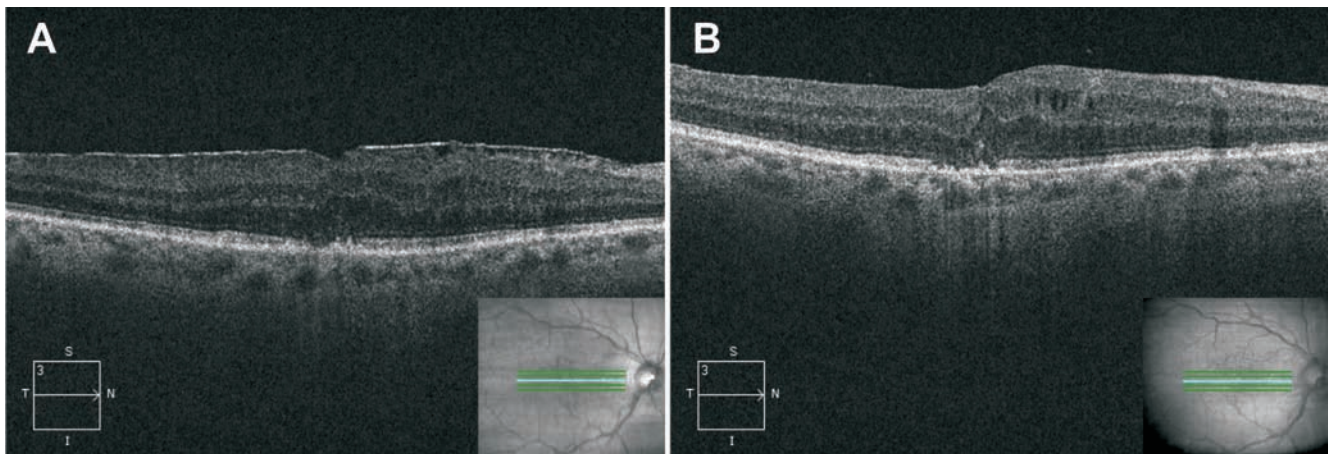
**Fig. 4 |** HHD-OCT of LE after subtenon triamcinolone injection, horizontal and vertical scans.



**Fig. 5 |** HD-OCT of LE 4 months post operatively, horizontal and vertical scans.

recovery of the foveal contour; normalization of retinal thickness; total disappearance of the subfoveal deposits; and normalization of the configuration of the outer retinal layers (Figure 5).

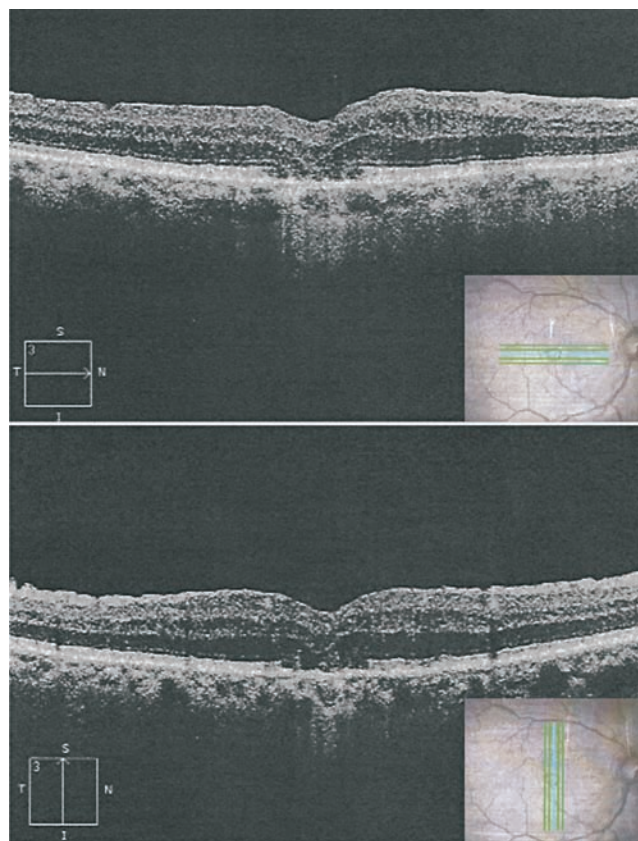
During this time visual acuity in the RE gradually deteriorated to 20/80 and HD-OCT showed spontaneous resolution of the subfoveal deposits, with the appearance of intraretinal edema (Figure 6A). The same surgery was then



**Fig. 6 |** A) Spontaneous resolution of subfoveal deposit in the RE preoperatively. B) HD-OCT of the RE 4 months postoperatively.

performed in the RE (phacoemulsification, posterior chamber IOL implantation, 25 Gauge pars plana vitrectomy and membrane and ILM peeling) one year later relative to the LE, by the same surgeon, without any intraoperative complications, using the same membrane dye (Brilliant Blue), the same number of times (twice). Four months postoperatively visual acuity in the RE was unchanged at 20/80. HD-OCT showed a persisting abnormal foveal contour, and persistence of slight cystic intraretinal edema, as well as of the distortion of the outer retinal layers, IS/OS line, and RPE-Bruch's membrane complex seen preoperatively (Figure 6B). One year postoperatively the right eye's intraretinal edema had spontaneously reabsorbed, central foveal thickness was 342 microns and foveal contour was regained in part, but there was disruption of the external layers of the retina with subfoveal loss of the IS/OS line and atrophy of the RPE (Figure 7).

Visual outcomes remained at 20/80 in the RE and at 20/20 in the LE at the last follow-up visit (1 year after the second surgery).



**Fig. 7** | HD-OCT of the right eye 1 year postoperatively, horizontal and vertical scans.

## DISCUSSION

Recent studies point to the conclusion that ERM-associated subretinal deposits are not related to adult vitelliform macular dystrophy (AVMD) since they are usually unilateral, much smaller in size, have a different behaviour over time, and are seen much more frequently than AVMD<sup>1,3,4</sup>.

Dupas et al published a case series of 15 eyes with subfoveal yellow deposits associated with ERM, where these lesions are shown to have short wavelength hyperautofluorescence.

Findings from this series seem to suggest that subfoveal deposits may be significantly associated with higher age but do not necessarily represent a poor prognostic factor for postoperative visual course. The authors postulate that the yellow subfoveal deposits represent or appear as a consequence of altered photoreceptor and RPE metabolism, their hyperautofluorescent properties being due to the accumulation of photoreceptor debris.

This debris would in turn result from limited phagocytosis from misalignment of photoreceptors with the RPE<sup>1</sup>; but this condition would and seems to be reversible after restoration of normal retinal architecture with ERM removal.

In another series by Gomes *et al* 9 patients with subfoveal yellow pigmented deposits were described.

These deposits were associated with longstanding ERM, and with evidence of outer retinal disorganization on OCT. In this series, however, the subfoveal lesions were hypoautofluorescent<sup>2</sup>.

Also, patients in this series had a poor postoperative visual outcome. This led the authors to suggest that these longstanding membranes may be associated with altered photoreceptor-RPE metabolism, culminating in cellular disorganization and, eventually, in irreversible photoreceptor loss, as heralded by the hypoautofluorescent changes. It would therefore seem to make sense to advocate an early surgery for eyes with such changes on autofluorescence imaging.

Our patient presented with bilateral ERM-associated yellow subfoveal deposits that showed different functional and morphologic outcomes in spite of the same surgical procedure, performed by the same surgeon, in each eye.

The LE, which had a larger subfoveal deposit to start with, improved with topical corticosteroids, and total resolution of the deposit occurred after surgery, with an excellent visual outcome. In the RE surgery was carried out at a later date due to a better initial visual acuity and fewer symptoms. However, the subfoveal deposit spontaneously disappeared before the surgical procedure; and postoperatively this eye had a poorer morphological and functional recovery.

We are thus encouraged to speculate that this is further evidence towards the hypothesis that subfoveal ERM-associated deposits may go through 2 fundamental stages: an early stage at which there is compromised RPE-photoreceptor metabolism, with accumulation of debris, which is reversible upon prompt restoration of normal architecture and release of ERM-induced traction; and a later stage with irreversible damage to the RPE photoreceptor complex. At the earlier stage metabolic changes in RPE and photoreceptors, caused by edema and tangential forces from the ERM, can lead to photoreceptor suffering probably evidenced by hyperautofluorescence. Surgery in this stage with membrane peeling, normalization of retinal thickness and alignment can allow for RPE phagocytosis of the deposit and debris with restoration of normal retinal physiology and function<sup>5</sup>. In later stages these longstanding anomalies in retinal metabolism lead to irreversible photoreceptor death, probably by apoptosis, and hypoautofluorescence is seen<sup>3,6</sup>. The deposit may even disappear due to retinal atrophy and lowering of metabolic functions, but even though the membrane is peeled and the intraretinal edema resolved, visual function can no longer be restored.

Although we have no autofluorescent imaging for our patient, in accordance with this hypothesis and the previous literature, one would have expected the lesions in his LE to be hyperautofluorescent and the lesions in the RE hypoautofluorescent.

We conclude that OCT and autofluorescence may thus be of high value in evaluating these cases in order to identify patients that may benefit from early surgery.

## REFERENCES

1. Dupas B, Tadayoni R, Erginay A, Massin P, Gaudric A. Subfoveal Deposits Secondary to Idiopathic Epiretinal Membranes. *Ophthalmology* 2009;116:1794–1798.
2. Gomes NL, Corcostegui I, Fine HF, Chang S. Subfoveal Pigment Changes in Patients with Longstanding Epiretinal Membranes. *Am J Ophthalmol* 2009;147:865–868.
3. Spaide RF, Noble K, Morgan A, Bailey Freund K. Vitelliform Macular Dystrophy. *Ophthalmology* 2006;113:1392–1400.
4. Querques G, Forte R, Querques L, Massamba N, Souied E H. Natural Course of Adult-Onset Foveomacular Vitelliform Dystrophy: A Spectral-Domain Optical Coherence Tomography Analysis. *Am J Ophthalmol* 2011;152:304–313.
5. Mitamura Y, Hirano K, Baba T, Yamamoto S. Correlation of visual recovery with presence of photoreceptor inner/outer segment junction in optical coherence images after epiretinal membrane surgery. *Br J Ophthalmol* 2009;93:171–175.
6. Imamura Y, Fujiwara T, Spaide RF. Fundus Autofluorescence and Visual Acuity in Central Serous Chorioretinopathy. *Ophthalmology* 2011;118:700–705.
7. Benhamou N, Souied EH, Zolf R, Coscas F, Coscas G, Soubrane G. Adult-onset Foveomacular Vitelliform Dystrophy: A Study by Optical Coherence Tomography. *Am J Ophthalmol* 2003;135:362–367.
8. Skalka HW. Vitelliform macular lesions. *Br J Ophthalmol* 1981;65:180–183.
9. Saito W, Yamamoto S, Hayashi M, Ogata K. Morphological and functional analyses of adult onset vitelliform macular dystrophy. *Br J Ophthalmol* 2003;87:758–762.

Trabalho apresentado nos: 55º Congresso Português de Oftalmologia – 6 a 8 de Dezembro de 2012; 14<sup>th</sup> EURETINA Congress London – 11 a 14 de Setembro de 2014.

Trabalho não submetido para outras publicações cedendo os autores os seus direitos à SPO.

## CONTACTO

Maria Luisa Colaço  
Avenida Estados Unidos da América nº 73 8º esquerdo  
1700-165 Lisboa  
luisacolaco@gmail.com