

Expression of Focal Adhesion Kinase in Retinoblastoma

Arnaldo Dias-Santos^{1,2}, Vasco Bravo-Filho^{2,3}, Dana Faingold², Alexandre Odashiro⁴,
Patrícia Odashiro², Lisa Jagan², Matthew Ballazsi², Miguel N. Burnier Jr^{2,3}

¹Interno do Internato Complementar em Oftalmologia no Departamento de Oftalmologia do Centro Hospitalar de Lisboa Central – CHLC – Lisboa, Portugal

²Henry C. Witelson Ocular Pathology Laboratory, Department of Pathology, McGill University Health Center, Montreal, Quebec, Canada

³Departamento de Oftalmologia, Universidade Federal de São Paulo – UNIFESP – São Paulo, Brasil

⁴Assistant Professor, Department of Pathology and Molecular Medicine, McMaster University, Canada

RESUMO

Introdução: As cinases de adesão focal (CAF) são tirosina-cinases citoplasmáticas, não recetoras, importantes e no processo oncogénico. O objetivo deste estudo é avaliar o nível de expressão das CAF no retinoblastoma e correlacioná-la com fatores prognósticos histopatológicos.

Material e Métodos: a expressão de CAF e da sua forma ativa fosforilada - CAF [pY397] - foi avaliada em vinte espécimes de retinoblastomas por imuno-histoquímica. A imunorreatividade foi correlacionada com a idade, grau de diferenciação do tumor e com a presença ou ausência de invasão da câmara anterior, coróideia, vítreo e nervo ótico.

Resultados: A avaliação histopatológica revelou 55% de tumores pouco diferenciados, 30% moderadamente diferenciados e 15% bem diferenciados. A invasão da câmara anterior foi observada em 80% dos casos, da coróide em 35%, do vítreo em 25% e do nervo ótico em 70%. Vinte e cinco por cento dos tumores apresentaram uma forte expressão de CAF [pY397], 60% expressão moderada e 15% expressão fraca. Relativamente à imunorreatividade para CAF não fosforilada, 20% dos tumores revelaram-se fortemente positivos, 75% moderadamente positivos e 5% fracamente positivos. Não houve correlação significativa entre a expressão destas moléculas e a idade ou fatores de prognóstico histopatológicos.

Conclusão: Este estudo foi o primeiro a avaliar a expressão desta molécula no retinoblastoma. Todos os espécimes apresentaram expressão de CAF ou CAF [pY397], tendo mais de 80% exibido expressão moderada ou forte de ambas. Os resultados sugerem uma potencial relação destas moléculas com o processo oncogénico, abrindo perspectivas relativamente a novas estratégias de intervenção terapêutica no retinoblastoma.

Palavras-chave

Cinases de adesão focal; imuno-histoquímica; retinoblastoma.

ABSTRACT

Introduction: Focal adhesion kinase (FAK) is a non-receptor tyrosine kinase and plays an important role in tumorigenesis. The purpose of this study was to evaluate the expression of FAK in retinoblastoma and to correlate with histopathological prognostic factors.

Material and Methods: The expression of FAK and phosphorylated FAK (FAK[pY397]) was assessed in 20 retinoblastomas specimens via immunohistochemistry. Immunoreactivity was correlated with age, the degree of tumor differentiation and with the invasion into the anterior chamber, choroid, vitreous and optic nerve.

Results: 55% of the tumors were poorly differentiated, 30% were moderately and 15% were well differentiated. Anterior chamber invasion was observed in 80% of cases, choroidal invasion in 35% of cases, while optic nerve invasion and vitreous seeding were present in 70% and 25%, respectively. Twenty five percent of the tumors showed strong expression for FAK[pY397], 60% moderate and 15% weak. Immunostaining for FAK revealed 20% strongly positive tumors, 75% moderately positive and 5% weakly positive. There was no significant correlation between FAK or FAK[pY397] expression and age or histopathological prognostic factors.

Conclusion: This study was the first to assess the role of FAK in retinoblastoma. FAK and FAK[pY397] were expressed in all the specimens and more than 80% of the cases presented a moderate or strong expression of both these molecules. The overexpression of FAK in retinoblastoma supports a potential role for FAK in its pathogenesis, opening prospects for new strategies for therapeutic intervention in this tumor.

Key-words

Focal adhesion kinase; immunohistochemistry; retinoblastoma.

INTRODUCTION

Retinoblastoma (RB) is the most common intraocular malignancy of childhood, representing 3% of the malignant neoplasms that occur in patients younger than 15 years^{1, 2} and less than 1% in all pediatric groups³. It has a worldwide incidence of one case per 15000–20000 live births, which corresponds to about 9000 new cases every year.⁴ Mortality rates range from 40–70% in Asia and Africa, to 3–5% in Europe, Canada, and the USA⁵⁻¹⁰. Treatment modalities for RB include: enucleation, transpupillary thermotherapy, cryotherapy, laser photocoagulation, chemotherapy, and radiotherapy. The indication for each method depends on the size, location and extension of the disease¹¹. In an attempt to preserve vision and avoid mutilation procedures like enucleation, chemotherapy has assumed a pivotal role in the treatment of RB^{12,13}. However, tumor chemoresistance and local RB recurrence continues to jeopardize treatment success, even with the use of multidrug regimens¹⁴⁻¹⁶. By identifying new prognostic factors and potential therapeutic agents, it may be possible to improve the standard of care for RB patients.

Focal adhesion kinase (FAK) is a non-receptor tyrosine kinase. It is localized to focal adhesions or contact points between cells and their extracellular matrix and

is highly activated by integrin-mediated stimulation of cells¹⁷⁻¹⁹. FAK phosphorylation at tyrosine residue 397 results in activation and modulation of signals critical for survival of anchorage-dependent cells and cell migration²⁰. In tumors, FAK plays a pivotal role in cell viability, survival, proliferation, migration and invasion²¹⁻²⁵. FAK overexpression is observed in a wide variety of tumors and it is frequently used as a marker of severity, invasion and metastasis²⁶⁻³². In fact, it has been demonstrated that inhibition of FAK impairs growth in cancers such as cutaneous melanoma³³, breast³⁴, lung¹⁸ and ovary carcinomas³⁵ and neural tumors such as neuroblastoma¹⁹.

To date, there have been no previous reports of FAK expression in retinoblastoma. The purpose of this study is to evaluate the expression of FAK in retinoblastoma and to correlate this expression with clinical and histopathological prognostic factors.

MATERIAL AND METHODS

Twenty formalin-fixed paraffin-embedded primary retinoblastomas were collected from the archives of the Henry C. Witelson Ocular Pathology Laboratory and Registry, McGill University, Montreal, Canada. Age and gender were obtained from histopathological reports.

Nine males aged 7, 12, 21, 23, 24, 24, 36, 38, 39 months and eleven females aged 6, 6, 14, 16, 20, 24, 36, 36, 48, 60, 60 months were used in this study. Two sections were obtained from each specimen.

Sections were haematoxylin and eosin stained for histopathological assessment. Two independent pathologists reviewed the slides by light microscopy. The following parameters were reported: the pattern of tumor growth (endophytic, exophytic, mixed, diffuse, necrotic or spontaneous regression)³⁶, cell differentiation status (well differentiated: Flexner-Wintersteiner rosettes or fleurettes in more than 80% of the area; moderately differentiated: Flexner-Wintersteiner rosettes or fleurettes in less than 80% of the area; poorly differentiated: absence of these structures)³⁷, optic nerve and choroidal invasion (according to the Khelifaoui protocol)³⁸, anterior chamber invasion and presence of vitreous seeding.

Immunohistochemistry was completed using the Ventana BenchMark LT (Ventana Medical System Inc., Arizona, USA) fully automated machine. FAK staining was performed according to the protocols and instructions provided by Ventana Medical Systems, Inc. The processing of bar code-labeled slides included baking of the slides, solvent-free deparaffinization, and CC1 (Tris-EDTA buffer,

pH 8.0) antigen retrieval. One slide from each specimen was incubated with mouse monoclonal anti-human FAK (clone 77; 1:1,000; BD Biosciences, Lexington, KY) and the other slide was incubated with rabbit monoclonal anti-human FAK [pY397] (1:1,000; BioSource, Camarillo, CA) for 30 minutes at 37°C, followed by application of a biotinylated secondary antibody (8 minutes at 37°C) and an avidin-alkaline phosphatase enzyme conjugate complex (8 minutes at 37°C). Finally, the antibody was detected by Fast Red chromogenic substrate and counterstained with hematoxylin. As positive controls, sections of skin melanoma were used. For negative controls, the primary antibody was omitted.

The expression of FAK and FAK [pY397] were classified according to the intensity (0: no staining; 1: weak staining; 2: moderate staining; 3: strong staining) and percentage of positive tumor cells (0: no staining; 1: less than or equal to 25%; 2: 26% through 50%; 3: more than or equal to 51%). The scores were summed and a final score was given to each case for each anti-body. The final score was classified as weak (<3), moderate (4-5) or strong (6).

The final immunohistochemical score was correlated to age and histopathological factors indicating poor prognosis such as optic nerve, anterior chamber and choroidal invasion, tumor differentiation and vitreous

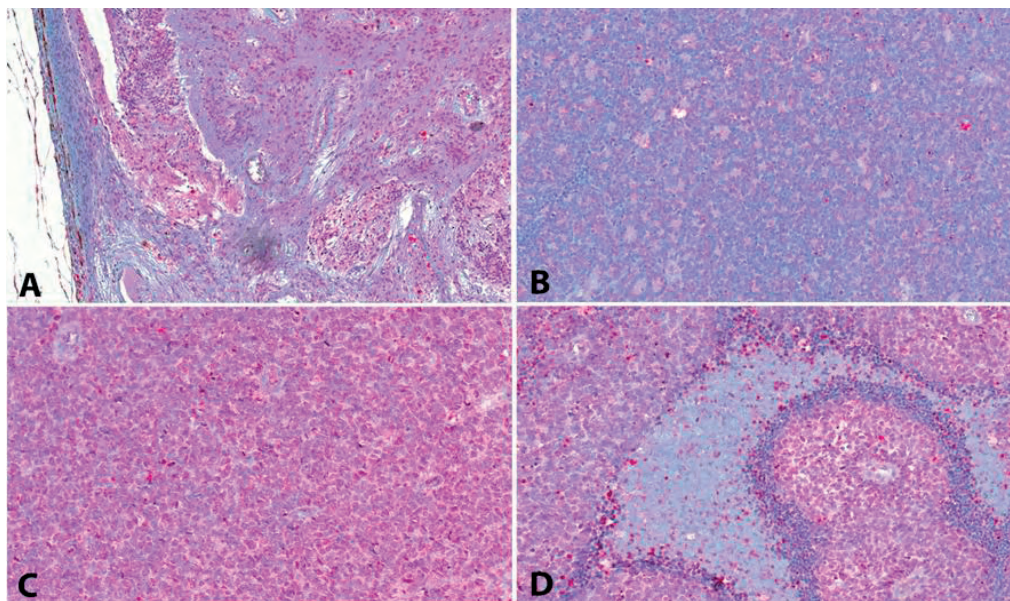


Fig. 1 | Digital photomicrograph of retinoblastoma specimens immunostained for FAK [pY397]. **A)** Staining intensity 3 in a poorly differentiated RB with choroidal invasion (H&E; original magnification $\times 4.1$ using AIS equivalent to 41 x magnification in microscopy). **B)** Staining intensity 2 in a moderately differentiated RB (H&E; original magnification $\times 20$ using AIS equivalent to 200 x magnification in microscopy). **C)** Staining intensity 3 in a RB (H&E; original magnification $\times 20$ using AIS equivalent to 200 x magnification in microscopy). **D)** Staining intensity 3 in a RB with necrosis (H&E; original magnification $\times 20$ using AIS equivalent to 200 x magnification in microscopy).

*AIS: Aperio's Imagescope Software

Table 1 |

Case	Differentiation	Growth Pattern	AC invasion y/n	Choroid invasion y/n	ON invasion y/n	Vitreous seeding y/n
1	PD	Endo	N	n	y	y
2	PD	Endo	N	n	n	n
3	PD	Mixed	Y	y	y	y
4	PD	Mixed	N	y	n/a	y
5	MD	Mixed	N	y	n	y
6	PD	Mixed	Y	y	y	y
7	WD	Mixed	N	n	n	n
8	PD	Mixed	Y	y	n	y
9	MD	Exo	N	y	n	n
10	PD	Mixed	N	y	y	y
11	MD	Mixed	N	y	n	y
12	PD	Mixed	Y	y	y	y
13	PD	Mixed	N	y	n	y
14	PD	Mixed	N	n	n	y
15	MD	Endo	N	n	n	y
16	MD	Mixed	N	y	n	y
17	WD	Mixed	N	y	n	n
18	MD	Mixed	N	n	n	y
19	WD	Diffuse	N	y	n	n
20	PD	Mixed	N	n	n	y

Histopathological classification and prognostic factors of all cases. AC = anterior chamber; endo = endophytic; exo = exophytic; MD = moderately differentiated; n = no; ON = optic nerve; n/a = not applicable; PD = poorly differentiated; WD = well differentiated; y = yes.

seeding. For statistical analysis of the results, the Pearson chi-squared test was used to assess whether FAK and FAK [pY397] expression differed with age and varying extents of tumor invasion and degrees of differentiation. ($p < 0.05$ was considered significant).

RESULTS

The mean age of the patients was 27.5 ± 16.3 months. There were 9 right eyes and 11 left eyes. In 3 cases (15%), the patients had bilateral retinoblastoma and in the remaining 17 (85%) patients the tumor was unilateral. In one case it was not possible to evaluate optic nerve invasion because that tissue was lacking in the specimen. In table 1 we present the histopathological classification (differentiation and growth pattern) and prognostic factors (anterior chamber, choroidal and optic nerve invasion and vitreous seeding) of the specimens.

According to the histopathological results, 11 (55%) tumors were poorly differentiated, 6 (30%)

were moderately differentiated, and 3 (15%) were well differentiated. The most frequent growth pattern was the mixed type, seen in 15 (75%) patients. This was followed by an endophytic pattern in 3 (15%) patients, the exophytic pattern in 1 (5%) patient and the diffuse pattern in 1 (5%) patient. Anterior chamber invasion was observed in 16 (80%) patients, choroidal invasion in 7 (35%) patients, optic nerve invasion in 14 (70%) patients, and vitreous seeding in 5 (25%) patients.

All cases displayed a diffuse heterogeneous pattern of immunostaining. In the anti-FAK [pY397] stained specimens, all cases revealed expression of this molecule in the nucleus and in the cytoplasm, except for two that were positive only in the cytoplasm. In this group, three (15%) cases presented weak expression, 12 (60%) presented moderate expression and 5 (25%) presented strong expression (Figure 1.). There was no significant correlation between FAK [pY397] expression and age or histopathological prognostic factors. In the anti-FAK stained specimens, all cases expressed this molecule in the nucleus and the cytoplasm. One case (5%) presented

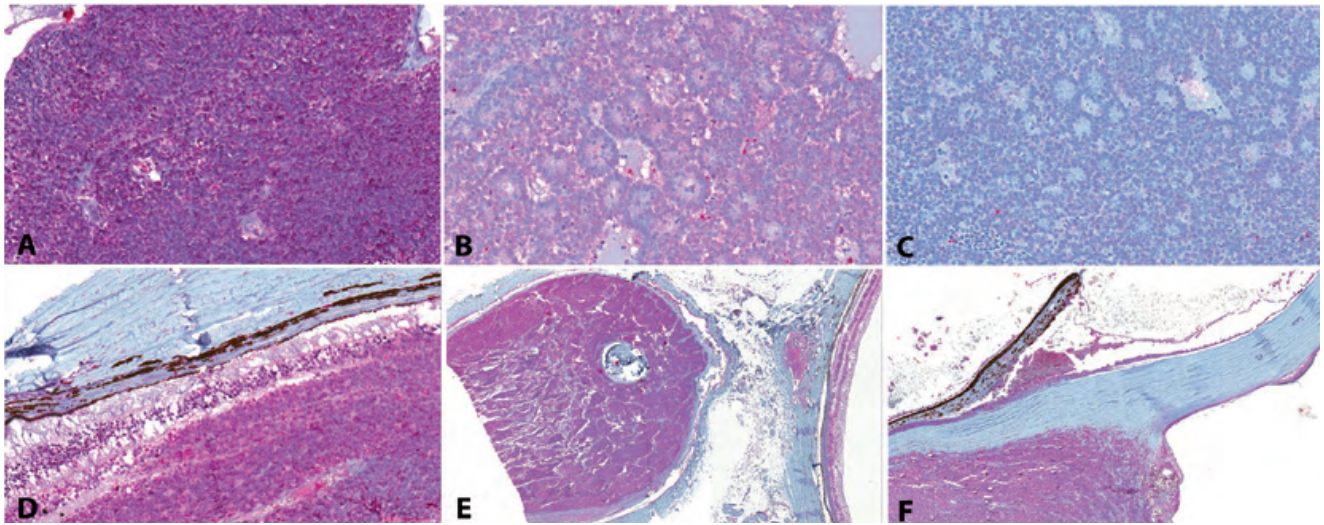


Fig. 2 | Digital photomicrograph of retinoblastoma specimens stained for FAK. **A)** Staining intensity 3 in a poorly differentiated RB (H&E; original magnification $\times 20$ using AIS equivalent to 200 x magnification in microscopy). **B)** Staining intensity 2 in a well differentiated RB (H&E; original magnification $\times 20$ using AIS equivalent to 200 x magnification in microscopy). **C)** Staining intensity 1 in a well differentiated RB (H&E; original magnification $\times 20$ using AIS equivalent to 200 x magnification in microscopy). **D)** Tumor adjacent to the retina, which presents distorted structures and high intensity immunostaining (H&E; original magnification $\times 20$ using Aperio's Imagescope Software equivalent to 200 x magnification in microscopy). **E)** Optic nerve invasion by a highly stained tumor (H&E; original magnification $\times 1.9$ using Aperio's Imagescope Software equivalent to 19 x magnification in microscopy). **F)** Anterior chamber and extraocular invasion by a highly stained tumor (H&E; original magnification $\times 4.2$ using Aperio's Imagescope Software equivalent to 42 x magnification in microscopy).
*AIS: Aperio's Imagescope Software

weak FAK expression, 15 (75%) presented moderate expression and 4 (20%) presented strong expression (Figure 2.). FAK expression did not correlate with either age or histopathological prognostic factors. Some non-involved intraocular tissues, like retina, choroid and ciliary body also showed weak immunostaining with both anti-FAK and anti-FAK [pY397].

DISCUSSION

In the United States, 300–350 new cases of retinoblastoma are diagnosed annually and 5000 cases are diagnosed worldwide^{39,40}. In developed countries, over 95% of children will survive this malignancy and 90% will retain vision in at least one eye^{39,41}. In the developing world, the mortality rate reaches about 70%,⁴ mainly due to delayed diagnosis. The major threat for retinoblastoma is its invasive nature and chemoresistance. An understanding of the mechanisms responsible for the aggressive retinoblastoma phenotype is essential, as these factors must be considered in the development of new drugs and more selective chemotherapeutic regimens. In particular, protein tyrosine kinases have emerged as a potential therapeutic target because

of the important role they play in cellular mechanisms such as differentiation, proliferation, regulatory processes and signal transduction⁴².

FAK is a cytoplasmic non-receptor protein tyrosine kinase with several functions. Structurally, FAK plays an important role in cell-cell and cell-extracellular matrix adhesion. Once phosphorylated, the activated FAK transmits ligand-dependent cell signals downstream of integrins, growth factors and G protein-coupled receptors⁴³. During its activation, it is sequentially phosphorylated on its major autophosphorylation site, Tyr 397, and other sites, namely Tyr 576, thus rendering this molecule a fully active kinase⁴⁴. In addition to this well-described role as a cytoplasmic kinase, FAK has demonstrated activity in the nucleus. Pathological stimuli such as cell de-adhesion from the substrate⁴⁵, oxidative stress⁴⁶ and FAK inhibition^{47,48} may promote FAK nuclear migration. Furthermore, FAK enhances cell survival and proliferation through its nuclear kinase independent roles, by promoting p53 degradation via ubiquitination⁴⁵. It also acts as a co-transcriptional regulator capable of altering gene transcription⁴⁶. FAK is implicated in tumor invasion by regulating the activity of proteolytic enzymes like urokinase^{33,49}. In studies of malignant melanoma, FAK expression was correlated to the migration

potential of cells⁵⁰. In studies of retinal pathologies, FAK overexpression enhanced angiogenesis in the retina⁵¹. Thus, FAK has been implicated in numerous functional aspects of cancer including epithelial mesenchymal transition, maintenance of cancer stem cells, promotion of tumor cell survival, angiogenesis, invasion and metastasis^{20,27,52-54}.

Because FAK is involved in multiple mechanisms related to tumor proliferation, invasion and metastasis, it is worthwhile to explore the role of FAK in RB. Therefore, we evaluated the expression of FAK in a series of 20 cases of retinoblastoma and all cases expressed FAK at detectable levels. Strong and moderate expression of FAK [pY397] and FAK was seen in 85% and in 95% of the cases, respectively. The high rates of positivity obtained in this study confirm that FAK is significantly overexpressed in retinoblastoma, implying that both phosphorylated and nonphosphorylated FAK may play an important role in its pathogenesis. FAK overexpression has been demonstrated in a variety of malignancies including cutaneous melanoma,³³ breast,³⁴ lung¹⁸, ovary³⁵ and colon carcinomas⁵⁵, Ewing sarcoma⁵⁶, gastrointestinal stromal tumor⁵⁷ and neural tumors such as neuroblastoma and glioblastoma^{19,58}. Some cancers which have demonstrated a correlation between FAK expression and poor prognosis include breast²⁹, colorectal³¹, lung cancer⁵⁹, oesophageal squamous cell carcinoma²⁸, hepatocellular³² and oral squamous cell carcinoma³⁰. In uveal melanoma cell lines the expression of phosphorylated FAK correlated with the acquisition of an invasive phenotype and vasculogenic mimicry³³. Our study found no correlation between FAK immunostaining and histopathological prognostic factors. This may be partly related to the limited sample size. Our findings are in line with studies of colon adenocarcinoma⁶⁰ and pancreatic cancer⁶¹, where FAK expression did not correlate with histopathological markers or prognosis. It is important to note that in one study of invasive cervical cancer, weak expression of FAK was found to be a strong independent predictor of poor patient outcomes⁶². This suggests a more complex role of this kinase in carcinogenesis.

It is plausible that FAK is involved in multiple stages of tumor progression, given the overexpression observed in both differentiated and non-differentiated RB tumors. In early malignant transformation, FAK may be implicated in the regulation of apoptosis and tumor proliferation^{21, 63-65}. In the later stages of RB development, FAK may play a role in tumor progression, invasion and metastasis^{20, 26, 31, 33, 50}.

Due to the multiple roles of FAK in tumor development and metastatic cascade, it is currently being investigated as a new target for therapeutic intervention^{58, 66, 67}. The presence of FAK in non-tumoral tissues in the eye and its

roles in both normal and diseased cells may be a concerning factor regarding therapy²⁵. In our sample, both FAK and FAK [pY397] were highly expressed, precluding discrimination between aggressive and non-aggressive status. On the contrary, in a study by Hess et al., phosphorylated FAK on Tyr397 and Tyr576, was found to be expressed only in the most aggressive cutaneous and uveal melanoma cells, thus rendering FAK [pY397] as a potential therapeutic target³³. A better understanding of the roles of FAK and FAK [pY397] in retinoblastoma may provide new insights into possible therapeutic intervention strategies.

A limitation of our study was the absence of clinical data regarding the enucleated specimens. As a result we cannot be sure whether any specimen was a primary enucleation, or if chemotherapy or radiotherapy was administered before surgery. Therefore, from our series it is not possible to determine whether conservative treatments had any influence on the expression of FAK and FAK [pY397].

To the best of our knowledge, this is the first study addressing the expression of FAK in retinoblastoma. The overexpression of this kinase suggests that FAK may play a key role in the progression of RB. Further studies regarding the roles of FAK in RB and the potential effect of its inhibition are warranted.

REFERENCES

1. Howarth C, Meyer D, Hustu HO, Johnson WW, Shanks E, Pratt C. Stage-related combined modality treatment of retinoblastoma. Results of a prospective study. *Cancer*. 1980 Mar 1;45(5):851-8.
2. Hurwitz RL, Shields, C.L.SJ, Chevez-Barrios, P., Chintagumpala, M.M., editor. *Principles & Practice of Pediatric Oncology*. 5th ed. Philadelphia: Lippincott Williams & Wilkins; 2005.
3. Abramson DH. Retinoblastoma in the 20th Century: Past Success and Future Challenges The Weisenfeld Lecture. *Investigative Ophthalmology & Visual Science*. 2005 August 1, 2005;46(8):2684-91.
4. Dimaras H, Kimani K, Dimba EA, Gronsdahl P, White A, Chan HS, et al. Retinoblastoma. *Lancet*. 2012 Apr 14;379(9824):1436-46.
5. Kivela T. The epidemiological challenge of the most frequent eye cancer: retinoblastoma, an issue of birth and death. *Br J Ophthalmol*. 2009 Sep;93(9):1129-31.
6. MacCarthy A, Draper GJ, Steliarova-Foucher E, Kingston JE. Retinoblastoma incidence and survival in European children (1978-1997). Report from the Automated

- Childhood Cancer Information System project. *Eur J Cancer*. 2006 Sep;42(13):2092-102.
7. Nyamori JM, Kimani K, Njuguna MW, Dimaras H. The incidence and distribution of retinoblastoma in Kenya. *Br J Ophthalmol*. 2012 Jan;96(1):141-3.
 8. Leal-Leal C, Flores-Rojo M, Medina-Sanson A, Cerecedo-Diaz F, Sanchez-Felix S, Gonzalez-Ramella O, et al. A multicentre report from the Mexican Retinoblastoma Group. *Br J Ophthalmol*. 2004 Aug;88(8):1074-7.
 9. Rodrigues KE, Latorre Mdo R, de Camargo B. [Delayed diagnosis in retinoblastoma]. *J Pediatr (Rio J)*. 2004 Nov-Dec;80(6):511-6.
 10. Society CR. National Retinoblastoma Strategy Canadian Guidelines for Care: Strategie therapeutique du retinoblastome guide clinique canadien. *Can J Ophthalmol*. 2009;44 Suppl 2:S1-88.
 11. Abramson DH, Scheffler AC. Update on retinoblastoma. *Retina*. 2004 Dec;24(6):828-48.
 12. Deegan WF. Emerging strategies for the treatment of retinoblastoma. *Curr Opin Ophthalmol*. 2003 Oct;14(5):291-5.
 13. Demirci H, Eagle RC, Jr., Shields CL, Shields JA. Histopathologic findings in eyes with retinoblastoma treated only with chemoreduction. *Arch Ophthalmol*. 2003 Aug;121(8):1125-31.
 14. Filho JP, Correa ZM, Odashiro AN, Coutinho AB, Martins MC, Erwenne CM, et al. Histopathological features and P-glycoprotein expression in retinoblastoma. *Invest Ophthalmol Vis Sci*. 2005 Oct;46(10):3478-83.
 15. Scott IU, Murray TG, Toledano S, O'Brien JM. New retinoblastoma tumors in children undergoing systemic chemotherapy. *Arch Ophthalmol*. 1998 Dec;116(12):1685-6.
 16. Lee TC, Hayashi NI, Dunkel IJ, Beaverson K, Novetsky D, Abramson DH. New retinoblastoma tumor formation in children initially treated with systemic carboplatin. *Ophthalmology*. 2003 Oct;110(10):1989-94; discussion 94-5.
 17. van Nimwegen MJ, Verkoeijen S, van Buren L, Burg D, van de Water B. Requirement for focal adhesion kinase in the early phase of mammary adenocarcinoma lung metastasis formation. *Cancer Res*. 2005 Jun 1;65(11):4698-706.
 18. Meng XN, Jin Y, Yu Y, Bai J, Liu GY, Zhu J, et al. Characterisation of fibronectin-mediated FAK signalling pathways in lung cancer cell migration and invasion. *Br J Cancer*. 2009 Jul 21;101(2):327-34.
 19. Beierle EA, Massoll NA, Hartwich J, Kurenova EV, Golubovskaya VM, Cance WG, et al. Focal adhesion kinase expression in human neuroblastoma: immunohistochemical and real-time PCR analyses. *Clin Cancer Res*. 2008 Jun 1;14(11):3299-305.
 20. Schlaepfer DD, Mitra SK. Multiple connections link FAK to cell motility and invasion. *Curr Opin Genet Dev*. 2004 Feb;14(1):92-101.
 21. Frisch SM, Vuori K, Ruoslahti E, Chan-Hui PY. Control of adhesion-dependent cell survival by focal adhesion kinase. *J Cell Biol*. 1996 Aug;134(3):793-9.
 22. Sonoda Y, Watanabe S, Matsumoto Y, Aizu-Yokota E, Kasahara T. FAK is the upstream signal protein of the phosphatidylinositol 3-kinase-Akt survival pathway in hydrogen peroxide-induced apoptosis of a human glioblastoma cell line. *J Biol Chem*. 1999 Apr 9;274(15):10566-70.
 23. Sonoda Y, Matsumoto Y, Funakoshi M, Yamamoto D, Hanks SK, Kasahara T. Anti-apoptotic role of focal adhesion kinase (FAK). Induction of inhibitor-of-apoptosis proteins and apoptosis suppression by the overexpression of FAK in a human leukemic cell line, HL-60. *J Biol Chem*. 2000 May 26;275(21):16309-15.
 24. Sood AK, Coffin JE, Schneider GB, Fletcher MS, DeYoung BR, Gruman LM, et al. Biological significance of focal adhesion kinase in ovarian cancer: role in migration and invasion. *Am J Pathol*. 2004 Oct;165(4):1087-95.
 25. Schwock J, Dhani N, Hedley DW. Targeting focal adhesion kinase signaling in tumor growth and metastasis. *Expert Opinion on Therapeutic Targets*. 2009 2010/01/01;14(1):77-94.
 26. Cance WG, Harris JE, Iacocca MV, Roche E, Yang X, Chang J, et al. Immunohistochemical Analyses of Focal Adhesion Kinase Expression in Benign and Malignant Human Breast and Colon Tissues: Correlation with Preinvasive and Invasive Phenotypes. *Clinical Cancer Research*. 2000 June 1, 2000;6(6):2417-23.
 27. Owens LV, Xu L, Craven RJ, Dent GA, Weiner TM, Kornberg L, et al. Overexpression of the focal adhesion kinase (p125FAK) in invasive human tumors. *Cancer Res*. 1995 Jul 1;55(13):2752-5.
 28. Miyazaki T, Kato H, Nakajima M, Sohda M, Fukai Y, Masuda N, et al. FAK overexpression is correlated with tumour invasiveness and lymph node metastasis in oesophageal squamous cell carcinoma. *Br J Cancer*. 2003 Jul 7;89(1):140-5.
 29. Lark AL, Livasy CA, Dressler L, Moore DT, Millikan RC, Geradts J, et al. High focal adhesion kinase expression in invasive breast carcinomas is associated with an aggressive phenotype. *Mod Pathol*. 2005 Oct;18(10):1289-94.
 30. de Vicente JC, Rosado P, Lequerica-Fernandez P,

- Allonca E, Villallain L, Hernandez-Vallejo G. Focal adhesion kinase overexpression: correlation with lymph node metastasis and shorter survival in oral squamous cell carcinoma. *Head Neck*. 2013 Jun;35(6):826-30.
31. Lark AL, Livasy CA, Calvo B, Caskey L, Moore DT, Yang X, et al. Overexpression of Focal Adhesion Kinase in Primary Colorectal Carcinomas and Colorectal Liver Metastases: Immunohistochemistry and Real-Time PCR Analyses. *Clinical Cancer Research*. 2003 January 1, 2003;9(1):215-22.
32. Itoh S, Maeda T, Shimada M, Aishima S, Shirabe K, Tanaka S, et al. Role of expression of focal adhesion kinase in progression of hepatocellular carcinoma. *Clin Cancer Res*. 2004 Apr 15;10(8):2812-7.
33. Hess AR, Postovit LM, Margaryan NV, Seftor EA, Schneider GB, Seftor RE, et al. Focal adhesion kinase promotes the aggressive melanoma phenotype. *Cancer Res*. 2005 Nov 1;65(21):9851-60.
34. Sheen-Chen SM, Huang CY, Chan YC, Tsai CH, Chi SY, Wu SC, et al. An evaluation of focal adhesion kinase in breast cancer by tissue microarrays. *Anticancer Res*. 2013 Mar;33(3):1169-73.
35. Judson PL, He X, Cance WG, Van Le L. Overexpression of focal adhesion kinase, a protein tyrosine kinase, in ovarian carcinoma. *Cancer*. 1999 Oct 15;86(8):1551-6.
36. Arean C, Orellana ME, Abourbih D, Abreu C, Pifano I, Burnier MN, Jr. Expression of vascular endothelial growth factor in retinoblastoma. *Arch Ophthalmol*. 2010 Feb;128(2):223-9.
37. Schouten-van Meeteren AY, van der Valk P, van der Linden HC, Moll AC, Imhof SM, Huismans DR, et al. Histopathologic features of retinoblastoma and its relation with in vitro drug resistance measured by means of the MTT assay. *Cancer*. 2001 Dec 1;92(11):2933-40.
38. Khelifaoui F, Validire P, Auperin A, Quintana E, Michon J, Pacquement H, et al. Histopathologic risk factors in retinoblastoma: a retrospective study of 172 patients treated in a single institution. *Cancer*. 1996 Mar 15;77(6):1206-13.
39. Shields CL, Shields JA. Diagnosis and management of retinoblastoma. *Cancer Control*. 2004 Sep-Oct;11(5):317-27.
40. Ray A, Gombos DS, Vats TS. Retinoblastoma: an overview. *Indian J Pediatr*. 2012 Jul;79(7):916-21.
41. Abramson DH. Retinoblastoma in the 20th century: past success and future challenges the Weisenfeld lecture. *Invest Ophthalmol Vis Sci*. 2005 Aug;46(8):2683-91.
42. Barry RJ, de Moura LR, Marshall JC, Fernandes BF, Orellana ME, Anteckka E, et al. Expression of C-kit in retinoblastoma: a potential therapeutic target. *Br J Ophthalmol*. 2007 Nov;91(11):1532-6.
43. Hanks SK, Ryzhova L, Shin NY, Brabek J. Focal adhesion kinase signaling activities and their implications in the control of cell survival and motility. *Front Biosci*. 2003 May 1;8:d982-96.
44. Owen JD, Ruest PJ, Fry DW, Hanks SK. Induced focal adhesion kinase (FAK) expression in FAK-null cells enhances cell spreading and migration requiring both auto- and activation loop phosphorylation sites and inhibits adhesion-dependent tyrosine phosphorylation of Pyk2. *Mol Cell Biol*. 1999 Jul;19(7):4806-18.
45. Lim ST, Chen XL, Lim Y, Hanson DA, Vo TT, Howerston K, et al. Nuclear FAK promotes cell proliferation and survival through FERM-enhanced p53 degradation. *Mol Cell*. 2008 Jan 18;29(1):9-22.
46. Luo SW, Zhang C, Zhang B, Kim CH, Qiu YZ, Du QS, et al. Regulation of heterochromatin remodelling and myogenin expression during muscle differentiation by FAK interaction with MBD2. *Embo J*. 2009 Sep 2;28(17):2568-82.
47. Lim ST, Chen XL, Tomar A, Miller NL, Yoo J, Schlaepfer DD. Knock-in mutation reveals an essential role for focal adhesion kinase activity in blood vessel morphogenesis and cell motility-polarity but not cell proliferation. *J Biol Chem*. 2010 Jul 9;285(28):21526-36.
48. Lim ST, Miller NL, Chen XL, Tancioni I, Walsh CT, Lawson C, et al. Nuclear-localized focal adhesion kinase regulates inflammatory VCAM-1 expression. *J Cell Biol*. 2012 Jun 25;197(7):907-19.
49. Aguirre Ghiso JA. Inhibition of FAK signaling activated by urokinase receptor induces dormancy in human carcinoma cells in vivo. *Oncogene*. 2002 Apr 11;21(16):2513-24.
50. Akasaka T, van Leeuwen RL, Yoshinaga IG, Mihm MC, Jr., Byers HR. Focal adhesion kinase (p125FAK) expression correlates with motility of human melanoma cell lines. *J Invest Dermatol*. 1995 Jul;105(1):104-8.
51. Kornberg LJ, Shaw LC, Spoerri PE, Caballero S, Grant MB. Focal adhesion kinase overexpression induces enhanced pathological retinal angiogenesis. *Invest Ophthalmol Vis Sci*. 2004 Dec;45(12):4463-9.
52. Lark AL, Livasy CA, Calvo B, Caskey L, Moore DT, Yang X, et al. Overexpression of focal adhesion kinase in primary colorectal carcinomas and colorectal liver metastases: immunohistochemistry and real-time PCR analyses. *Clin Cancer Res*. 2003 Jan;9(1):215-22.
53. Siesser PM, Hanks SK. The signaling and biological implications of FAK overexpression in cancer. *Clin Cancer Res*. 2006 Jun 1;12(11 Pt 1):3233-7.
54. Zhao X, Guan JL. Focal adhesion kinase and its

- signaling pathways in cell migration and angiogenesis. *Adv Drug Deliv Rev.* 2011 Jul 18;63(8):610-5.
55. Heffler M, Golubovskaya VM, Dunn KM, Cance W. Focal adhesion kinase autophosphorylation inhibition decreases colon cancer cell growth and enhances the efficacy of chemotherapy. *Cancer Biol Ther.* 2013 Jun 3;14(8).
56. Crompton BD, Carlton AL, Thorner AR, Christie AL, Du J, Calicchio ML, et al. High-throughput tyrosine kinase activity profiling identifies FAK as a candidate therapeutic target in Ewing sarcoma. *Cancer Res.* 2013 May 1;73(9):2873-83.
57. Takahashi T, Serada S, Ako M, Fujimoto M, Miyazaki Y, Nakatsuka R, et al. New findings of kinase switching in gastrointestinal stromal tumor under imatinib using phosphoproteomic analysis. *Int J Cancer.* 2013 May 28.
58. Golubovskaya VM, Huang G, Ho B, Yemma M, Morrison CD, Lee J, et al. Pharmacologic blockade of FAK autophosphorylation decreases human glioblastoma tumor growth and synergizes with temozolomide. *Mol Cancer Ther.* 2013 Feb;12(2):162-72.
59. Ji HF, Pang D, Fu SB, Jin Y, Yao L, Qi JP, et al. Overexpression of focal adhesion kinase correlates with increased lymph node metastasis and poor prognosis in non-small-cell lung cancer. *J Cancer Res Clin Oncol.* 2013 Mar;139(3):429-35.
60. Theocharis SE, Kouraklis GP, Kakisis JD, Kanelli HG, Apostolakou FE, Karatzas GM, et al. Focal adhesion kinase expression is not a prognostic predictor in colon adenocarcinoma patients. *Eur J Surg Oncol.* 2003 Sep;29(7):571-4.
61. Furuyama K, Doi R, Mori T, Toyoda E, Ito D, Kami K, et al. Clinical significance of focal adhesion kinase in resectable pancreatic cancer. *World J Surg.* 2006 Feb;30(2):219-26.
62. Gabriel B, zur Hausen A, Stickeler E, Dietz C, Gitsch G, Fischer DC, et al. Weak expression of focal adhesion kinase (pp125FAK) in patients with cervical cancer is associated with poor disease outcome. *Clin Cancer Res.* 2006 Apr 15;12(8):2476-83.
63. Zhao JH, Reiske H, Guan JL. Regulation of the cell cycle by focal adhesion kinase. *J Cell Biol.* 1998 Dec 28;143(7):1997-2008.
64. Wang D, Grammer JR, Cobbs CS, Stewart JE, Jr., Liu Z, Rhoden R, et al. p125 focal adhesion kinase promotes malignant astrocytoma cell proliferation in vivo. *J Cell Sci.* 2000 Dec;113 Pt 23:4221-30.
65. Beviglia L, Golubovskaya V, Xu L, Yang X, Craven RJ, Cance WG. Focal adhesion kinase N-terminus in breast carcinoma cells induces rounding, detachment and apoptosis. *Biochem J.* 2003 Jul 1;373(Pt 1):201-10.
66. Infante JR, Camidge DR, Mileskin LR, Chen EX, Hicks RJ, Rischin D, et al. Safety, pharmacokinetic, and pharmacodynamic phase I dose-escalation trial of PF-00562271, an inhibitor of focal adhesion kinase, in advanced solid tumors. *J Clin Oncol.* 2012 May 1;30(13):1527-33.
67. Kim H, Kim ND, Lee J, Han G, Sim T. Identification of Methyl Violet 2B as a Novel Blocker of Focal Adhesion Kinase Signaling Pathway in Cancer Cells. *Biochem Biophys Res Commun.* 2013 Jun 28.

Trabalho desenvolvido no Henry C. Witelson Ocular Pathology Laboratory, Department of Pathology, McGill University Health Center, Montreal, Quebec, Canada

Os autores não têm conflitos de interesse a declarar.

No conflicting relationship exists for any author..

CONTACTO

Hospital de Santo António dos Capuchos,
Serviço de Oftalmologia, Alameda de Santo António dos
Capuchos, 1169-050 Lisboa.

E-mail: arnaldomiguelsantos@gmail.com