

# Unusual bilateral retinitis secondary to *Rickettsia conorii* infection

André Marques<sup>1</sup>, Pedro Simões<sup>1</sup>, Marta Guedes<sup>1,2</sup>

<sup>1</sup>Egas Moniz Hospital (Lisbon, Portugal)

<sup>2</sup>Head of the Uveitis Clinic, Egas Moniz Hospital (Lisbon, Portugal)

## RESUMO

Um quadro de retinite pode ter diversas causas, nomeadamente infecciosas ou auto-ímmunes, sendo o diagnóstico correcto fundamental para o melhor tratamento e prevenção de perda visual irreversível. Comunicamos o caso de um homem saudável que se apresentou com um quadro de retinite bilateral multifocal com envolvimento vascular perilesional após um período febril e exantema cutâneo. Após algumas dificuldades iniciais, o diagnóstico de infecção por *Rickettsia conorii* foi estabelecido e administrado o devido tratamento. Este é, para os autores, um dos poucos casos publicados de uveíte posterior secundária a rickettsiose no qual se verificaram complicações oculares raras, incluindo edema macular bilateral com descolamento neurosensorial da fóvea e desenvolvimento de estrela macular, e para as quais se recorreu também a corticoterapia sistémica devido ao risco elevado de perda visual.

## Palavras-chave

*Rickettsia, conorii*, uveíte, retinite, rash

## ABSTRACT

Retinitis can be caused by a number of reasons, namely infectious or autoimmune, and the correct diagnosis is fundamental in order to provide the best treatment and to prevent irreversible visual loss. We report a case of a young healthy man who presented with bilateral multifocal retinitis with perilesional vascular involvement following a febrile period and a cutaneous rash. Despite some initial pitfalls, a diagnosis of *Rickettsia conorii* was finally made and appropriate treatment was provided. To our knowledge, this is one of the few reported cases of posterior uveitis due to rickettsiosis in which rare ocular complications are seen, including bilateral macular edema with foveal detachment and macular star development, and in which treatment with systemic corticosteroids was provided due to sight-threatening lesions.

## Keywords

*Rickettsia, conorii*, uveitis, retinitis, rash

## INTRODUCTION

Rickettsiosis are zoonosis caused by intracellular gram-negative bacteria, transmitted to humans by infected arthropods. Rickettsial agents can fall into three major

categories, namely the typhus group, the scrub group and the spotted fever group. The last one includes *Rickettsia conorii* (*R. conorii*), responsible for causing boutnonneuse fever, also known as Mediterranean spotted fever (MSF), an acute systemic disease that manifests with high fever,

headaches, general malaise and a typical cutaneous maculopapular exanthema which tends to involve the palms and soles<sup>1-3</sup>. In Portugal, as well as in countries along the Mediterranean basin, MSF is considered an endemic disease and *Rhipicephalus sanguineus* (the “dog tick”) is the main vector and reservoir of *R. conorii*<sup>4</sup>.

Several ocular complications can follow *R. conorii* infection but the posterior segment manifestations may be the most important and severe ones. However, there are relatively few case-reports and reviews available regarding posterior uveitis presentations in a rickettsiosis context<sup>5-8</sup>. Also, there are even fewer reports regarding the role of systemic corticosteroids when treating these patients and the possibility of central nervous system (CNS) involvement.

The following case depicts an unusual presentation of *R. conorii*-related uveitis and the steps taken towards the correct diagnosis. We also discuss some rare ocular complications and the suitable treatment approach.

## CASE REPORT

A 35-years old male patient presented to our emergency room with a 4-day history of sudden and progressive bilateral visual acuity (VA) reduction.

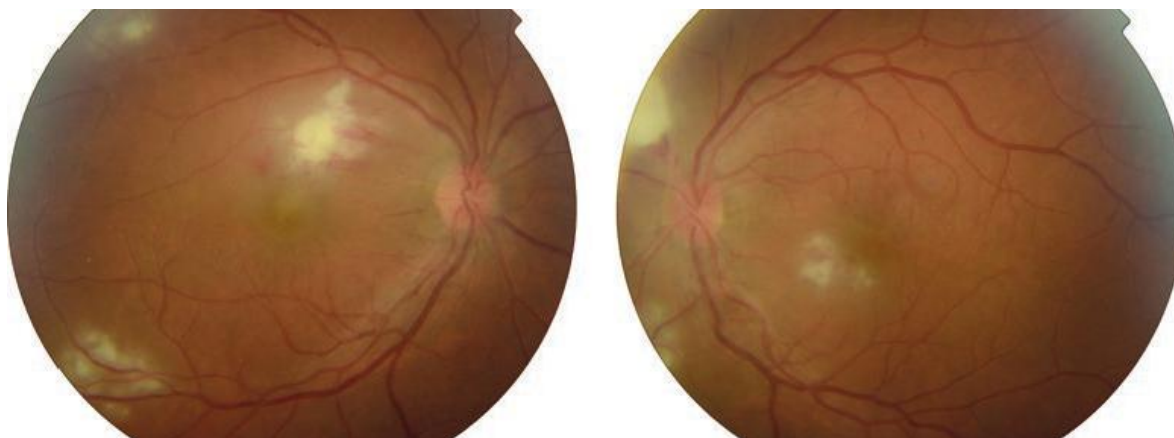
appearance, with circumoral pallor and sparing only the palms and soles. Since there were known cases of scarlet fever in his children’s school, and considering the recent acute tonsillitis, his rash was interpreted as scarlet fever by his doctor, who changed his antibiotic to intravenous cefazoline.

Although there was some clinical improvement, about two weeks later he noticed a marked visual loss, denying other relevant ocular signs or symptoms apart from a mildly red eye, such as pain, floaters, photopsia or metamorphopsia.

On clinical examination, his best corrected visual acuity (BCVA) was indeed very low, 20/200 in his right eye (OD) and 20/63 in his left eye (OS). Pupils’ light and near responses were normal and he reported no red-colour desaturation.

Slit-lamp examination revealed a bilateral 2+ conjunctival injection and 3+ anterior chamber cellular reaction, with no visible keratic precipitates and with normal intraocular pressure. On dilated fundus observation, there were multiple white to yellowish retinitis lesions visible with relatively distinct borders, mainly in the macular area and near the main vascular arcades, with associated perilesional Hemorrhage. There was no noticeable vitritis and the optic discs looked normal in both eyes (Figure 1).

Confronted with this bilateral panuveitis, we asked



**Fig. 1 |** Fundus photos from the right and left eye, showing bilateral multifocal retinitis lesions, mainly in the macular area and near temporal vascular arcades, with some perilesional hemorrhages.

Apart from asthma and smoking habits, he had an otherwise unremarkable history until 3 weeks prior to presentation, when he reported fever and a sore throat, which was interpreted as acute tonsillitis, for which he was empirically treated with oral amoxicillin with clavulanic acid.

A few days later, however, he reported a generalized skin rash, “rough” to the touch and maculopapular in its

about other relevant personal history (such as oral or genital ulcers, sexual transmitted diseases, drug-abuse or other risky behaviours), recent travels abroad or to rural areas, outdoor activities, pets (namely dogs, cats and birds) or unpasteurized fresh cheese consumption, but he denied everything apart from a recurrent fungal balanitis. He was married for 7 years and denied other extramarital relationships.

## INVESTIGATIONS

A full blood count and renal and hepatic function tests were requested, as well as the erythrocyte sedimentation rate (ESR) and reactive c protein (RCP) levels, together with serologic tests for HIV 1/2, *Toxoplasma gondii*, *Treponema pallidum* (non-treponemic VDRL and antibodies anti-*Treponema pallidum*), *Rickettsia conorii*, *Bartonella henselae*, *Borrelia burgdorferi*, *Brucella* and *Coxiella burnetii*. An Interferon- $\gamma$  release assay (IGRA) test and anti-streptolysin O (ASO) titer were also requested, as well as antigenemia search for *Candida albicans*.

After consulting with Internal Medicine colleagues, blood cultures in aerobic and anaerobic conditions were conducted in addition to fungal blood cultures.

We also performed spectral-domain optical coherence tomography (SD-OCT), fluorescein angiography (FA) and head computed tomography (head-CT), considering the presence of a severe bilateral retinitis and systemic complaints.

## DIFFERENTIAL DIAGNOSIS

The clinical picture and history was somewhat misleading at the beginning and the retinitis lesions too severe to wait for the lab results.

The recent presumed tonsillitis and rash which looked like it could be scarlet fever made it mandatory to include a post-streptococcal uveitis in the differential, which, although rare, could explain the anterior uveitis and retinal vasculitis, and hence the ASO titer<sup>9</sup>.

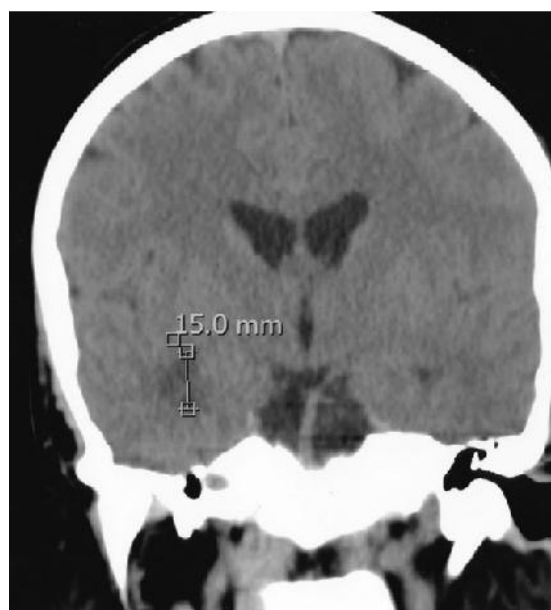
Rickettiosis<sup>1-7</sup> and Lyme's disease (caused by *Bartonella burgdorferi* infection)<sup>10,11</sup> could also explain the rash and fever, as well as the retinitis, but there was no epidemiological context, namely recent outdoor activities, contact with dogs or tick bites. Also, the skin rash wasn't characteristic of any of these, since boutonneuse fever typically courses with a maculopapular exanthema which also affects the palms and soles, and Lyme's rash tends to start as an oval or annular erythematous lesion with expanding borders that fades and recurs a few weeks later (erythema migrans).

Brucellosis<sup>12,13</sup> could also manifest itself with a maculopapular exanthema and retinitis, but there was also no epidemiological context, having denied consumption of raw milk and cheese. Syphilis<sup>14-16</sup> and tuberculosis<sup>17-19</sup>, the "great imitators" capable of inducing any type of uveitis, should always be included in the differential diagnosis, explaining for treponemic tests and IGRA.

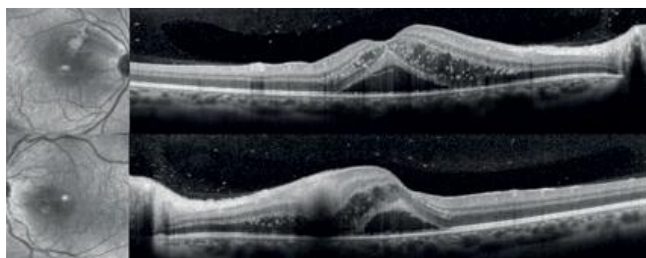
Finally, due to the recurrent fungal balanitis, and even though he was otherwise apparently healthy, fungal infection (especially by *Candida albicans*) was also considered as well as Behçet's disease, although he had no other clinical diagnostic findings, in particular oral or genital ulcers.

However, the only results immediately available were his blood count (unremarkable), a slightly elevated ESR (35mm/h) and RCP within normal range (<0.3mg/dL). He also tested negative for HIV 1/2, *T. gondii* (both IgM and IgG), VDRL and anti-treponemal antibodies, and the ASO titer was also considered normal (<197IU/mL). This allowed us to exclude syphilis, toxoplasmosis and post-streptococcal uveitis. The only positive finding was the antigenemia for *Candida albicans*, with the remaining serologies still unavailable at this time.

His head-CT (Figure 2) revealed a hypodense lesion with about 15 mm in diameter in the deep temporal white matter next to the temporal horn of the right ventricle, which seemed to correspond to edema, which in the clinical context was considered to be probably infectious or inflammatory in its nature. In light of this finding, we asked for a neurologist consult, who conducted a thorough neurologic examination (completely normal, apart from the visual disturbances) and a lumbar puncture. His cerebrospinal fluid analysis showed only a mild pleocytosis (9 cells, mainly mononuclear), with a normal biochemistry and negative microbiological and cytological exams. In order to better



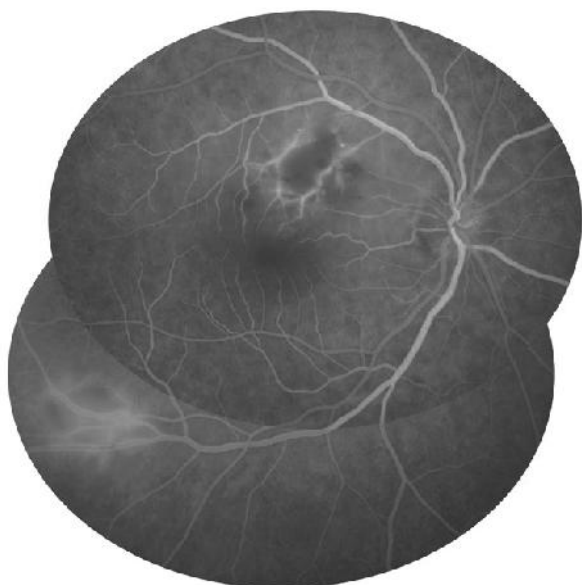**Fig. 2 |** Head-CT showing a hypodense lesion in the deep temporal white matter next to the temporal horn of the right ventricle with about 15 mm in diameter, without mass effect.



**Fig. 3 |** SD-OCT of the right (upper image) and left eye (lower image) showing bilateral intra and subretinal fluid leading to macular edema and neurosensory foveal detachment.

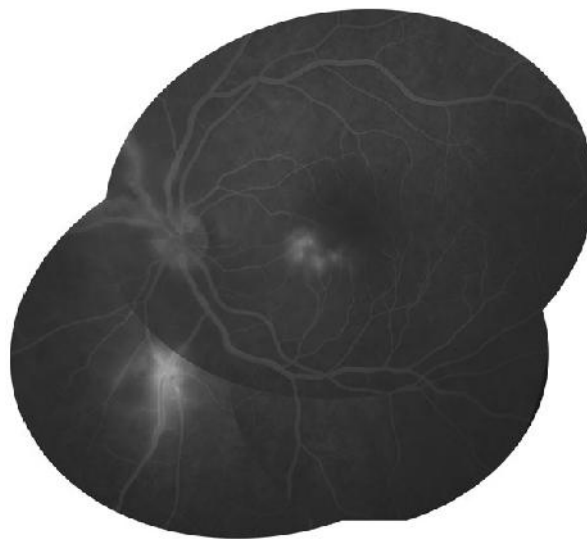
define the CNS lesion, we also performed a head magnetic resonance imaging (MRI), which confirmed the presence of a nonspecific lesion in the periventricular white matter with regular boundaries, hypointense in T1 and hyperintense in T2/FLAIR, with no contrast enhancement.

On SD-OCT (Figure 3), it was evident the bilateral presence of intra and subretinal fluid corresponding to macular edema and neurosensory foveal detachment. The FA, on the other hand, showed perilesional venous leakage with no other more peripheral lesions and no coexisting optic disc abnormalities (Figures 4 and 5).



**Fig. 4 |** Right eye's fluorescein angiography showing perilesional venous leakage and absence of optic disc abnormalities. No peripheral lesions found (not shown).

The patient was admitted and started empirical treatment with oral doxycycline 100mg b.i.d. and fluconazole 150mg/day, plus topical corticosteroid and cycloplegic for the anterior uveitis.



**Fig. 5 |** Fluorescein angiography of the left eye, showing similar findings.

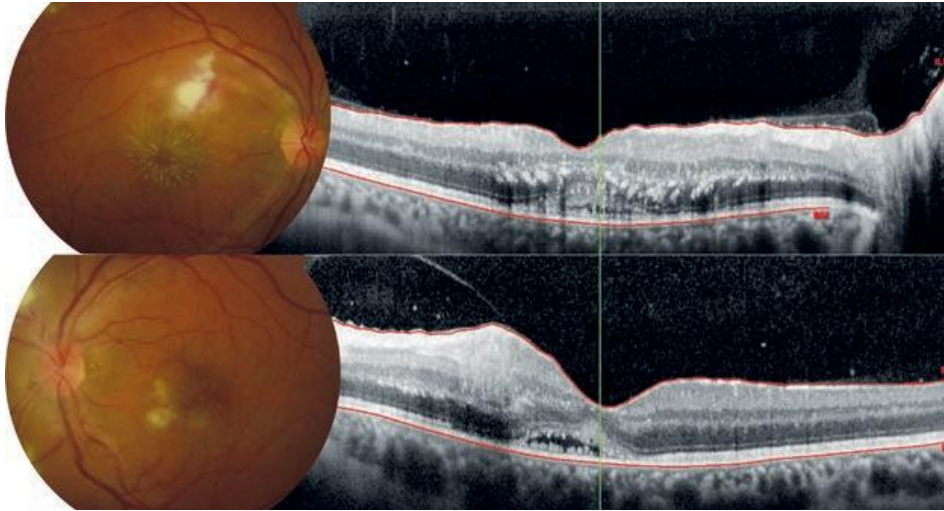
## TREATMENT

We decided to start oral doxycycline (100mg b.i.d.) until further results were available since we were dealing with a patient with severe multifocal retinitis and probable CNS involvement in a setting of fever and skin rash, and this would cover most of the possible diagnosis, including rickettiosis, *Bartonella* and *Brucella*. Fluconazole was also started since we had a history of recurrent fungal balanitis and positive peripheral antigenemia for *Candida albicans*.

Meanwhile, three days later the patient noted a drop in his vision. His BCVA had decreased to 20/400 (OD) and 20/160 (OS), and the retinitis lesions had not improved at all, with the appearance of a macular star in his right eye (Figure 7). At that time, we still had no other lab results available, and due to the clinical severity, with macular lesions leading to a marked visual loss, we decided not only to do an anterior chamber tap to collect aqueous humour for panbacterial DNA polymerase chain reaction (PCR) analysis and mycological culture, but also an intravenous methylprednisolone pulse (1g/day for 3 days).

Fortunately, it was evident an immediate visual and tomographic improvement, with reduction of the macular edema and subretinal fluid and partial VA recovery, with a BCVA of 20/63 and 20/32, in his right and left eye, respectively (Figure 6). In the meantime, the remaining results became available. The panbacterial DNA PCR analysis and aqueous humour microbiological exam were negative, as well as the serologies for *Bartonella* and *Borrelia* (IgM and



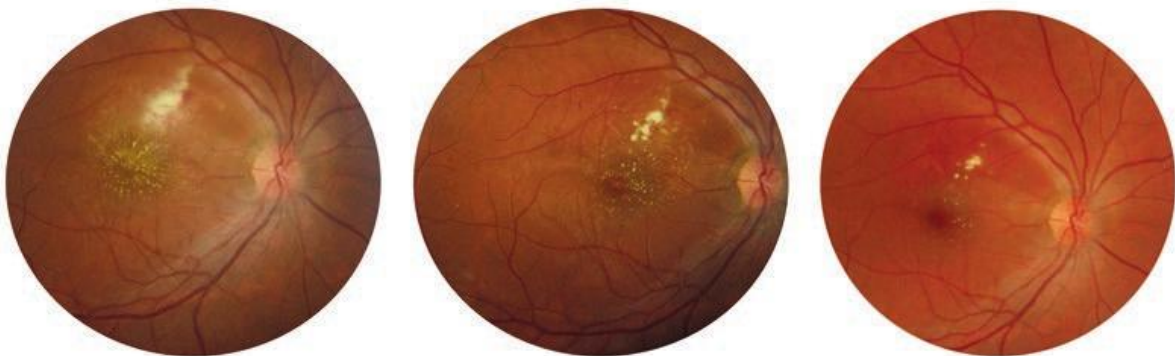

**Fig. 6 |** Fundoscopic appearance and SD-OCT after intravenous methylprednisolone and initial treatment with oral doxycycline showing marked improvement in the retinitis lesions and corresponding tomographic corresponding. The BCVA improved from 20/400 (OD) and 20/160 (OS) to 20/63 and 20/32, respectively.

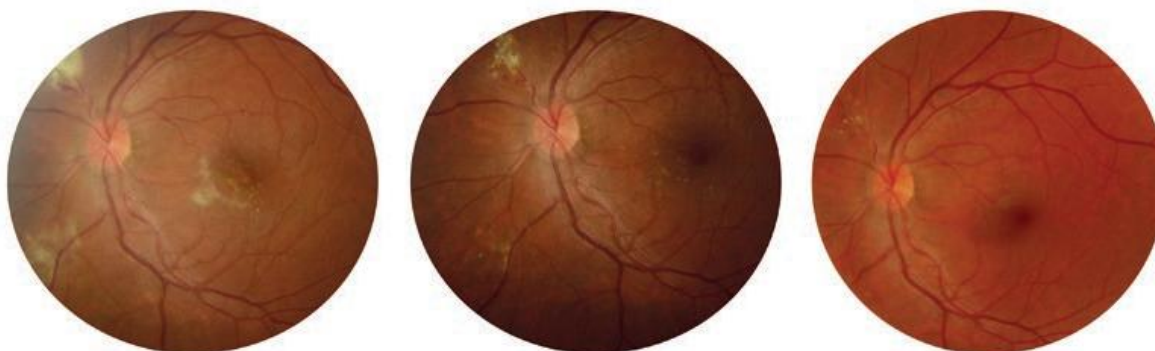IgG both negative). On the other hand, he tested positive for *Rickettsia conorii*, with an IgM antibody titer of 128 IU/mL. We were somewhat perplexed by this result, considering the negative panbacterial DNA PCR analysis, but upon further study we found that the 16s rRNA gene, present in most bacteria and detected by this PCR assay for classification and species identification is missing in *Rickettsia*! Even so, confronted with these findings, we decided to repeat serologies with a three-week interval and request a second, “targeted”, DNA PCR analysis in the peripheral blood for *R. conorii*. A four-fold increase was registered in the IgM titer (512 IU/mL), together with positive IgG antibodies (256 IU/mL), and the second PCR confirmed the *R. conorii* infection. Interestingly, his serologies were also positive for *Coxiella burnetii*, but this was interpreted as a cross-reaction due to the highly elevated IgM and IgG antibody titers for *R. conorii*.

In light of these findings, we kept the patient on doxycycline 100 mg b.i.d. for 3 weeks and on oral prednisolone, initially at 1 mg/kg/day with a slow taper afterwards. We also decided to maintain fluconazole, as previously discussed.

There was a sustained and progressive visual and anatomic improvement, with resolution of the retinitis lesions, macular edema and foveal detachment. After three weeks and having consulted with our internists and infectious diseases experts, we decided to lower the doxycycline dose to 100 mg once per day and slowly taper the prednisolone dose. Having completed six weeks of treatment, we then decided to stop fluconazole and at three months of follow-up, we suspended treatment altogether. By this time, his BCVA was 20/20 on both eyes with no anterior chamber reaction and the posterior segment lesions were almost completely gone (Figures 7 and 8).



**Fig. 7 |** Fundoscopic appearance of the right eye at 6th week (BCVA 20/63), 2nd month (BCVA 20/25) and 3rd month (20/20).



**Fig. 8 |** Sustained left eye's clinical improvement, with resolution of the retinitis lesions. Retinographies taken at 6 weeks (BCVA 20/25), 2 months (BCVA 20/20) and 3 months (BCVA 20/20).

## DISCUSSION

This case proved to be a diagnostic and therapeutic challenge since we were dealing with an apparently young patient with marked visual loss who had a rather “strange” retinitis, not particularly characteristic or pathognomonic of anything (almost resembling *Bartonella*-related neuroretinitis, but with no disc inflammation), and with a somewhat confounding previous history, hence the necessity to consider all the previously referred differentials.

Had he told us he had been bitten by a tick or played with dogs, it would have made the rickettsiosis diagnosis much more probable right away. The fact that serologic tests for *Rickettsia* may take up to two weeks to become positive did also contribute to a delayed diagnosis. However, due to the severity of the macular lesions, waiting for positive results (and their confirmation) was not an option, hence we decided to start empirical treatment with doxycycline, fluconazole and, as a sight-saving measure, intravenous methylprednisolone. This decision is certainly controversial and debatable, but we thought it was advisable regarding the fact that the clinical picture was deteriorating while already on antimicrobial therapy.

Rickettsiosis may have a number of ocular manifestations, ranging from conjunctivitis, keratitis and anterior uveitis to several posterior segment complications, such as retinitis, vascular involvement (with retinal hemorrhages, cotton wool spots and occlusions reported), macular edema, macular star, optic disc edema, optic neuritis and even extraocular complications such as III and VI cranial nerve palsies<sup>5-8</sup>. We found, however, only two revisions depicting in a more detailed way the most common posterior segment findings and discussing their treatment and prognosis<sup>5,6</sup>. Both reported vitritis as the most frequent finding, present in 75-90% of patients and generally mild. Interestingly, that was not our case, where we found no vitreous inflammation

whatsoever during the course of the disease, even though the patient, being immunocompetent had multiple active retinitis lesions.

The second most common finding in these reviews differed, being macular edema (50%) in the review by Agahan A. et al<sup>6</sup> and retinitis (30%) in the review published by Khairallah M. et al in 2004<sup>5</sup>. The retinitis lesions described were variable in size, topography (found on the posterior pole in about one half of the patients and in the periphery in the other half) and anatomic location (affecting either only the more superficial retinal layers in 53.3% of the cases or being full-thickness in the remaining 46.7%), but all white in colour and always perivascular.

A consistent finding by these authors is the presence of a focal, perilesional vascular involvement, mainly phlebitis (with only one patient presenting with diffuse vasculitis) with haemorrhaging in more than 20%, which is in accordance to our patient, whose FA showed focal, perilesional venular leakage with no other vascular abnormalities. *Rickettsia*'s tropism for endothelial cells easily explains this finding since it causes a disseminated vasculitis process which is also responsible for the skin rash.

Apart from the absence of vitritis, however, our patient had other distinct differences from most of the reported cases. For instance, macular star and serous retinal detachment, which were rare complications in both reviews (seen in 3.3% and 5% of the patients, respectively) and usually unilateral when present, were actually clear manifestations in our case, although the detachment was limited to the fovea in both eyes.

This is not only very uncommon but also an indicator of poor prognosis, hence our decision to treat with systemic corticosteroids. Another rare finding was the presence of a CNS lesion, which we haven't found described in other papers except in a case-report of a patient with optic neuritis and severe VA reduction, in which is reported a

periventricular lesion in the deep white-matter in all similar to ours<sup>8</sup>. Apparently, no neurological sequelae were evident secondary to this lesion, as it happened in our patient.

The authors also decided to do an intravenous methylprednisolone pulse followed by oral prednisolone for one month as a sight-saving measure and with no related complications (namely, worsening of the CNS lesion). We agree with this approach and although corticosteroid use should be judicious when the diagnosis isn't clear and in an infectious setting, we find it justifiable in severe cases when there's a high risk of permanent visual loss, such as when dealing with bilateral macular lesions with marked VA reduction.

Another point of controversy or doubt is related to the duration of the antibiotic treatment. Although it is given that tetracyclines (especially doxycycline, 100 mg b.i.d.) are the first-line antibiotics for rickettsiosis (even though there are some alternatives, like clarithromycin, fluoroquinolones and trimethoprim sulfamethoxazole), it is yet unclear for how long these should be prescribed. Although some authors defend treating all patients for 2 weeks<sup>5,8</sup>, some agree to a longer course (8 to 10 weeks)<sup>6</sup>, while we wonder if it should be based on clinical evolution and patient's tolerability. Being evident a sustained and progressive visual and anatomic improvement in our patient, and after consulting with our internists and infectious diseases experts, we decided to half the dosage after three weeks and keep the patient on 100 mg doxycycline per day until completing three months of treatment. We found that this (together, probably, with the systemic corticosteroids) was effective in the resolution of the retinal lesions and visual recovery.

Thankfully, posterior uveitis secondary to *Rickettsia conorii* appears to have a good overall prognosis<sup>5,7</sup> with resolution of all lesions in all patients and with over 90% achieving a BCVA of 20/20, although it can be worse if there's cystoid macular edema or cataract. It should be noted that it may take up to 3 to 10 weeks, or even longer, for full recovery, and a regular follow-up must be ensured.

## REFERENCES

1. Bazin R. Rickettsial diseases. In: Foster CS, Vitale AT, eds. Diagnosis and treatment of uveitis. Philadelphia: WB Saunders Co.; 2002:297-304.
2. Alio J, Ruiz-Beltran R, Herrero-Herrero JJ, et al. Retinal manifestations of Mediterranean spotted fever. *Ophthalmologica* 1987;195:31-37.
3. Jemni L, Hamouda H, Chakroun M, et al. Mediterranean spotted fever in central Tunisia. *J Travel Med* 1994;1:106-108.
4. Sousa, R, Nóbrega, SD, Bacellar F, et al. Sobre a realidade da fibrose escarosa-nodular em Portugal. *Acta Médica Portuguesa* 2003;16:429-436.
5. Khairallah M, Ladjimi A, Chakroun M, et al. Posterior segment manifestations of *Rickettsia conorii* infection. *Ophthalmology* 2004;111:529-534
6. Agahan A, Torres J, Fuentes-Páez G, et al. Intraocular inflammation as the main manifestation of *Rickettsia conorii* infection. *Clinical Ophthalmology* 2011;5:1401-1407.
7. Abroug N, Khochtali S, Kahloun R, et al. Ocular manifestations of rickettsial disease. *J Infect Dis Ther* 2014;2:3.
8. Hanen L, Mouna S, Faten F, et al. An unusual cause of optic neuritis: rickettsiosis disease. *Asian Pac J Trop Biomed* 2014;4(12):998-1000.
9. Wirosko WJ, Connor TB, Wagner, PF. Recurrent poststreptococcal uveitis. *Arch Ophthalmol* 1999; 117(12):1649-1650.
10. Steere AC. Lyme disease. *N Engl J Med* 1989;321:586-596
11. Steere AC, Bartenhagen NH, Craft JE, et al. The early clinical manifestations of Lyme disease. *Ann Intern Med* 1983;99:76-82.
12. Gungur K, Bekir NA, Namiduru M. Ocular complications associated with brucellosis in an endemic area. *Eur J Ophthalmol* 2002;12:232-237.
13. Rolando I, Olarte L, Vilchez, et al. Ocular manifestations associated with brucellosis: a 26-year experience in Peru. *Clin Infect Dis* 2008;1:1338-1345.
14. Arruga J, Valentines J, Mauri F, et al. Neuroretinitis in acquired syphilis. *Ophthalmology* 1985;92:262-270.
15. Morgan CM, Webb RM, O'Connor GR. Atypical syphilitic chorioretinitis and vasculitis. *Retina* 1984;4:225-231.
16. Jumper JM, Machemer R, Gallemore RP, et al. Exudative retinal detachment and retinitis associated with acquired syphilitic uveitis. *Retina* 2000;20:190-194.
17. Donahue HC. Ophthalmologic experience in a tuberculosis sanatorium. *Am J Ophthalmol* 1967;64: 742-748.
18. Darrell RW. Acute tuberculous panophthalmitis. *Arch Ophthalmol* 1967;78:51-54.
19. Coles RS. Uveitis associated with systemic disease. *Surv Ophthalmol* 1963;8:377-392.

No commercial interests to report.

## CONTACTO

André Marques  
Rua Marques de Pombal nº287A 3º andar.  
2775-265 Parede  
E-mail: andresalgadomarkes@gmail.com