

Ophthalmology case

*Fábio Barroso¹, Ana Lachado¹, Luísa Carreira¹,
Gilberta Santos¹, José Pombeiro¹, Vasco Miranda¹*

Following an uneventful pregnancy, a full-term, female infant was born by normal vertex delivery from a 29-year old primigravida. Family history was unremarkable. Apgar scores were nine and ten at first and fifth minute, respectively, and birth weight was 2720 g (P 3-10). On the first day of life physical examination revealed a whitish, ovoid mass, 0.5 mm by 0.25 mm, that straddled the inferotemporal limbus of the left eye (Figure 1). The red eye reflex was normal and symmetrical in both eyes. The eyelids had no abnormalities and complete eye closure was present whilst sleeping, with no corneal exposure or lagophthalmos. The cornea was transparent on all quadrants; the anterior chamber was fully formed; the pupil was circular, centred and photoreactive, with no iris malformations or

anterior corneal adhesions; fluorescein test showed no corneal epithelial defects. The crystalline lens was transparent and no vitreal abnormalities were evident. Mydriatic fundoscopy was symmetrical in both eyes and revealed round optic disks with well-defined borders, no pallor and no excavation; both venous and arterial retinal vasculature showed no engorgement and there were no retinal haemorrhages; there was a slight retinal pigmented epithelium hypopigmentation adequate in newborns, with visualization of the choroidal vessels on zone II but normal orange-red coloured macular pigmentation. Other physical examination was unremarkable.

What is your diagnosis?

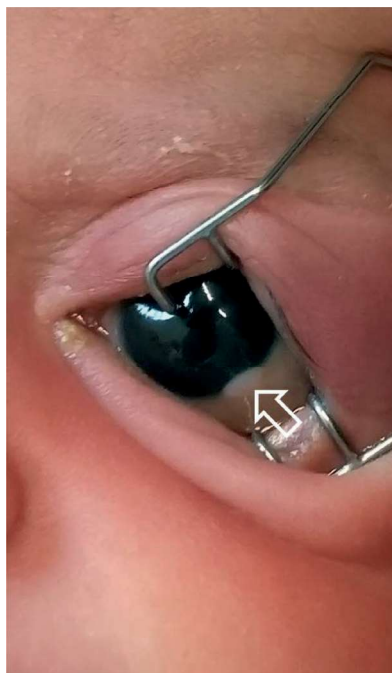


Figure 1

¹ Department of Neonatology and Neonatal Intensive Care, Centro Materno Infantil do Norte, Centro Hospitalar do Porto. 4050-371 Massarelos, Portugal.

fabiodmb87@gmail.com; alachado@campus.ul.pt; luisamcarreira@sapo.pt; gilberta_santos@hotmail.com; josepombeiro@gmail.com

¹¹ Department of Ophthalmology, Hospital de Santo António, Centro Hospitalar do Porto. 4099-001 Porto, Portugal. vm.miranda@gmail.com

DIAGNOSIS

Limbal Dermoid Cyst

DISCUSSION

Epibulbar dermoids are congenital benign episcleral choristomas (tissue that is not found normally at that location), which includes cells from ectodermal and mesodermal origin. Choristomas may present unilaterally or bilaterally, representing almost 3% of all conjunctival and corneal tumors. They usually are not inherited, although some exceptions have been described, such as in some familial systemic disorders such as Goldenhar's syndrome (preauricular appendages, preauricular fistulae and epibulbar dermoids or lipodermoids) and the mandibulofacial dysostosis of Treacher Collins Syndrome.

Anatomically, epibulbar dermoids have been classified into three grades. Grade I limbal dermoids are superficial lesions localized to the limbus and measuring less than 5 mm. Grade II limbal dermoids are larger involving part of the corneal stroma and grade III are even larger covering the whole cornea and penetrating the anterior chamber.

Limbal dermoids have a global estimated incidence of 1 to 3 per 10.000. They are present at birth but may not be easily identified until the first or second decade of life. One accepted theory suggests that limbal dermoids are the result of an early embryological error leading to metaplastic transformation of the mesoblast between the rim of the optic nerve and surface ectoderm. They may contain a variety of histologically abnormal tissues, including hair follicles, sebaceous gland acini, lacrimal gland, teeth, cartilage, bone, vascular structures, brain. Malignant transformation is extremely rare.

The classical morphology of limbal dermoids is an elevated whitish or yellow round and smooth mass overlying both the cornea and conjunctiva. It appears most commonly in the inferotemporal quadrant as a solitary lesion but sometimes presents as multiple lesions.^{1,2}

Medical treatment is usually reserved for grade I dermoids, inducing only mild astigmatism < 1D, so management can be made with spectacle correction. For small asymptomatic grade I limbal dermoids, it is actually recommended that these children undergo clinical observation with serial examinations because surgery procedures may lead to scarring and pseudopterygium. During each clinical examination, lesion dimensions, visual acuity and presence or absence of amblyopia must be defined. In this grade, there are well established criteria for surgical intervention: development of clinically amblyopia or significant anisometropia; growth of limbal dermoid inducing marginal dellen and increasing anisotropic astigmatism; non-compliance on corrective spectacle-wear and cosmetic reasons.²

Surgery is recommended for grade II and III limbal dermoids, given that they usually cause refractive or occlusive amblyopia.^{2,3}

A wide variety of surgical correction techniques have been described in literature, ranging from simple excision to lamellar/penetrating keratoplasty. Other recent techniques include limbal donor stem cell transplantation, surgical resection followed by

amniotic membrane transplantation or a combination of corneal tattooing and a limboconjunctival autograft using fibrin glue. Surgical sequelae include persistent epithelial defects, peripheral corneal vascularization and opacity.³⁻⁵

In conclusion, we present a case of limbal dermoid cyst diagnosed in the immediate neonatal period, allowing a close clinical follow-up by a pediatric ophthalmologist in order to offer the most appropriate treatment throughout the child's life. The authors want to reinforce the need to perform a careful eye examination of the newborn in order to early detect this and other congenital malformations of the ocular system.

ABSTRACT

Introduction: Limbal dermoids are benign congenital tumours that contain choristomatous elements. These lesions are present at birth but may not be easily identified until later in life.

Case report: We report a case of a one-day-old newborn, female, with no relevant gestational or neonatal history, referred to our pediatric ophthalmologic unit because of a whitish round mass in the inferotemporal limbus of the left eye. Clinical examination confirmed the diagnosis of limbal dermoid cyst, and she was referred to ophthalmologic consultation for clinical follow-up.

Discussion: The diagnosis of limbal dermoids is established by the presence of a yellow/white solid tumour located at the limbus. These lesions have been classified into three grades. The treatment for grade I pediatric limbal dermoids is initially conservative. In stages II and III, a combination of simple excision, lamellar keratoplasty, sutureless amniotic membrane and limbal stem cell transplantation may be necessary. Prognosis is generally favourable.

Keywords: limbal dermoid; dermoid cyst; ocular surface; amblyopia

RESUMO

Introdução: Os dermóides límbicos são tumores benignos que contêm coristomas. Estas lesões estão presentes desde o nascimento, mas podem não ser facilmente reconhecidas até idades mais avançadas.

Caso Clínico: Descrevemos o caso de um recém-nascido, do sexo feminino, com um dia de vida, sem antecedentes pré-natais ou neonatais de relevo, referenciada ao Serviço de Oftalmologia do nosso centro por apresentar uma tumefacção arredondada e esbranquiçada na região inferotemporal do limbo do olho esquerdo. A observação clínica confirmou o diagnóstico de quisto dermóide límbico, tendo sido orientada para consulta de oftalmologia para monitorização clínica.

Discussão: O diagnóstico dos dermóides límbicos estabelece-se pela presença de uma massa tumoral sólida de coloração amarelada/esbranquiçada na região límbica. Estas lesões têm sido classificadas em três graus. Atualmente, o tratamento dos dermóides límbicos de grau I é inicialmente conservador. Por outro lado, nos de grau II ou III, uma combinação de excisão simples, queratoplastia lamelar, aplicação de membranas am-

nióticas e transplante de células límbicas podem ser necessárias. O prognóstico é geralmente favorável.

Palavras-chave: Dermóide límbico; quisto dermóide; superfície ocular; ambliopia

Nascer e Crescer – Birth and Growth Medical Journal
2017; 26(2): ??-?

CORRESPONDENCE TO

Fábio Barroso
Department of Neonatology and
Neonatal Intensive Care
Centro Materno Infantil do Norte
Centro Hospitalar do Porto
Largo da Maternidade de Júlio Dinis,
4050-371 Massarelos
Email: fabiodmb87@gmail.com

REFERENCES

1. Pirouzian A. Management of pediatric corneal limbal dermoids. *Clin Ophthalmol* 2013; 7:607-14.
2. Shields JA, Shields CL. Orbital cysts of childhood: classification, clinical features, and management. *Surv Ophthalmol* 2004; 49:281-99.
3. Jeong J, Song YJ, Jung SI, Kwon JW. New Surgical Approach for Limbal Dermoids in Children: Simple Excision, Corneal Tattooing, and Sutureless Limboconjunctival Autograft. *Cornea*. 2015; 34:720-3.
4. Amescua G, Atallah M, Nikpoor N, *et al*. Modified simple limbal epithelial transplantation using cryopreserved amniotic membrane for unilateral limbal stem cell deficiency. *Am J Ophthalmol*. 2014;158: 469-75.
5. Watts P, Michaeli-Cohen A, Abdoell M, *et al*. Outcome of lamellar keratoplasty for limbal dermoids in children. *J AAPOS*. 2002; 6:209-15.

Received for publication: 22.12.2016
Accepted in revised form: 01.03.2017