

IMAGING CASES

A dangerous secret – A case report of battery ingestion

Um segredo perigoso – Um caso clínico de ingestão de pilha

Ana Catarina Fernandes¹ , Mariana Gaspar¹ , Maria Bandeira Duarte¹ , Alexandra Gavino¹ , Aldina Lopes¹ 

A previously healthy nineteen-month-old boy presented to the Emergency Department with vomiting, abdominal pain, and prostration with three days of evolution and fever for a day. There was no history of drooling, refusal to feed, or changes in bowel movements. The parents initially associated these symptoms with the introduction of cow's milk into the diet. No further information was provided. On physical examination, the child appeared ill, but there were no other specific findings. Additional investigations were requested. Laboratory tests showed elevated inflammatory parameters, and abdominal ultrasound showed no changes. A chest x-ray showed a round, double-ring, radiopaque foreign body, without ectopic air, around T4-T5, approximately 20 millimeters, suspected to be a battery (*Figure 1*), and the child was immediately referred for endoscopic removal.

What is your diagnosis?

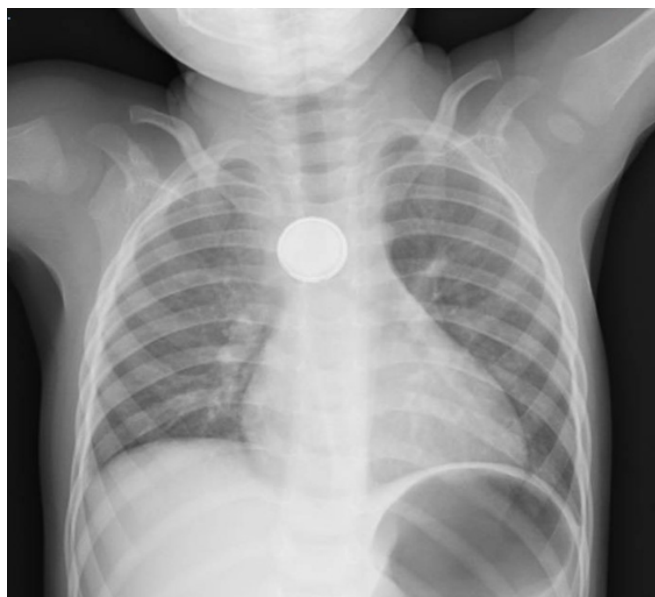


Figure 1 - Chest radiograph showing a round, double-ring, radiopaque image around T4-T5 suspected of being a coin or a battery. The double ring/halo determined that it was a battery.

1. Department of Pediatrics, Hospital Distrital de Santarém. 2005-177 Santarém, Portugal.
acf_anacatarina@hotmail.com; mariana_sgasp@hotmai.com; mbandeiraduarte@gmail.com; alexandra33@gmail.com; aldina.lopes@hds.min-saude.pt

DISCUSSION

Foreign body ingestion is a common problem between the ages of six months and three years.⁽³⁾ Most caregivers report a history of foreign body ingestion, which did not occur in this case.^(1,3)

When ingestion is not witnessed or reported, suspicion should be raised in children with intellectual disability, since clinical symptoms are not specific.⁽¹⁾ Stridor, drooling, fussiness, chest pain, abdominal pain, fever, feeding refusal, wheezing, and respiratory distress are all possible manifestations of foreign body ingestion.^(1,4)

Management of foreign body ingestion depends on the type of foreign body (button batteries, magnets, sharp/pointed objects, food impaction, coins/blunt objects, superabsorbent objects), its location within the gastrointestinal tract, timing of the ingestion, clinical presentation, and patient size.⁽⁴⁾ The approach may be expectant in some cases or require emergent removal in others.^(1,4)

Imaging with conventional radiograph of the neck, chest, and abdomen should be considered in all patients with suspected foreign body ingestion, even if the suspected object is not radiopaque, due to the possibility of other swallowed objects or ectopic air indicating perforation.⁽¹⁾ Distinguishing between similarly shaped objects, such as coins and button batteries, can be difficult but is essential for a correct approach. Therefore, the radiograph should be carefully examined to distinguish between a coin and a battery.⁽¹⁾ A double ring/halo sign on an anteroposterior radiograph suggests the presence of a battery.^(1,3,4)

Coins are the most commonly ingested foreign bodies and are usually not an emergency.⁽¹⁻³⁾ When a coin is located in the esophagus, removal is considered if there are severe clinical symptoms or if the coin does not move spontaneously after 24 hours of ingestion.⁽¹⁾ A battery in the esophagus can rapidly cause serious health hazards due to its capacity for caustic injury, requiring early diagnosis and emergent removal to prevent complications.^(3,4)

Possible complications of a battery lodged in the esophagus include mucosal burns, perforation, stricture, vocal cord paralysis, tracheoesophageal fistula, mediastinitis, bleeding (from an aortoenteric fistula), and death.^(1,3,4) Damage can be induced in only one hour and involve all layers of the esophagus in only four hours.⁽³⁾ Emergent endoscopic removal of the battery is the main approach.^(3,4)

CONCLUSION

In the present case, the ingestion was not witnessed, and the symptoms evolved over 72 hours. This highlights the importance of the differential diagnosis of foreign body ingestion in the considered age group due to the potential consequences of ingestion of this type of material.

ABSTRACT

Foreign body ingestion is a common problem in Pediatrics that can be fatal.⁽¹⁻³⁾ Because the clinical presentation is unspecific, the diagnosis is usually based on the history reported by the caregivers and confirmed by radiograph.⁽¹⁻³⁾ If history is not reported, the diagnosis can be challenging, so a high index of suspicion is required. The differentiation between foreign bodies of similar size and shape is also essential to define the urgency of the approach.⁽¹⁻³⁾ A case of unwitnessed button battery ingestion is presented in this report.

Keywords: battery; coin; foreign body; radiograph

RESUMO

A ingestão de um corpo estranho é um problema frequente em Pediatria, podendo ser fatal.⁽¹⁻³⁾ A apresentação clínica é inespecífica, sendo o diagnóstico facilitado pela história fornecida pelos cuidadores e confirmado radiologicamente.⁽¹⁻³⁾ Na ausência de história, o diagnóstico pode ser desafiante, pelo que é necessário um elevado índice de suspeição. É também essencial distinguir radiologicamente objetos de formato/tamanho semelhante, de modo a determinar a urgência da remoção do corpo estranho.⁽¹⁻³⁾ Este artigo relata um caso de ingestão não testemunhada de uma pilha.

Palavras-chave: corpo estranho; moeda; pilha; radiografia

AUTHORSHIP

Ana Catarina Fernandes - Writing – original draft; Writing – review & editing

Mariana Gaspar - Data curation; Investigation; Resources

Maria Bandeira Duarte – Data curation; Investigation; Resources

Alexandra Gavino - Writing – original draft; Writing – review & editing

Aldina Lopes - Project administration; Supervision; Validation

REFERENCES

1. Connors GP. Pediatric foreign body ingestion. <https://www.ncbi.nlm.nih.gov/books/NBK430915/>. Last Updated: January 23, 2019.
2. Gilger MA. Foreign bodies of the esophagus and gastrointestinal tract in children. UpToDate, February 2019.
3. Kelly Sinclair. Button and cylindrical battery ingestion: Clinical features, diagnosis, and initial management. UpToDate, January 2019.
4. Kramer RE, Lerner DG, Lin T, Manfredi M, Shah M, Stephen TC, *et al.* Management of Ingested Foreign Bodies in Children:

A Clinical Report of the NASPGHAN Endoscopy Committee. J
Pediatr Gastroenterol Nutr. 2015; 60(4): 562-74. doi: [https://doi.
org/10.1097/MPG.0000000000000729](https://doi.org/10.1097/MPG.0000000000000729).

CORRESPONDENCE TO

Ana Catarina Fernandes
Department of Pediatrics
Hospital Distrital de Santarém
Av. Bernardo Santareno 3737B
2005-177 Santarém
Email: acf_anacatarina@hotmail.com

Received for publication: 24.01.2021

Accepted in revised form: 04.11.2021