

IMAGING CASES

NEONATAL CRANIAL BONE DEPRESSION

DEPRESSÃO ÓSSEA CRANIANA NEONATAL

Joana Tenente¹, Ivana Cardoso¹, António Vinhas da Silva², Jacinto Torres²

A female preterm neonate with 1425 g of birth weight and fetal growth restriction in the third trimester was delivered by C-section at 34 weeks of gestational age. No trauma was described during pregnancy or delivery. Apgar scores at 1 and 5 minutes were 8 and 9, respectively. The head circumference was 29.5 cm (10th–50th centile for age) and the physical examination was unremarkable. The girl was admitted to the Neonatal Intensive Care Unit for late prematurity and very low weight.

On day three of life, a hard left parietal depression with approximately 3x3 cm of size and 2 cm of depth was noted (**Figure 1**). There was no evidence of pain or neurological impairment nor of other physical abnormalities. Calcium-phosphate metabolism was evaluated, with normal phosphate, calcium, and vitamin D values. Skull radiograph revealed an abnormal concavity in the left parietal bone. Head computed tomography (CT) showed a focal sinking of the left parietal bone posteriorly to the coronal suture, with no lytic or blastic bone lesions or epicranial or intracranial soft tissue component. A fracture line was also noted posteriorly and superiorly to this sinking and extending to the sagittal suture, most likely corresponding to the coaptated linear fracture (**Figures 2 and 3**). A watchful approach was adopted and the patient was discharged on day 28, maintaining follow-up at the Neurosurgery and Neonatology outpatient departments. At two months of chronological age, the parietal fracture was barely perceptible, and neurological examination was normal.

What is your diagnosis?

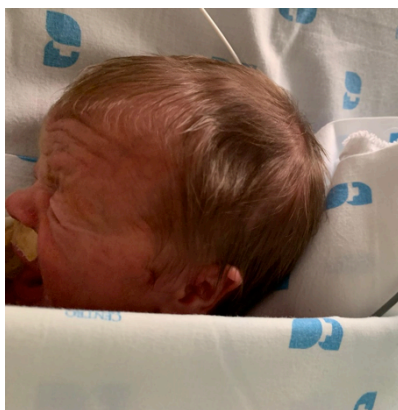

Figure 1 - Left parietal skull depression with approximately 3x3 cm of size and 2 cm of depth

1. Department of Pediatrics, Unidade I, Centro Hospitalar Vila Nova de Gaia/Espinho. 4434-502 Vila Nova de Gaia, Portugal. joanatenente@hotmail.com; ivana.oliveira.cardoso@gmail.com
2. Department of Pediatrics, Unidade I, Centro Hospitalar Vila Nova de Gaia/Espinho. 4434-502 Vila Nova de Gaia, Portugal. vinhasdasilva@gmail.com; jacintotorres@gmail.com

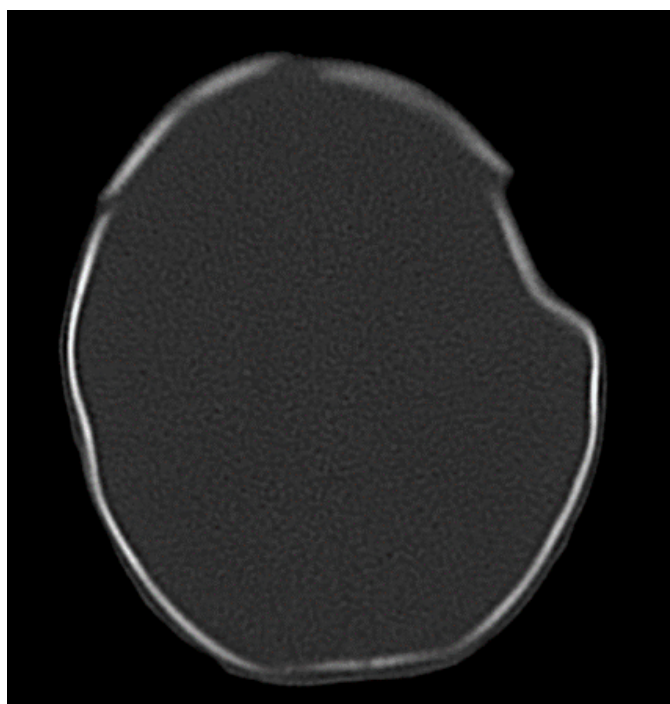


Figure 2 - Head computed tomography showing focal sinking of the left parietal bone posteriorly to the coronal suture, corresponding to a probable "ping-pong" fracture

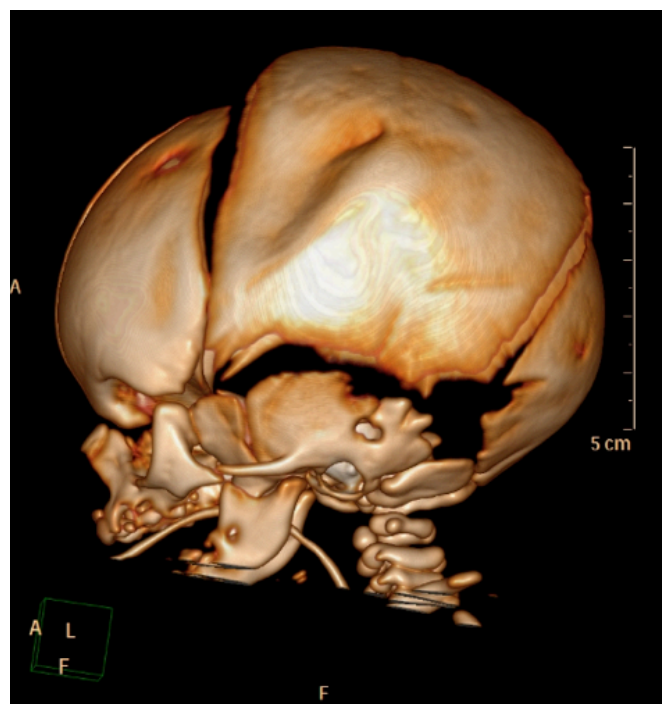

Figure 3 - Three-dimensional CT reconstruction showing invagination of the parietal bone (arrow)

DIAGNOSIS

Ping-pong fracture

Depressed skull fractures in newborns are rare, with an estimated incidence of 1–2.5 cases per 10,000 live births.¹ These “greenstick” fractures are referred to as ‘ping-pong fractures’ because of the resemblance to an indented ping-pong ball.² They develop in two distinct forms: iatrogenic (secondary to birth trauma) or spontaneous.¹ Spontaneous intrauterine skull fractures are thought to be caused by compression against the maternal ischial bone, sacral promontory, symphysis pubis, uterine fibroid, fifth lumbar vertebrae, and fetal hands or part of a twin or asymmetrical pelvis.¹

Regarding location, most fractures involve the parietal bone, with frontal and occipital bones less frequently implicated.³ This is due to immature ossification and prolonged focal pressure on a neonatal skull with membranous sutures, fontanelles, and low calcium levels, with consequent indentation of the bone surface and undisrupted bone continuity.^{1,2}

Skull radiography can show the degree of deformity and cranial ultrasound can identify hemorrhages and/or hematomas, but computed tomography is the most accurate exam to describe the

lesion and should be performed to confirm the diagnosis and exclude complications.⁴

The prognosis is good in spontaneous cases and those with a normal neurological examination.^{1,4,5} A watchful attitude is advised since many fractures can elevate spontaneously within four to six months.^{1,5}

Available treatments include surgical elevation, elevation by digital pressure on the edges of the depression, and elevation by vacuum extractor or breast pump.⁵ Surgical treatment is reserved for selected cases with cerebrospinal fluid leak, wound infection, hematoma, bone fragments within the brain parenchyma, neurological deficits, signs of increased intracranial pressure, or cosmetically deforming defects.^{2,3,5}

ABSTRACT

A female preterm was admitted to the Neonatal Intensive Care Unit for late prematurity and very low weight. The physical examination was normal. On the third day of life, a hard left, non-painful parietal depression was noted, with no evidence of neurological impairment. Head computed tomography (CT) showed focal sinking of the left

parietal bone posteriorly to the coronal suture. A watchful attitude was adopted and the patient was discharged on day 28. The diagnosis was a "ping-pong fracture", which can occur iatrogenically or spontaneously in uterus. This diagnosis can be confirmed by x-ray or CT scan and the prognosis is usually good, with complete deformity regression. At two months, the parietal fracture was barely perceptible, and neurological examination was normal.

Keywords: bone depression, newborn, ping-pong fracture, spontaneous fracture

RESUMO

Uma recém-nascida foi internada nos cuidados intensivos neonatais por prematuridade tardia e muito baixo peso, com um exame objetivo normal à admissão. No terceiro dia de vida, foi detetada uma depressão óssea parietal esquerda, dura, não dolorosa e sem implicações neurológicas aparentes. A tomografia computadorizada (TC) evidenciou um afundamento focal do osso parietal esquerdo posterior à sutura coronal. Foi decidido manter vigilância clínica e a recém-nascida teve alta ao 28º dia de vida. O diagnóstico foi uma "fratura do tipo ping-pong", que podem ocorrer de forma iatrogénica ou espontânea no útero. O diagnóstico pode ser confirmado por radiografia ou TC e o prognóstico é geralmente favorável, com regressão completa da deformidade óssea. Aos dois meses, a fratura era praticamente impercetível e o exame neurológico normal.

Palavras-chave: depressão óssea, fratura espontânea, fratura ping-pong, recém-nascido

REFERENCES

1. Ilhan O, Bor M, Yukkaldiran P. Spontaneous resolution of a ping-pong' fracture at birth. *BMJ Case Rep.* 2018;2018:8-10. doi:10.1136/bcr-2018-226264.
2. Sorar M, Fesli R, Gürer B, Kertmen H, Sekerci Z. Spontaneous elevation of a ping-pong fracture: Case report and review of the literature. *Pediatr Neurosurg.* 2013;48(5):324-326. doi:10.1159/000351412.
3. Ballesteros MF, De Oliveira RS. Closed Depressed Skull Fracture in Childhood Reduced with Suction Cup Vacuum Method: Case Report and a Systematic Literature Review. *Cureus.* 2019;11(7). doi:10.7759/cureus.5205.
4. Silva JB, João A, Miranda N. Fratura em Pingue-Pongue no Recém-Nascido : Um Diagnóstico Raro Ping-Pong Fracture in Newborn : A Rare Diagnosis. 2019;32:20344.
5. Loire M, Barat M, Mangyanda Kinkembo L, Lenhardt F, M'buila C. Spontaneous ping-pong parietal fracture in a newborn. *Arch Dis Child Fetal Neonatal Ed.* 2017;102(2):F153-F161. doi:10.1136/archdischild-2015-310313.

CORRESPONDENCE TO

Joana Tenente
Department of Pediatrics
Unidade I
Centro Hospitalar Vila Nova de Gaia/Espinho
Rua Conceição Fernandes s/n
4434-502 Vila Nova de Gaia
Email: joanatenente@hotmail.com

Received for publication: 01.02.2021

Accepted in revised form: 16.02.2021