

IMAGING CASES

Dermatology clinical case

Caso clínico dermatológico

Ana Sofia Figueiredo¹ , Carolina Quintela¹ , Susana Machado² , Glória Velho² , Jorge França Santos³ 

A ten-year-old boy observed during a routine pediatric visit presented with nail changes on the hands and toes and a concomitant skin lesion on the sole of the foot. Fever, pain, or direct contact with similar lesions were denied. Family history revealed that the mother was followed in rheumatology for suspected autoimmune disease and the grandmother had rheumatoid arthritis.

On physical examination, the boy presented with yellow and thickened proximal and lateral nail folds on the right hallux and fourth toe of the left foot (**Figure 1**) and an erythematous squamous plaque on the sole of the right foot (**Figure 2**). Ten months later, the boy presented with multiple yellowish, scaly, and thickened finger and toe nails (**Figure 3**).

What is your diagnosis?

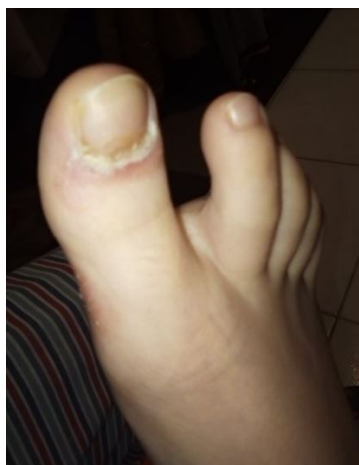

Figure 1

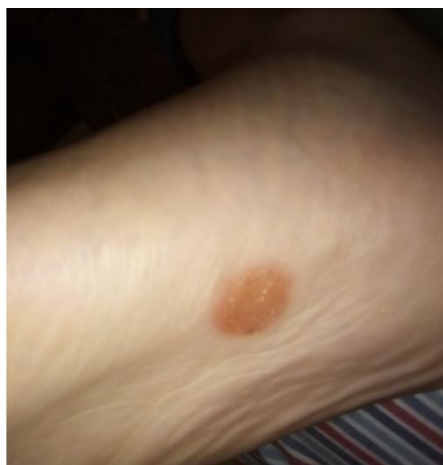

Figure 2

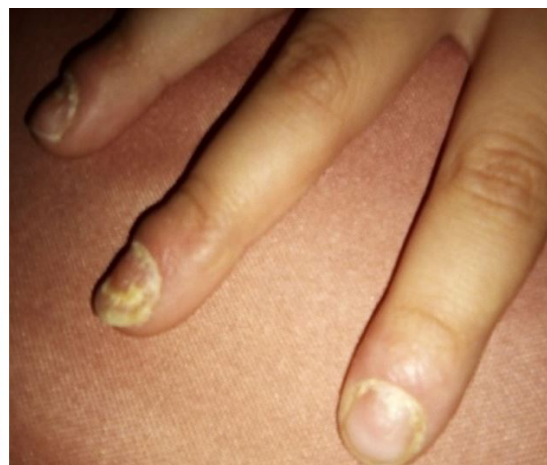


Figure 3

1. Department of Neonatology and Pediatrics, Unidade de Vila Real, Centro Hospitalar de Trás os Montes e Alto Douro. 5000-508 Vila Real, Portugal. sofiafigueiredo.94@gmail.com; carolina.quintelam@gmail.com
2. Department of Dermatology, Centro Hospitalar Universitário de Santo António. 4099-001 Porto, Portugal. susanamlmachado@gmail.com; gloriacunhavelho@gmail.com
3. Department of Neonatology and Pediatrics, Unidade de Chaves, Centro Hospitalar de Trás os Montes e Alto Douro. 5000-508 Vila Real, Portugal. jmfrancasantos@hotmail.com

DIAGNOSIS

Nailpsoriasis

DISCUSSION

Psoriasis is a systemic inflammatory disease that affects the skin, mucous membranes, phanera (nails and scalp), and joints, with variable presentation and severity. The average age of onset is 7-10 years, meaning that one third of adults with psoriasis have their first symptoms before the age of 20.^(1,2) A positive first-degree family history is reported in 17% of children and adolescents with psoriasis, possibly predicting more severe disease.^(1,3)

Similar to adults, the most common type of psoriasis in children is plaque psoriasis, which presents as erythematous plaques with a silvery-white scale typically affecting the limbs, scalp, postauricular region, elbows, knees, and umbilicus. Children may have thinner plaques with irregular borders and more facial and anogenital involvement than adults, with facial psoriasis being the sole manifestation in 4-5% of cases and anogenital psoriasis being the most common manifestation under two years of age.^(1,4) Anogenital involvement, possibly related to the Koebner phenomenon (appearance of skin lesions on previously unaffected skin secondary to trauma), presents as a large area of confluent erythema or salmon-colored patches or plaques.^(1,2) Guttate psoriasis and psoriatic arthritis are also more common in children. The former manifests as drop-like, erythematous, scaly, small papules on the trunk and extremities, often preceded by group A beta-hemolytic streptococcus infection, and the latter is characterized by joint pain, most commonly affecting the fingers and toes.⁽⁴⁾

Childhood psoriasis has a wide spectrum of physical manifestations, with nail involvement occurring in 12-32% of cases. Nail psoriasis may manifest as plate dystrophy, leukonychia, hyperkeratosis, and nail fold involvement, as described in the present patient. Other nail lesions described in the literature may include pitting, splinter hemorrhages, oil droplets, and salmon spots, among others.^(1,5)

Because most patients with nail psoriasis have concomitant cutaneous psoriasis or psoriatic arthritis, the patient history should include an assessment of personal history for signs or symptoms of these conditions. A strong family history of psoriasis may also raise suspicion of nail psoriasis in a patient with no other manifestations. A complete skin examination, including nails, scalp, and anogenital skin, should also be performed to evaluate for other psoriasis-related changes.⁽¹⁾

The diagnosis of nail psoriasis is clinical. Differential diagnosis with onychomycosis can be challenging due to overlapping clinical features. In addition, psoriatic nail involvement may predispose to secondary fungal infection, most commonly caused by *Candida parapsilosis* and dermatophytes, in up to 1/3 of patients.

Consequently, treatment of psoriasis with systemic agents without treatment of the concomitant fungal infection may lead to an unsatisfactory therapeutic outcome.⁽⁶⁾

In addition to onychomycosis, seborrheic dermatitis should also be considered in the differential diagnosis of nail psoriasis. The condition is characterized by pink-yellow to reddish-brown patches with greasy scales, but psoriasis plaques tend to be thicker, silvery white, and unrelated to seborrhea. Lichen planus also presents with a pruritic papulosquamous eruption, usually on the extremities, and with nail inflammation, which rarely results in permanent destruction of the nail matrix. Pityriasis rosea is the less likely diagnosis, affecting the trunk and producing the classic "Christmas tree" pattern.⁽⁷⁾

Data on the management of psoriasis in children are limited, so treatment should be individualized based on scientific evidence and clinical experience. Most patients have mild to moderate disease with good therapeutic response to topical agents. In these cases, the first-line treatment is topical corticosteroids with vitamin D analogues, which optimizes the clinical response and reduces the risk of corticosteroid-induced side effects (skin atrophy and stretching, acne).⁽¹⁾ Narrow-band UVB phototherapy is safe and effective, but less attractive because it requires two to three sessions per week in the hospital.⁽¹⁾ A few patients with moderate to severe psoriasis or refractory to topical treatment/phototherapy are treated with systemic agents. Methotrexate is the most common option, followed by acitretin and cyclosporine, which require regular analytical and clinical control. Recently, etanercept (>4 years of age), adalimumab (>4 years of age), and ustekinumab (>12 years of age) have been indicated as preferred therapeutic options in children due to their targeted action with less toxicity and less frequent laboratory monitoring.⁽⁸⁾

In the present case, the boy was initially treated with topical antifungal agents, with poor response. Later, during clinical follow-up, he presented with two erythematous squamous lesions on the foot and trunk, as well as erythema and penile skin plaques confirming the diagnosis of psoriasis made in collaboration with dermatology specialists. Excellent results were achieved after treatment with topical betamethasone/calcipotriol and a period of oral acitretin, with no side effects.

The complexity of nail psoriasis requires the involvement of a multidisciplinary team with psychosocial support. Indeed, several factors need to be considered before treatment, including age, disease extent and location, previous treatment and results, and presence of comorbidities.^(2,4) Patients with psoriasis have an increased cardiovascular risk (3-4 times increased risk of hypertension, diabetes, dyslipidemia) and a higher prevalence of mental disorders such as depression, anxiety, and alcohol or drug abuse, which are associated with significant impact on quality of life.⁽⁹⁾

In conclusion, this case highlights the importance of differential diagnosis and work-up and regular follow-up in a less common presentation of a known disease.

ABSTRACT

Psoriasis is a systemic disease that commonly affects the skin, scalp, and nails. Occasionally, nail psoriasis may be the only manifestation at the time of clinical presentation. The authors present the case of a 10-year-old boy with nail involvement as the main feature at presentation, initially treated with antifungal agents. The emergence of skin lesions allowed the diagnosis of nail psoriasis and appropriate treatment. Differential diagnosis with onychomycosis can be difficult due to overlapping clinical features of the nails. Therapeutic options for psoriasis include topical agents for moderate to mild disease, systemic agents for moderate to severe disease, and biologic agents for severe or refractory disease. This case reviews the diagnosis and treatment of a well-known condition with a less common presentation.

Keywords: nail; psoriasis; treatment

RESUMO

A psoríase é uma doença sistémica que envolve frequentemente a pele, o couro cabeludo e as unhas. Em alguns casos, as alterações ungueais podem ser a única manifestação na apresentação. Os autores relatam o caso clínico de um rapaz de 10 anos com envolvimento ungueal como principal manifestação. O rapaz foi inicialmente tratado com antifúngicos, mas o aparecimento de lesões cutâneas permitiu o diagnóstico e tratamento adequados. O diagnóstico diferencial com onicomicose pode ser difícil, uma vez que as alterações a nível ungueal se sobrepõem. As hipóteses terapêuticas na psoríase podem ser divididas em agentes tópicos na doença ligeira a moderada, agentes sistémicos na doença moderada a grave e agentes biológicos na doença grave ou refratária. Este caso clínico revisita o diagnóstico e tratamento de uma doença conhecida com uma apresentação menos comum.

Palavras-chave: psoríase; tratamento; unha

AUTHORSHIP

Ana Sofia Figueiredo - Data curation; Writing – original draft; Writing – review & editing

Carolina Quintela - Data curation; Validation; Visualization; Writing – review & editing

Susana Machado - Conceptualization; Methodology; Supervision; Validation; Writing – review & editing

Glória Velho - Conceptualization; Methodology; Supervision; Validation; Writing – review & editing

Jorge França Santos - Conceptualization; Methodology; Supervision; Validation; Writing – review & editing

REFERENCES

1. Eichenfield LF, Paller AS, Tom WL, Sugarman J, Hebert AA, Friedlander SF, *et al.* Pediatric psoriasis: Evolving perspectives. *Pediatr Dermatol.* 2018 Mar;35(2):170-181. doi: <https://doi.org/10.1111/pde.13382>.
2. Amy S Paller M, Emily Broun Lund M. Psoriasis in children: Epidemiology, clinical manifestations, and diagnosis. *UpToDate;* 2021.
3. Moustou AE, Kakourou T, Masouri S, Alexopoulos A, Sachlas A, Antoniou C. Childhood and adolescent psoriasis in Greece: a retrospective analysis of 842 patients. *Int J Dermatol* 2014; 53(12): 1447-53.
4. Mahé E. Childhood psoriasis. *Eur J Dermatol* 2016; 26(6): 537-48.
5. Uber M, Carvalho VO, Abagge KT, Robl Imoto R, Werner B. Clinical features and nail clippings in 52 children with psoriasis. *Pediatr Dermatol* 2018; 35(2): 202-7.
1. Tabassum S, Rahman A, Awan S, Jabeen K, Farooqi J, Ahmed B, *et al.* Factors associated with onychomycosis in nail psoriasis: a multicenter study in Pakistan. *Int J Dermatol.* 2019 Jun;58(6):672-678. doi: <https://doi.org/10.1111/ijd.14364>.
2. Gisondi P, Bellinato F, Girolomoni G. Topographic Differential Diagnosis of Chronic Plaque Psoriasis: Challenges and Tricks. *J Clin Med* 2020; 9(11).
3. Dogra S, Mahajan R. Biologics in pediatric psoriasis – efficacy and safety. *Expert Opinion on Drug Safety* 2018; 17(1): 9-16.
1. Osier E, Wang AS, Tollefson MM, Cordoro KM, Daniels SR, Eichenfield A, *et al.* Pediatric Psoriasis Comorbidity Screening Guidelines. *JAMA Dermatol.* 2017 Jul 1;153(7):698-704. doi: <https://doi.org/10.1001/jamadermatol.2017.0499>.

CORRESPONDENCE TO

Ana Sofia Figueiredo
Department of Neonatology and Pediatrics
Unidade de Vila Real
Centro Hospitalar de Trás os Montes e Alto Douro
Avenida da Noruega Lordelo
5000-508 Vila Real
Email: sofiafigueiredo.94@gmail.com

Received for publication: 17.08.2021

Accepted in revised form: 10.01.2022