

## CASE REPORTS

### Nijmegen breakage syndrome: The importance of follow-up

#### Síndrome de quebras de Nijmegen: A importância do seguimento

Sara Leite<sup>1</sup>, Cláudia Lemos<sup>1</sup>, Rita Dias<sup>2</sup>, Raquel Faria<sup>3,4</sup>, Laura Marques<sup>5</sup>

#### ABSTRACT

Nijmegen breakage syndrome (NBS) is a rare genetic disorder caused by mutations in the *NBN* gene, which is inherited in an autosomal recessive pattern. The condition results in inadequate DNA repair and is characterized by immunodeficiency with recurrent sinopulmonary infections, increased radiosensitivity, and predisposition to malignancy, particularly of lymphoid origin. The main clinical feature is progressive and severe microcephaly, which affects the facial phenotype, characterized by prominent midface, sloping forehead, and retrognathia. Mild to moderate intellectual impairment is often present and female patients usually develop primary ovarian failure. The diagnosis requires a high index of suspicion and is confirmed by molecular genetic testing. Herein are presented two cases of Nijmegen breakage syndrome followed in a tertiary center.

**Keywords:** immunodeficiency; Nijmegen breakage syndrome; microcephaly

#### RESUMO

A síndrome de quebras de Nijmegen (NBS) é uma doença genética rara que ocorre devido à presença de variantes patogénicas no gene *NBN*, herdado de forma autossómica recessiva. Esta condição leva à reparação inadequada do DNA e caracteriza-se por imunodeficiência com infeções pulmonares recorrentes, hipersensibilidade à radiação e predisposição para neoplasias, particularmente de origem linfóide. As características fenotípicas principais são a microcefalia grave, que influencia o fenótipo facial, com andar médio da face proeminente e retrognatismo. A perturbação ligeira a moderada do desenvolvimento é frequente e os doentes do sexo feminino geralmente desenvolvem insuficiência ovárica primária. O diagnóstico requer um elevado índice de suspeição e pode ser confirmado por análise genética. São apresentados dois casos de síndrome de quebras de Nijmegen seguidos num hospital terciário.

**Palavras-chave:** imunodeficiência; síndrome de quebras de Nijmegen; microcefalia

1. Department of Pediatrics, Centro Materno-Infantil do Norte, Centro Hospitalar Universitário de Santo António. 4050-651 Porto, Portugal. sara.s.leite@gmail.com; claudiajoalemos@gmail.com
2. Department of Medicine, Centro Hospitalar Universitário de Santo António. 4099-001 Porto, Portugal. rita.ribeiro.d@gmail.com
3. Clinical Immunology Unit, Centro Hospitalar Universitário de Santo António. 4099-001 Porto, Portugal. rakfaria@gmail.com
4. Unit for Multidisciplinary Research in Biomedicine (UMIB) – ICBAS – Universidade do Porto. 4050-313 Porto rakfaria@gmail.com
5. Infectious Diseases and Immunodeficiencies Unit, Department of Pediatrics, Centro Materno-Infantil do Norte, Centro Hospitalar Universitário de Santo António. 4050-651 Porto, Portugal. laurahoramarques@gmail.com

## INTRODUCTION

Nijmegen breakage syndrome (NBS) is a rare genetic disorder (1:100000) caused by mutations in the *NBN* gene, which is inherited in an autosomal recessive pattern.<sup>(1)</sup> With more than 60 variants described, the *NBN* gene, located on chromosome 8q21, is the only gene identified to date in the genetic basis of NBS.<sup>(2)</sup> The protein product of the *NBN* gene is nibrin, which plays a key role in regulating the activity of proteins involved in the end-processing of normal and mutated DNA double-strand (DDS) breaks caused by ionizing radiation.<sup>(2,3)</sup> When DDS breaks are not repaired, they result in genomic instability, gene mutations, or chromosomal rearrangements that can lead to malignancy, particularly of lymphoid origin.<sup>(4)</sup> Nibrin also plays a role in lymphocyte maturation and immunoglobulin class switching, resulting in immunodeficiency characterized by recurrent sinopulmonary infections and increased radiosensitivity.

The main clinical feature of NBS is progressive and severe microcephaly, which affects the facial phenotype, resulting in a prominent midface, sloping forehead, and retrognathia.<sup>(2)</sup> The nose is usually long and beaked, but may also be upturned with anteverted nostrils.<sup>(2)</sup> Mild to moderate intellectual impairment is often present, and female patients usually develop primary ovarian insufficiency.<sup>(2)</sup>

The diagnosis requires a high index of suspicion and is confirmed by molecular genetic analysis.

## CASE REPORTS

**Case 1.** An 18-month-old male of Ukrainian ancestry was referred to the hospital for severe microcephaly noted at birth. He presented a “bird-like” face (**Figure 1a**) and a *café au lait* spot on the right lumbar region. He had severe lymphopenia (686/mm<sup>3</sup>) with low CD4<sup>+</sup> counts (CD4 375/mm<sup>3</sup>; CD4% 28.4; **Table 1**). There was no relevant family history and the parents were not consanguineous. Molecular genetic analysis revealed a homozygous pathogenic variant, c.657\_661delACAAA(p.Lys219Asnfs\*16), confirming the diagnosis of NBS.

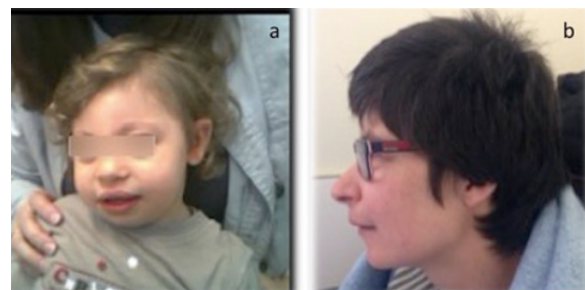
The child maintained regular follow-up. He is currently six years old, has moderate speech delay, and is receiving speech therapy and global developmental stimulation. Microcephaly was progressive (less than the 3<sup>rd</sup> percentile, standard deviation -4.86) and the boy maintained severe lymphopenia with low CD4<sup>+</sup> counts. Prophylactic cotrimoxazole was administered during the first three years of life. To date, he had no severe infections or signs of malignancy.

**Case 2.** A four-year-old girl was referred to the immunodeficiency center for recurrent respiratory infections. She had severe microcephaly (below the 3<sup>rd</sup> percentile, standard deviation -3.79), prominent midface, sloping forehead, receding mandible, and long, prominent nose (**Figure 1b**). The initial study revealed immunoglobulin deficiency and lymphopenia with low CD4 counts (**Table 1**). At the age of five, she was hospitalized for severe autoimmune hemolytic

anemia, with good response to steroids. She had a favorable course throughout childhood and adolescence, with moderate intellectual disability and recurrent respiratory tract infections, which were treated in the outpatient setting. The girl was transferred to the adult immunodeficiency clinic at the age of 18 years, clinically stable.

At the age of 33, she presented with severe hemolytic anemia and severe lymphopenia and cryoglobulinemia, and was diagnosed with lymphoplasmocytic lymphoma. She was treated with a chemotherapy regimen (five cycles of rituximab, cyclophosphamide, and prednisone), with initial clinical remission. Six months later, a control computed tomography (CT) scan showed pulmonary relapse and the girl was started on a new chemotherapy regimen (four cycles of rituximab and bendamustine). She experienced clinical deterioration since cycle four, and a new biopsy of a mass lesion confirmed progression to high-grade diffuse large B-cell lymphoma. She was started on palliative treatment with cyclophosphamide and rituximab, with no response and a fatal outcome in four months.

The patient fulfilled clinical and analytical criteria for NBS and had several chromosomal abnormalities: 46,XX,t(2;13)(p21;q14),t(6;10)(q21;p15),t(7;11)(q32;q23.2). Molecular genetic testing for the most common abnormalities in the *NBN* gene at that time (including the founder mutation in exon 6, c.657\_661del5) was negative. Genomic array (array-CGH) showed the presence of the 6q23.1-q23.2 deletion associated with lymphoplasmocytic lymphoma.



**Figure 1** – Phenotypic features of the two patients considered (a. male, Case 1; b. female, Case 2)

**Table 1** – Immunologic profile of the two patients

	Case 1	Case 2
<b>Immunoglobulin</b>		
IgA (mg/dL)	39	548
IgG (mg/dL)	631	891
IgM (mg/dL)	58	70
IgE (UI/mL)	<2	<2
<b>Lymphocyte population (/mm<sup>3</sup>)</b>		
CD3	560	1127
CD4	375	520
CD8	84	590
CD19	286	121

## DISCUSSION

The diagnosis of NBS is based on characteristic clinical manifestations, chromosomal instability, increased cellular sensitivity to ionizing radiation *in vitro*, cellular and humoral immunodeficiency, and homozygous pathogenic variants in the *NBN* gene.

Patients have a high susceptibility to infections, usually involving the respiratory tract (chronic sinusitis, recurrent bronchitis, pneumonia). Opportunistic infections are also common. Early diagnosis of NBS is important to prevent severe recurrent infections.

There is no specific treatment for NBS. Intravenous immunoglobulin may be given if immunoglobulin levels are low, and appropriate antibiotic prophylaxis may be instituted.

Unnecessary exposure to all forms of ionizing radiation for diagnostic purposes should be avoided unless absolutely necessary. Because of the high sensitivity to radiation treatment and chemotherapy, the radiation dose should be limited and chemotherapy protocols should be tailored to individual tolerance.<sup>(2,4)</sup> In these patients, it is reasonable to reduce the chemotherapy dose by up to 50%, especially with anthracyclines, methotrexate, alkylating agents, and epipodophyllotoxins. The use of monoclonal antibodies and kinase inhibitors or bone marrow transplantation with reduced-intensity conditioning can be considered in selected cases to replace radiotherapy and some antineoplastic agents, as performed in Case 2.<sup>(1,4)</sup>

The major complication associated with chromosomal instability is the development of cancer, primarily of lymphoid origin. As many as 40% of malignancies are diagnosed before the second decade of life, and the most common types are non-Hodgkin lymphoma, predominantly diffuse large B-cell lymphoma, and T-cell lymphoblastic lymphoma.<sup>(4)</sup> Patient prognosis remains poor.

Malignancy should be carefully assessed, as it may occur several decades after diagnosis. The patient in Case 2 presented with lymphoma in the third decade of life, with an initial remission followed by a fatal course, which is common in these patients. Early diagnosis must be made by examinations that do not involve the use of ionizing radiation. However, this patient underwent two chest X-rays and three CT scans between diagnosis and follow-up because these studies are more accessible than magnetic resonance imaging. The impact of this amount of ionizing radiation on the final outcome is unknown.

The present two cases illustrate the importance of close and long-term follow-up of NBS patients from childhood to adulthood, as some comorbidities may be prevented or reduced with early treatment. In addition, genetic counseling should be offered to parents of affected patients, as NBS is an autosomal recessive disorder and prenatal testing for increased risk pregnancy or preimplantation genetic diagnosis for NBS can be performed.<sup>(2)</sup>

## AUTHORSHIP

Sara Leite – Writing – original draft  
Cláudia Lemos – Writing – original draft  
Rita Dias – Writing – review & editing  
Raquel Faria – Writing – review & editing  
Laura Marques - Writing – review & editing

## REFERENCES

1. Kocheva SA, Martinova K, Antevska-Trajkova Z, Coneska-Jovanova B, Eftimov A, Dimovski AJ. T-lymphoblastic leukemia/lymphoma in Macedonian patients with Nijmegen breakage syndrome. *Balkan J Med Genet*. 2016; 19(1):91-4.
2. Varon R, Demuth I, Chrzanowska KH. Nijmegen Breakage Syndrome. *GeneReviews*. Seattle: University of Washington; 1993-2018.
3. Wolska-Kuśnierz B, Gregorek H, Chrzanowska K, Piatosa B, Pietrucha B, Heropolitanska-Pliszka E, *et al*. Nijmegen Breakage Syndrome: Clinical and Immunological Features, Long-term outcome and treatment options – a retrospective analysis. *J Clin Immunol*. 2015;35(6):538-49.
4. Pastorczak A, Szczepanski T, Mlynarski W. Clinical course and therapeutic implications for lymphoid malignancies in Nijmegen breakage syndrome. *Eur J Med Genet*. 2016;59(3):126-32.
5. Correia J, Pinho L, Couto Guerra I, Costa E, Cleto E. Instabilidade cromossômica e imunodeficiência – associação essencial no diagnóstico de Síndrome de Nijmegen. *Revista Nascer e Crescer*. 2017;26(2):133-7.
6. Braggio E, Dogan A, Keats J, Chng W J, Huang G, Matthews J M, *et al*. Genomic analysis of marginal zone and lymphoplasmacytic lymphomas identified common and disease-specific abnormalities. *Mod Pathol*. 2012;25(5):651-60.

## CORRESPONDENCE TO

Sara Leite  
Department of Pediatrics  
Centro Materno-Infantil do Norte  
Centro Hospitalar Universitário de Santo António  
Largo da Maternidade de Júlio Dinis 45  
4050-651 Porto  
Email: sara.s.leite@gmail.com

Received for publication: 02.11.2021

Accepted in revised form: 28.04.2022